

## V-Shaped Corrective Ulnar Osteotomy in Neglected Monteggia Fracture Dislocation in Children

Riad M Megahed<sup>\*</sup>, Ali T Elalfy and Ahmed Mohammed Abdelwahab

Department of Orthopaedic Surgery, Faculty of Medicine, Zagazig University, Egypt

<sup>\*</sup>Corresponding author: Riad M Megahed, Assistant Professor, Zagazig University Faculty of Human Medicine, Orthopedics, Egypt, Tel: 00201005645077; E-mail: riadmansour203@yahoo.com

Received date: November 29, 2016; Accepted date: January 18, 2017; Published date: January 25, 2017

Copyright: © 2017 Megahed RM, et al. This is an open-access article distributed under the terms of the Creative Commons Attribution License, which permits unrestricted use, distribution, and reproduction in any medium, provided the original author and source are credited.

### Abstract

**Background:** Neglected Monteggia fracture dislocation in children constitutes significant disability in respect to pain, stiffness, deformity, neurological compromise and restriction of activities of daily living. Many treatment strategies have been described to manage neglected Monteggia fracture dislocation and one of these strategies is the ulnar osteotomy for restoration of the ulnar length and reduction of the radial head with annular ligament reconstruction for restoration of the elbow biomechanics for this difficult problem.

**Aim:** Evaluation of the results of a new V-shaped corrective ulnar osteotomy without bone grafting with annular ligament reconstruction in management of neglected Monteggia fracture dislocation in children.

**Materials and methods:** In a prospective study 16 patients with mean age of 7 years and 3 months, who presented with neglected Monteggia fracture dislocation, were studied. The time interval between injury and presentation ranged from 3 months to 20 months (mean 11.2 months). Eleven patients were classified as Bado type I, three as Bado type II and two as Bado type III. All children underwent open reduction of the radiocapitellar joint with V-shaped angulation-distraction osteotomy of ulna and annular ligament reconstruction. We used the Mayo elbow performance score for evaluation of our results.

**Results:** The mean follow-up period was 19.5 months. All ulnar osteotomies healed uneventfully. The mean loss of pronation was 4°. Elbow flexion-extension range improved postoperative by 3° and no child complained of pain, deformity or restriction of activity. The elbow score was excellent in eight cases, good in five cases, and fair in three cases.

**Conclusion:** V-shaped corrective ulnar osteotomy technique without bone grafting is a technically simple procedure, which achieves lengthening and angulation of the ulna simultaneously in the sagittal plane and reduces the radial head and with annular ligament reconstruction will suffice in most cases of missed Monteggia fracture dislocation.

**Keywords:** Missed Monteggia fracture; Annular ligament reconstruction; Ulna osteotomy

### Introduction

Monteggia first described in 1814 a fracture of the proximal third of the ulna with dislocation of the radial head. It represents a link between injuries of the forearm and the elbow. These injuries follow the course of forearm fractures prognostically if recognized and treated early. However these injuries are often missed at the time of initial trauma [1].

Monteggia fracture-dislocation is a relatively rare injury. Bado reported an incidence of 1.7% in a cohort of 3,200 patients with forearm fractures [2]. The original injuries may be missed in up to 33% of cases, and late loss of reduction following closed treatment can be seen in up to 20% of cases [3]. Long-term follow-up of untreated Monteggia fracture dislocation reveals development of premature arthritis, pain, stiffness, deformity, neurological compromise and restriction of activities of daily living [3,4]. Thus, it is imperative to

treat the neglected fracture as soon as it is diagnosed. Freedman et al. performed reconstructive procedures up to six years after injury [5].

Restoration of normal anatomical relationship between proximal ulna and radius in cases of neglected Monteggia fracture dislocation is technically demanding procedure. Reduction of the radial head can be done either by open or closed methods. Many surgical options have been described in the literature such as open reduction and reconstruction of the annular ligament [3,6,7]. But ulnar osteotomy is the key for radial head reduction [8-17] which can be done by lengthening of the ulna with external fixator [18-20] or angulation at osteotomy site by wedge graft accompanied by fixation with plates and screws [21,22]. The aim of this study is to evaluate the results of the radial head reduction in children with neglected Monteggia fracture dislocation without bone grafting or application of external fixator by a simpler V-shaped corrective osteotomy of the ulna which allows ulnar angulation and lengthening along with annular ligament reconstruction in single stage.

## Materials and Methods

Ethical permission for this study was obtained from the Ethics Committee of Scientific Research in Zagazig University and informed consent was obtained from all guardians before participation in the study.

We had treated 16 patients of post traumatic symptomatic old Monteggia fracture –dislocation from the year 2009 to 2014 in the department of orthopaedics, Zagazig University hospitals. The age of patients at the time of reconstruction ranged from 7-12 years (average 7 years and 3 months). The gender of the cases was 9 girls and 7 boys; right side was affected in 10 cases and left side in 6 cases. According to Bado classification (Table 1) 11 patients were of Bado type I, 3 patients were Bado type II, and 2 were of Bado type III. No patients with type IV reported.

Type I	Anterior dislocation of radial head , anterior angulation of ulnar shaft fracture
Type II	Posterior dislocation of radial head , posterior angulation of ulnar shaft fracture
Type III	Lateral dislocation of radial head , proximal metaphyseal fracture of ulna
Type IV	Anterior dislocation of radial head , shaft fracture of ulna and radius

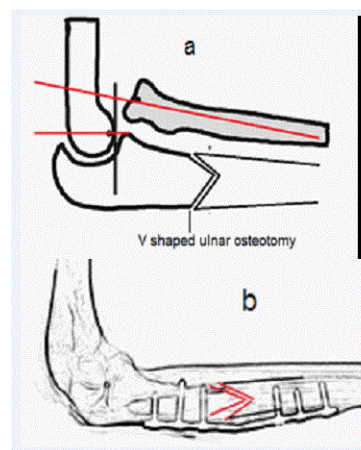
**Table 1:** Monteggia fracture dislocation– classification according to Bado [2].

The inclusion criteria included time interval between injury and surgical repair at least more than four weeks and this varied in our study between 3-20 months (average 11.2 months). The exclusion criteria included gross distortion of the radial head. No posterior interosseous nerve palsy was detected preoperatively in any of the cases.

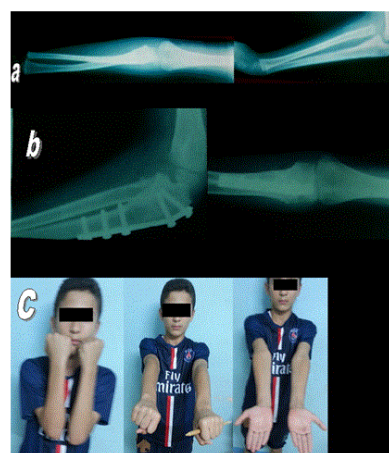
## Technique

Under general anaesthesia and tourniquet applied on the upper arm, a postero-lateral skin incision was made to expose the radiocapitellar joint and the mal-united site of the ulna through Speed and Boyd approach [23] which exposes the lateral surface of the ulna and the proximal fourth of the radius. The substance of the reflected supinator protects the deep branch of the radial nerve. The radiocapitellar joint was first approached and the radial head was found to be covered with dense fibrous scar tissue, which was excised. Reduction of the radial head into radial notch of proximal ulna was attempted, and its stability was assessed if the proximal radius is still unstable, maintain reduction with an oblique pin from the radius to the proximal ulna. In all patients stability could not be achieved and an ulnar osteotomy was performed of the ulna to ensure stability of the radial head. The proximal part of the ulna, i.e., the site of malunion or plastic deformity, is exposed through the standard dorsal approach. A sagittal oriented V-shaped osteotomy of the ulna is made similar to V-incision for lengthening of tendons with limbs of V with the long axis of the ulna and the limbs of the V is based on the diaphyseal fragment (Figure 1a). The osteotomy site is then angulated and lengthened simultaneously. When the appropriate length and angulation are achieved, the radial head gets reduced. The reduction is felt clinically and also confirmed by checking the stability of the radial head in flexion, extension, pronation and supination and by the radiocapitellar line under an image intensifier. A lateral slip of the triceps tendon was

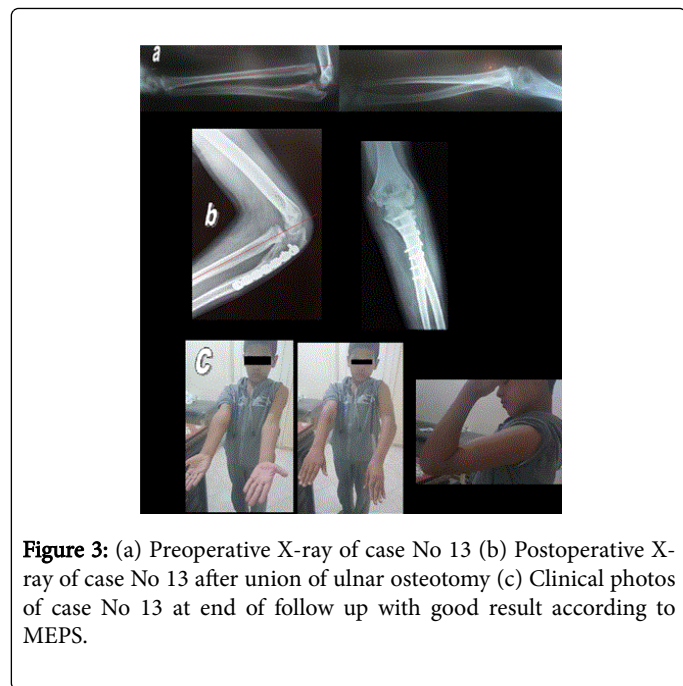
used for ligament reconstruction or with remnants of the ligament itself. A Kirschner wire was drilled percutaneously through the capitellum into the radial head with the elbow in 90 degrees of flexion and supination. The osteotomy at this particular angulation and length is held reduced in position with a small clamp and then fixed with small Dynamic Compression Plate (DCP) or reconstruction plate (Figure 1b). The excess bony spikes on the dorsal side are then shaved off to prevent prominence on the dorsal aspect of the proximal forearm. Post-operatively, the elbow is immobilized in 90° flexion and full supination for a period of six weeks followed by gradual mobilization (Figures 2 and 3).



**Figure 1:** (a) Diagram shows Monteggia fracture dislocation with v shaped ulnar osteotomy before correction of radiocapitellar line. (b) After angulation of osteotomy site and reduction of the radial head with fixation by plate.



**Figure 2:** (a) Preoperative X-ray of case No 3 (b) Postoperative X-ray of case No 3 after union of ulnar osteotomy (c) Clinical photos of case No 3 at end of follow up with excellent result according to MEPS.



**Figure 3:** (a) Preoperative X-ray of case No 13 (b) Postoperative X-ray of case No 13 after union of ulnar osteotomy (c) Clinical photos of case No 13 at end of follow up with good result according to MEPS.

The results of this study was graded as excellent, good, fair, poor based on the Mayo Elbow Performance score (MEPS). This scoring system has 4 parameters: 45 points are given for a pain-free elbow, 20 points for normal elbow movement, 10 points for a stable elbow and 25 points for performance of five activities of daily living. Stability of the elbow is rated as stable (no apparent varus/valgus instability), moderate (<10°varus/valgus instability), or gross (≥ 10°varus/ valgus instability). A patient with excellent result had a score of 90-100 points, a score of 75-89 points is good, a score of 60-74 points is fair, and score of less than 60 points is poor [24].

### Statistical Analysis

Data collected throughout history, basic clinical examination and outcome measures coded, entered and analyzed using Microsoft Excel software. Data were then imported into Statistical Package for the Social Sciences (SPSS version 20.0) (Statistical Package for the Social Sciences) software for analysis. According to the type of data qualitative represent as number and percentage , quantitative continues group represent by mean ± SD, comparison between paired quantitative parametric data by Paired t, P value was set at <0.05 for significant results and <0.001 for high significant result.

### Results

In this study all cases had regular thorough follow up for a period ranging from 12 to 26 months with a mean period of 19.5 ± 5.8 months (Tables 2-4). The mean operative time was 85 minutes. All patients of ulnar osteotomy united in good position and the length of ulna was maintained. The mean healing time of ulnar osteotomy for all children was 8 weeks (range 6-12 weeks). All 11 patients of Bado type I (68.7%) fracture achieved good range of motion with no evidence of residual radial head subluxation. Two cases (12.5%), one Bado type II fracture and one of the Bado type III, showed mild subluxation of radial head by radiocapitellar line which did not require any treatment. Transient posterior interosseous nerve palsy detected in one case (6.2%) recovered at 6.5 months after operation. Three patients (18.7%) also had superficial wound infection which resolved with local wound care and oral antibiotics.

Case	Age Months	Years/	Sex	Bado type	Duration from injury	Follow up [months]
1	7.2		B	I	7	22
2	6.3		G	I	10	21
3	7.4		B	I	9	25
4	6.2		G	III	9	12
5	8.9		G	I	8	12
6	4.3		B	I	7	14
7	6.4		B	I	18	26
8	5.6		G	II	9	25
9	8.7		G	I	6	26
10	6.9		B	I	3	24
11	12.2		G	II	8	26
12	9.3		B	II	14	12
13	7.6		B	I	16	12
14	6.5		G	III	20	17
15	7.9		G	I	19	22
16	6.5		G	I	17	16

**Table 2:** Clinical details of patients with missed Monteggia fracture.

Case No	Flexion Extension arc in degrees				Pro/sup Arc in degrees			
	Pre-op.	Post -op.	Change	Pain	Pre – op.	Post- Op	Change	MEPS
1	135	110	-25	Nil	170	140	-30	Fair
2	135	135	0	Nil	170	150	-20	Good
3	105	130	25	Nil	170	170	0	Excellent
4	140	130	-10	Nil	170	150	-20	Good
5	120	140	20	Nil	150	160	10	Excellent

6	120	145	25	Nil	120	150	30	Excellent
7	145	120	-25	Nil	180	140	-40	Fair
8	85	110	25	Nil	140	160	20	Excellent
9	110	130	20	Nil	150	160	10	Excellent
10	135	135	0	Nil	140	160	20	Excellent
11	130	130	0	Nil	180	170	-10	Good
12	145	120	-25	Nil	180	150	-30	Fair
13	140	130	-10	Nil	170	150	-20	Good
14	145	130	-15	Nil	150	140	-10	Good
15	120	145	25	Nil	130	150	20	Excellent
16	115	130	15	Nil	170	170	0	Excellent

**Table 3:** Details of pre and postoperative elbow function.

	Pre-operative Mean ± SD	Post-operative Mean ± SD	Paired t-test	p. value
Flexion Extension arc in degrees	126.3 ± 25.3	129.4 ± 10.3	-0.505	0.621
Pronation /supination Arc in degrees	158.8 ± 32	154.4 ± 10.3	0.554	0.588

**Table 4:** Comparison between pre-operative and post-operative elbow function regarding flexion extension and pronation/supination arc in degrees among the studied group.

### Clinical results

The mean preoperative range of flexion extension motion was (126°), and the mean postoperative range of motion was (129°) so the mean range of motion increased by 3° (p. value 0.6). All patients had a supination-pronation arc of > 100°; the range of supination was always less than that of pronation. The mean preoperative supination-pronation arc was 158°, and the mean postoperative supination-pronation arc was 154°, so the mean supination-pronation arc decreased by 4° (p value 0.5). Although no correlation was noted between the range of movements achieved and the duration of treatment, patients treated earlier had a greater range of movements than those treated later. At the final follow-up, no patient had any sign of instability. Based on the Mayo elbow performance score there were eight patients with excellent and five patients with good, and three patients with fair results at the final follow up.

### Radiological results

The initial post-operative radiographs showed anatomic reduction of the radial head and at the latest follow up in all patients of Bado type I fractures, two of Bado type II and one of the Bado type III. The radiocapitellar line showed subluxation of radial head with an irregular capittellar surface in two cases (one Bado type II fractures, and one of the Bado type III). The mean healing time of ulnar osteotomy for all children was 8 weeks (range 6-12 weeks). There were no cases of

growth disturbance, heterotopic bone formation or radioulnar synostosis.

### Discussion

The problems associated with neglected radio-ulnar dislocation after a Monteggia fracture-dislocation includes loss of forearm rotation, cubitus valgus, elbow instability, pain, degenerative arthritis, subluxation of the distal radioulnar joint and late neuropathy [3,6]. The keys to good results are early recognition of the injury and a stable reduction of the proximal radio-ulnar joint, which requires a sound and anatomical reduction of the ulnar fracture.

The duration for a neglected dislocation to be accepted as being reversible before the secondary adaptive changes disrupt the end result is not known exactly. The secondary adaptive changes developed are a deformity of the radial head and capitellum, causing incongruity of the radiocapitellar or proximal radioulnar joint and the interosseous membrane may lose tension, allowing re-dislocation of the radial head. The time interval between the injury and treatment and the maximum age at which the dislocated radial head may be successfully reduced without affecting the function of the elbow varies in the literature. Freedman et al. reported a case of satisfactory surgical correction achieved six years after the original dislocation [5]. Hirayama et al. and Stoll et al. reported that reconstruction could be successfully achieved in children up to ten years of age and at least four years after the initial injury [10,11]. Horii et al. recommended reduction of the radial head in patients under the age of 12 years when deformity of the radial head is minimal [14]. In the series by Kim et al. reconstruction was attempted up to 15 years of age and even ten years after the injury [13]. In Suzuki et al. [25] study they found that the correction of the dislocation gives the best result between 3 to 6 years passed since the initial trauma. In this study, the mean duration since the injury in our patients was 11.2 months.

The type of reconstruction varies and there is no clear consensus regarding treatment of missed Monteggia fracture. Open reduction of radial head and reconstruction of annular ligament combined with ulnar osteotomy by Rodgers et al. showed unpredictable results in his five of seven cases; whereas Inoue and Shionoya reported their good

results only in anterior monteggia lesion [26,27]. We have no experience regarding closed reduction by gradual lengthening of angulated ulna using an external fixator in the treatment of old dislocation Monteggia fracture dislocation as reported by Exner [18]. In our series, based on the Mayo elbow performance score there were eight patients with excellent result, five patients with a good result, and three patients with fair results. Suzuki et al. have suggested that reduction of the dislocated radial head leads to an increase in flexion of the elbow at the cost of a slight decrease in rotation of the forearm [25]. This is supported by our findings, the mean preoperative range of motion was (126°), and the mean postoperative range of motion was (129°), so the mean range of motion increased by 3°. All patients had a supination-pronation arc of > 100°; the range of supination was always less than that of pronation. The mean preoperative supination-pronation arc was 158°, and the mean postoperative supination-pronation arc was 154° so the mean supination-pronation arc decreased by 4°. We believe that even though spontaneous reduction of the radial head takes place after correction of the ulnar deformity, annular ligament reconstruction should be done in all cases for restoration of elbow biomechanics. No evidence of significant extension lag or notching and restriction of motion were seen in our study using the triceps sling or remnants of the annular ligament. V-shaped corrective osteotomy achieves lengthening as well as angulation of the ulna at the same time without compromising the stability. The amount of lengthening and angulation required is decided by the reduction of the radial head. The osteotomy is fixed at the length and angulation when a stable reduction of the radial head is achieved. Hasler et al. stated that only the repositioned radial head is “capable of defining the appropriate position for ulnar realignment” [19]. The same principle is followed in our technique, and we believe that once the radial head is reduced and with the elbow in 90° flexion and full supination the reduced radial head acts as an indirect support to maintain the osteotomy in the required length and angulation. We noticed in our series that the amount of ulnar lengthening needed for stable reduction of radial head ranged from 5-10 mm with 7 mm mean. The stability of the osteotomy increased by fixation with plate and screws although the intrinsic stability of the V-shaped osteotomy is present due to a large contact area between the two ends of the bones this lead to shortening of postoperative splinting with a plaster cast for 6 weeks. When we removed extra bone at the dorsal aspect of the osteotomy site we didn't found any effect on the stability of the osteotomy and the angulated ulna remodel very well without any cosmetic deformity.

Controversy exists regarding reconstruction of the annular ligament. Nakamura et al. [28] and David-West et al. [29] advocate it in all cases while others like Devnani [9] disregard it completely. Others like Bhaskar et al. [30] prefer an intra-operative decision based on the stability of reduction. Garg et al. [31] reported better results with annular ligament reconstruction using Palmaris longus graft but we believe that the remnants of the annular ligament if present or the lateral slip of the triceps fascia is a better option than the free Palmaris longus and is more biological and viable. Various types of osteotomies have been used to facilitate reduction of the radial head and to prevent recurrent subluxation. They include locking osteotomy without fixation or stabilized by graft, corrective diaphyseal osteotomy, proximal bending osteotomy, angulation and elongation osteotomy, gradual lengthening and angulation of the ulna using an external fixator [4,12,18]. The V-shaped corrective osteotomy has the following advantages:

(1) The surgical technique is relatively simple.

(2) A bigger contact area is maintained at the osteotomy site providing more stability.

(3) As there is bone-to-bone contact there is no need for bone graft and the chance for nonunion is less.

One of the limitations of our study is that the duration since injury until which this technique could be successful is not known. The minimum duration in our study was three months and the maximum was 20 months. Another limitation of our study is the small number of the sample size, as this condition is relatively rare.

## Conclusion

V-shaped corrective ulnar osteotomy technique without bone grafting is a technically simple, less demanding procedure, which achieves lengthening and angulation of the ulna simultaneously and reduces the radial head and with annular ligament reconstruction will suffice in most cases of missed Monteggia fractures. However, a longer follow-up with a higher number of cases is needed to arrive at definitive conclusions.

## References

1. Fowles JV, Sliman N, Kassab MT (1983) The Monteggia lesion in children: Fracture of the ulna and dislocation of the radial head. *J Bone Joint Surg Am* 65: 1276-1282.
2. Bado JL (1967) The Monteggia lesion. *Clin Orthop* 50: 71-86.
3. Bae Donald S (2016) Successful strategies for managing Monteggia injuries. *J Pediatr Orthop* 36: S67-S70.
4. Kalamchi A (1986) Monteggia fracture-dislocation in children: Late treatment in two cases. *J Bone Joint Surg Am* 68: 615-619.
5. Freedman L, Luk K, Leong JC (1988) Radial head reduction after a missed Monteggia fracture: Brief report. *J Bone Joint Surg Br* 70: 846-847.
6. Lloyd-Roberts GC, Bucknill TM (1977) Anterior dislocation of the radial head in children: Aetiology, natural history and management. *J Bone Joint Surg Br* 59: 402-427.
7. Gyr B M, Stevens PM, Smith JT (2004) Chronic Monteggia fractures in children: Outcome after treatment with the Bell-Tawse procedure. *J Pediatr Orthop B* 13: 402-406.
8. Oner FC, Diepstraten AF (1993) Treatment of chronic post-traumatic dislocation of the radial head in children. *J Bone Joint Surg Br* 75: 577-581.
9. Devnani AS (1997) Missed Monteggia fracture dislocation in children. *Injury* 28: 131-133.
10. Hirayama T, Takemitsu Y, Yagihara K, Mikita A (1987) Operation for chronic dislocation of the radial head in children: Reduction by osteotomy of the ulna. *J Bone Joint Surg Br* 69: 639-642.
11. Stoll TM, Willis RB, Paterson DC (1992) Treatment of the missed Monteggia fracture in the child. *J Bone Joint Surg Br* 74: 436-440.
12. Best TN (1994) Management of old unreduced Monteggia fracture dislocations of the elbow in children. *J Pediatr Orthop* 14: 193-199.
13. Kim HT, Park BG, Suh JT, Yoo CI (2002) Chronic radial head dislocation in children, part 2: Results of open treatment and factors affecting final outcome. *J Pediatr Orthop* 22: 591-597.
14. Horii E, Nakamura R, Koh S, Inagaki H, Yajima H, et al. (2002) Surgical treatment for chronic radial head dislocation. *J Bone Joint Surg Am* 84-A: 1183-1188.
15. Degreef I, De Smet L (2004) Missed radial head dislocations in children associated with ulnar deformation: treatment by open reduction and ulnar osteotomy. *J Orthop Trauma* 18: 375-378.
16. Wang MN, Chang WN (2006) Chronic posttraumatic anterior dislocation of the radial head in children: thirteen cases treated by open

- reduction, ulnar osteotomy, and annular ligament reconstruction through a Boyd incision. *J Orthop Trauma* 20: 1-5.
17. Eygendaal D, Hillen RJ (2007) Open reduction and corrective ulnar osteotomy for missed radial head dislocations in children. *Strategies Trauma Limb Reconstr* 2: 31-34.
  18. Exner GU (2001) Missed chronic anterior Monteggia lesion: Closed reduction by gradual lengthening and angulation of the ulna. *J Bone Joint Surg Br* 83: 547-550.
  19. Hasler CC, Von Laer L, Hell AK (2005) Open reduction, ulnar osteotomy and external fixation for chronic anterior dislocation of the head of the radius. *J Bone Joint Surg Br* 87: 88-94.
  20. Gicquel P, De Billy B, Karger C, Maximin MC, Clavert JM (2000) Treatment of neglected Monteggia's fracture by ulnar lengthening using the Ilizarov technique. *Rev Chir Orthop Reparatrice Appar Mot* 86: 844-847.
  21. Belangero WD, Livani B, Zogaib RK (2007) Treatment of chronic radial head dislocations in children. *Int Orthop* 31: 151-154.
  22. Mehta SD (1985) Flexion osteotomy of ulna for untreated Monteggia fracture in children. *Ind J Surg* 47: 15-19.
  23. Speed and Boyd (2013) Fractures and dislocations in children: Campbell's operative orthopaedics.
  24. Broberg MA, Morrey BF (1986) The mayo clinic performance index for the elbow. *J Orthop Trauma* 20: 8.
  25. Suzuki T, Seki A, Nakamura T, Ikegami H, Takayama S, et al. (2015) Re-dislocation after corrective osteotomy for chronic dislocation of the radial head in children. *Bone Joint J* 97: 11.
  26. Rodgers WB, Waters PM, Hall JE (1996) Chronic monteggia lesions in children: Complications and results of reconstruction. *J Bone Joint Surg Am* 78: 1322-1329.
  27. Inoue G, Shionoya K (1998) Corrective ulnar osteotomy for malunited anterior Monteggia lesions in children: 12 patients followed for 1-12 years. *Acta Orthop Scand* 69: 73-76.
  28. Nakamura K, Hirachi K, Uchiyama S, Takahara M, Minami A, et al. (2009) Long term clinical and radiographic outcomes after open reduction for missed monteggia fracture-dislocations in children. *J Bone Joint Surg Am* 91: 1394-1404.
  29. David-West KS, Wilson NI, Sherlock DA, Bennet GC (2005) Missed monteggia injuries. *Injury* 36: 1206-1209.
  30. Bhaskar A (2009) Missed monteggia fracture in children: Is annular ligament reconstruction always required? *Indian J Orthop* 43: 389-395.
  31. Garg P, Baid P, Sinha S, Ranjan R, Bandyopadhyay U, et al. (2011) Outcome of radial head preserving operations in missed Monteggia fracture in children. *Indian J of Orthop* 45: 404-409.