

# Virtual Surgical Simulation of Plate Setback for Reconstruction in an Edentulous Patient Following Segmental Mandibulectomy

Hitoshi Miyashita<sup>1\*</sup>, Naoko Sato<sup>2</sup>, Takashi Kochi<sup>3</sup>, Naoyuki Takagi<sup>4</sup> and Tetsu Takahashi<sup>1</sup>

<sup>1</sup>Division of Oral and Maxillofacial Surgery, Tohoku University Graduate School of Dentistry, Sendai, Japan

<sup>2</sup>Maxillofacial Prosthetics Clinic, Tohoku University Hospital, Sendai, Japan

<sup>3</sup>Department of Plastic and Reconstructive Surgery, Tohoku University Hospital, Sendai, Japan

<sup>4</sup>Department of Plastic and Reconstructive Surgery, Tohoku University Graduate School of Medicine, Sendai, Japan

\*Corresponding author: Hitoshi Miyashita, Division of Oral and Maxillofacial Surgery, Tohoku University Graduate School of Dentistry, 4-1 Seiryomachi, Aoba-ku, Sendai, Miyagi 980-8575, Japan, Tel: +81-022-717-8350; Fax: +81-022-717-8354; E-mail: miyashita@dent.tohoku.ac.jp

Received date: March 19, 2018; Accepted date: March 29, 2018; Published date: March 31, 2018

Copyright: ©2018 Miyashita H, et al. This is an open-access article distributed under the terms of the Creative Commons Attribution License, which permits unrestricted use, distribution, and reproduction in any medium, provided the original author and source are credited.

## Abstract

To restore continuity of the mandible after segmental mandibulectomy, a reconstruction plate with soft tissue transfer can be used as an alternative option to osseocutaneous tissue transfer. However, many surgeons carefully consider the use of this technique for central mandibulectomy defects because of the high rate of plate exposure. Although plate setback has been demonstrated to reduce plate-related complications, little information is available. This report describes the virtual surgical simulation of plate setback for reconstruction following segmental central mandibulectomy in a patient who was to become edentulous with anticipated postoperative lip incompetence and dysphasia.

**Keywords:** Reconstructive plate; Virtual surgical simulation; Mandibular reconstruction

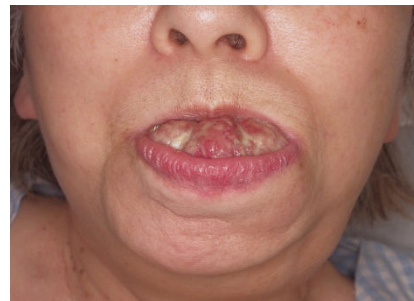## Introduction

The primary goal of mandibular reconstruction after segmental mandibulectomy is to restore oral function and esthetics. Vascularized bony reconstruction is an ideal approach as it has good long-term outcomes [1,2]. However, when bony reconstruction, which involves long and complex procedures, is unsuitable because of age, comorbidities, dentition and patient choice, a plate with soft tissue transfer can be an alternative option.

Plate reconstruction is useful when a large soft tissue free flap is required because of extensive soft tissue resection and when dental rehabilitation is not anticipated in the fibula [3]. However, a high rate of plate exposure has been reported when used for mandibulectomy defects, including in the central mandible [4]. To reduce plate-related complications, soft tissue selections, plate coverage by soft tissue, and plate setback have been used during plate reconstruction [5]. However, little information is available regarding plate setback and the optimal amount of setback relative to the position of the original mandible is uncertain. Recently, virtual surgical simulation has provided good outcomes in maxillofacial bony reconstruction [6], and it could offer more predictable outcomes for plate reconstruction by preoperative planning of the plate size and position. This report presents the virtual surgical simulation of plate setback for reconstruction following segmental mandibulectomy, including the central mandible, in a patient who was to become edentulous with anticipated postoperative lip incompetence and dysphasia.

## Case Report

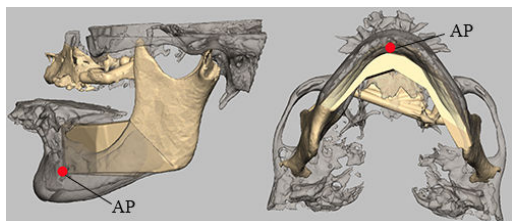
A 72-year-old female presented with extensive squamous cell carcinoma of the mandibular anterior gingival region and carcinoma of the left submandibular gland (Figure 1). The stereolithography files of the patient's maxillofacial bones were imported to computer-aided design software (Dental Modeling Software; Toyotsu Machinery, Tokyo, Japan) and a three-dimensional (3D) virtual model was created. Bilateral mandibulectomy, preserving the right gonial angle, and the complex soft tissue resection were planned based on the clinical examination, biopsy results, computed tomography scan, and magnetic resonance images. Plate reconstruction using a microvascular anterolateral thigh (ALT) flap was selected because of the large and complex soft tissue defect, comorbidities, and the patient's choice.



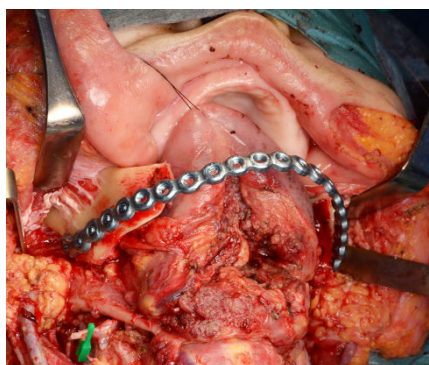**Figure 1:** Preoperative clinical photo of the patient.

There were critical factors to consider during reconstructive planning: 1) becoming edentulous with no anticipated dental rehabilitation in the mandible after surgery, 2) skeletal class III relationship, and 3) the resection of the lower lip and floor of mouth. If

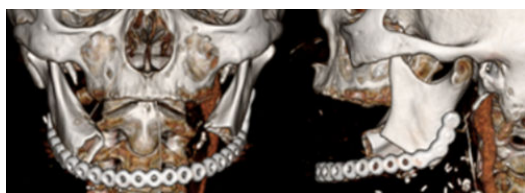
the plate was bent and positioned according to the lower border of the original mandible, it might impair lip closure and swallowing and may exert excessive pressure on the soft tissue surrounding the plate. Therefore, plate setback was required and virtual surgical simulation was performed for plate planning. The anterior point (AP) of the buccal side of the simulated model was set back horizontally to the lingual side of the original mandible in the lateral view, which provided space for coverage of the plate with the ALT fascia (Figure 2).



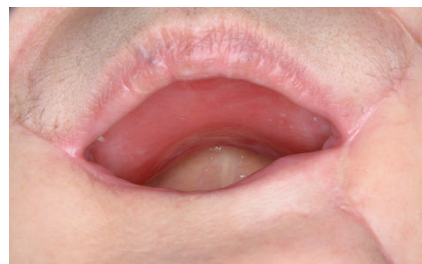**Figure 2:** Superimposition of simulated model and original (preoperative) mandible images (AP: anterior point).



**Figure 3:** Intraoperative image of the reconstruction plate.



**Figure 4:** Postoperative computed tomographic three-dimensional render of the reconstruction plate.



**Figure 5:** Postoperative clinical photograph of the patient.

The AP was vertically designed parallel to the imaginary occlusal plane through the gonial angle. It was assumed that the reconstructed vertical level by the plate and ALT flap would be similar to the original alveolar height. The anterior arch was designed according to the original shape and continued to the mandibular remnants in the horizontal view. Finally, the simulated mandibular model was fabricated. The reconstruction plate was pre-bent to fit the lower border of the simulated model and then the plate positioning guide was fabricated. The positioning guide enabled the mandible and the pre-bent reconstruction plate to be placed in stable positions and reproduced the simulated reconstruction [6].

The surgery was performed as preoperative surgical planning. The left partial glossectomy was decided intraoperatively because of poor blood flow, and the wound was closed. The plate was placed on the mandibular remnants using the positioning guide and fixed with titanium screws (Figures 3 and 4). The defects of the mandibular alveolus and floor of mouth were covered with the de-epithelialized ALT flap. The full-thickness defect of the lower lip was reconstructed by advancement flaps (Fries method) and lip competence was maintained. Because the ALT flap is thicker than the floor of mouth mucosa, ALT flap reconstruction reduced the original oral cavity space, which offered advantages in swallowing in this case. Even if the flap gradually atrophies with time, a tongue space similar to the original would be maintained. During the postoperative period, speech and swallowing rehabilitation was provided and a palatal augmentation prosthesis was delivered (Figure 5). Nutrition was obtained by mouth and gastrostomy tube feeding. Consequently, the plate planning provided optimal results for the patient.

## Discussion

For immediate reconstruction after segmental mandibulectomy, a plate with soft tissue transfer is an option for patients who are intolerant of long operations. However, plate reconstruction following segmental central mandibulectomy has been showed a high rate of plate exposure. Although plate setback is useful for reducing plate-related complications, little information is available on this technique. This report outlines how to design the plate setback following segmental central mandibulectomy using 3D simulation and modelling, and how to apply the system to the surgery. The 3D simulation and modelling delivers valuable information and enables surgeons to fully understand the surgical process, which ensures the quality of the plate reconstruction. Further study with a number of patients is necessary to clarify the optimal degree of setback relative to the original mandible.

## Conclusion

A plate with soft tissue transfer is a useful reconstruction following segmental central mandibulectomy for patients who are intolerant of long operations.

To reduce postoperative complications, the multidisciplinary managements including surgical simulation, surgical treatment and functional rehabilitation in perioperative periods are necessary for the patients who undergo segmental mandibulectomy. 3D simulation and modeling of plate setback for reconstruction following segmental central mandibulectomy and application of the system to the surgery could offer predictable and optimal outcomes.

## Conflicts of Interest

Authors declare that there is no competing interest.

## Acknowledgements

The authors acknowledge Dr. Takenori Ogawa, Department of Otolaryngology-Head and Neck Surgery, Tohoku University Graduate School of Medicine, for technical support and Hiroaki Kato and Natsuki Aizawa, Dental Laboratory, Tohoku University Hospital, for the 3D simulation. No specific grants were received for this study.

## References

1. Li Z, Zhao Y, Yao S, Zhao J, Yu S, et al. (2007) Immediate reconstruction of mandibular defects: a retrospective report of 242 cases. *J Oral Maxillofac Surg* 65: 883-890.
2. Urken ML, Buchbinder D, Costantino PD, Sinha U, Okay D, et al. (1998) Oromandibular reconstruction using microvascular composite flaps: report of 210 cases. *Arch Otolaryngol Head Neck Surg* 124: 46-55.
3. van Gemert J, Holtslag I, van der Bilt A, Merckx M, Koole R, et al. (2015) Health-related quality of life after segmental resection of the lateral mandible: Free fibula flap versus plate reconstruction. *J Craniomaxillofac Surg* 43: 658-662.
4. Nicholson RE, Schuller DE, Forrest LA, Mountain RE, Ali T, et al. (1997) Factors involved in long- and short-term mandibular plate exposure. *Arch Otolaryngol Head Neck Surg* 123: 217-222.
5. Onoda S, Kimata Y, Yamada K, Sugiyama N, Onoda T, et al. (2012) Prevention points for plate exposure in the mandibular reconstruction. *J Craniomaxillofac Surg* 40: e310-314.
6. Zheng GS, Su YX, Liao GQ, Chen ZF, Wang L, et al. (2012) Mandible reconstruction assisted by preoperative virtual surgical simulation. *Oral Surg Oral Med Oral Pathol Oral Radiol* 113: 604-611.