

Utero-Vesical Fistula: A Case Report

Okafor II^{*}, Amu CO² and Ogbodo SC¹

¹Departments of Obstetrics and Gynecology, Enugu State University of Science and Technology, Teaching Hospital, Parklane, Enugu, Nigeria

²Department of Surgery, College of Medicine, University of Nigeria, Enugu, Enugu State, Nigeria

Abstract

Background: Uterovesical fistula is a rare, but serious complication of caesarean delivery. Method: The case note of the patient was reviewed and summarized. Literature review on uterovesical fistula was done and the results compared with this report.

Results: The patient had an emergency caesarean delivery for prolonged obstructed labour that was complicated with wound infection and nine months after the surgery with cyclic haematuria, vaginal amenorrhoea and urinary continence (Youssef's syndrome). Exploratory laparotomy with a urologist confirmed uterovesical fistula which was successfully repaired.

Conclusion: Team management is advocated during a uterovesical repair when difficulties are anticipated.

Keywords: Uterovesical fistula; Caesarean delivery; Team repair

Introduction

Youssef described a pathological communication between the uterus and bladder after a lower segment caesarean delivery as a syndrome of cyclic haematuria (menouria), amenorrhoea and urinary continence in 1957 [1]. Utero-vesical fistula is rare and account for 1-4% of urogenital fistulae [2]. About 800 cases have been reported worldwide. Caesarean delivery accounts for about 88% causes of utero-vesical fistulae [3,4]. Other very rare causes of the fistula include curettage, migration of an intrauterine contraceptive device, high forceps delivery, placenta percreta, manual removal of placenta, and uterine artery embolization. There is usually a history of a precipitating trauma, haematuria, leakage of urine, cyclic menouria, amenorrhoea and infertility. Investigations for the diagnosis of uterovesical fistula include trans-abdominal and trans-vaginal ultrasonography, hysterosalpingography, cystoscopy, intravesical instillation of methylene blue, intrauterine insufflation of air, transperitoneal and transvesical fistulography [1,5,6]. Intravenous urography and computed tomography scan can occasionally be used. Sonohysterography can demonstrate the flow of saline from the uterine cavity into the urinary bladder [6]. Delayed surgical repair is often advocated [7]. Other treatment options include conservative management for 4-8 weeks, immediate surgical repair and hormonal treatment [8-10]. We report our case of uterovesical fistula caused by caesarean delivery which was successfully repaired.

Case Report

Mrs. OG was a 40-year-old Para 1⁺⁰ house wife who presented at Enugu State University of Science and Technology Teaching Hospital, Parklane, Enugu with 9-year history of cyclic haematuria, secondary amenorrhoea and 7-year history of secondary infertility. She had an emergency caesarean delivery on 20/1/2005 in a private hospital for prolonged obstructed labour. A healthy female baby was delivered. The surgery was complicated initially with urinary incontinence that resolved after 14 days of bladder catheterization; wound infection, dehiscence and secondary suturing. Nine months after the delivery, she noticed that she passed blood through the urine every month for 2 days. There was neither associated monthly vaginal bleeding nor urinary incontinence. Her hysterosalpingography (Figure 1) result diagnosed a utero-vesical fistula with uterine synaechia. The abdominal ultrasound also confirmed a utero-vesical fistula between the uterine isthmus and the bladder. She was booked for adhesiolysis and surgical repair of the fistula with a urologist on 1/5/2014. A 1.5×1.0 cm² uterovesical fistula between the upper end of the cervical canal and the posterior base of

bladder wall (about 3 cm above the ureteral openings) (Figure 2) was found. Uterine synaechiae were found to have obliterated the cervical canal below the fistula. The bladder wall was freed from adhesions by sharp dissection and then repaired with vicryl 1 in two layers after identifying the ureteral openings. Adhesiolysis was done (Figure 3) and uterus repaired with vicryl 1 in two layers with a size 6 Hegars dilator inserted into the cervical canal to avoid closing the canal. There was no omental flap interposition. The post-operative recovery was uneventful.

Discussion

Mrs. OG presented nine years post-caesarean delivery for prolonged obstructed labour with the classical signs of Youssef's syndrome: cyclic haematuria (menouria), vaginal amenorrhoea and urinary continence.

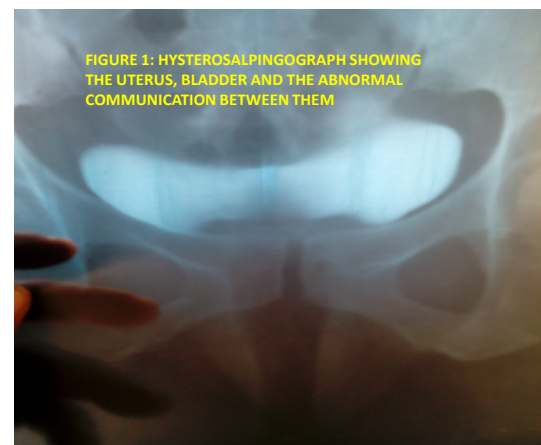


Figure 1: Hysterosalpingograph showing the uterus, bladder and the abdominal communication between them.

***Corresponding author:** Okafor II, Departments of Obstetrics and Gynecology, Enugu State University of Science and Technology Teaching Hospital, Parklane, Enugu, Nigeria, Tel: +2348034006918; E-mail: okaforii@yahoo.com

Received March 26, 2014; **Accepted** June 25, 2014; **Published** June 27, 2014

Citation: Okafor II, Amu CO, Ogbodo SC (2014) Utero-Vesical Fistula: A Case Report. Gynecol Obstet (Sunnyvale) 4: 228. doi:10.4172/2161-0932.1000228

Copyright: © 2014 Okafor II, et al. This is an open-access article distributed under the terms of the Creative Commons Attribution License, which permits unrestricted use, distribution, and reproduction in any medium, provided the original author and source are credited.

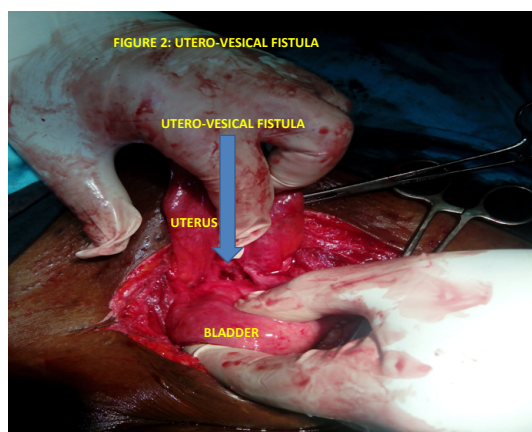


Figure 2: Utero-Vesical Fistula.

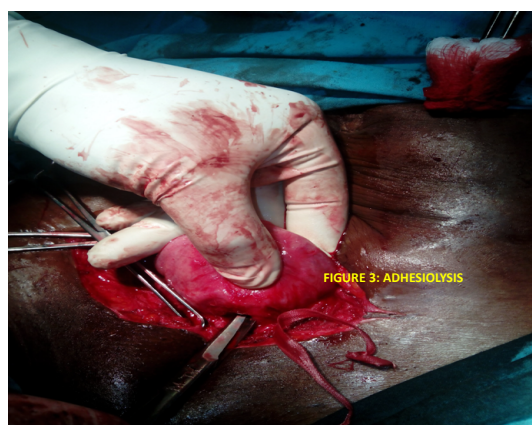

Figure 3: Adhesiolysis.

The majority of the reported cases were due to postcaesarean delivery complications as in our patient [1,4,5,7]. In most reported cases, the diagnoses were delayed as in this patient. Muthir and co-workers advocated a high index of suspicion in cases of post-caesarean delivery haematuria for early diagnosis of this syndrome and prevention of the associated complications [11]. Abdominal ultrasonograph and hysterosalpingography were employed to confirm uterovesical fistula in our patient. A simpler methylene blue test could also be used. This patient was continent of urine after the bladder catheterization for 14 days. The uterine synechia prevented urine and menstrual blood flow through the vagina. The higher resting uterine pressure of 8-12 mmHg could also prevent urine from the urinary bladder (with less resting pressure of <7.4 mmHg) from flowing into uterus through the tract [11]. The bladder of our patient may have been injured during the prolonged obstructed labour or when the suture used to close the uterine incision accidentally included the bladder. The cause of uterine synechia was mostly like due to poor surgical techniques during the caesarean delivery. Surgery is the definitive treatment in most of the cases of uterovesical fistulas. Surgical repair of Mrs. OG fistula was through transperitoneal access. Other routes of repair depend on location of the fistula and include vaginal, transvesical retroperitoneal and extravesical extraperitoneal routes. Prevention of obstructed labour with the use of partograph, employment of good surgical techniques with adequate downwards reflection of bladder with bladder retractor could have prevented this

syndrome and the associated complications especially infertility in Mrs. OG. Conservative management with 4-8 weeks bladder catheterization may prevent this complication especially when the fistula is small. In conclusion, Youssef's syndrome and the associated complications are preventable with proper management of labour with partograph, good surgical techniques and high index of suspicion. Team management with a urologist is advocated during a uterovesical fistula repair when difficulties are anticipated.

References

1. Youssef AF (1957) Menouria following lower segment cesarean section: A syndrome. *Am J Obstet Gynecol* 73: 759-767.
2. Iloabachie GC, Njoku O (1985) Vesico-uterine fistula. *Br J Urol* 57: 438-439.
3. Jozwik M, Jozwik M, Lotocki W (1997) Vesicouterine fistula-an analysis of 24 cases from Poland. *Int J Gynaecol Obstet* 57: 169-172.
4. Ikechebelu JI, Ugboaja JO, Okeke CF (2011) Post-cesarean vesicouterine fistula (Youssef syndrome): report of two cases. *J Obstet Gynaecol Res* 37: 912-915.
5. Park BK, Kim SH, Cho JY, Sim JS, Seong CK (1999) Vesicouterine fistula after cesarean section: ultrasonographic findings in two cases. *J Ultrasound Med* 18: 441-443.
6. Fenkci IV, Demirbas M, Oztekin O (2010) Sonohysterography in evaluation of Youssef's syndrome. *Int Urogynecol J* 21: 607-608.
7. Porcaro AB, Zicari M, Zecchini Antonioli S, Pianon R, Monaco C, et al. (2002) Vesicouterine fistulas following cesarean section: report on a case, review and update of the literature. *Int Urol Nephrol* 34: 335-344.
8. Eogan M, McKenna P (2003) Conservative management of a traumatic uterovesical fistula (Youssef's syndrome). *Eur J Obstet Gynecol Reprod Biol* 110: 114-116.
9. Bettez M, Breault G, Carr L, Tu le M (2011) Early versus delayed repair of vesicouterine fistula. *Can Urol Assoc J* 5: E52-55.
10. Yokoyama M, Arisawa C, Ando M (2006) Successful management of vesicouterine fistula by luteinizing hormone-releasing hormone analog. *Int J Urol* 13: 457-459.
11. Muthir JT, Amu O, Liman H (2010) Successful repair of iatrogenic cyclical menouria: a case report. *Niger J Clin Pract* 13: 344-346.