

Upper Gastrointestinal Bleeding (UGB): Causes and Treatment

Aomari A, Seddik H and Benkirane A

Department of Hepato-gastroenterology II, Military Hospital Mohamed V, Rabat, Morocco

*Corresponding author: Aomari A, Department of Hepato-gastroenterology II, Military Hospital Mohamed V, Rabat, Morocco, Tel: 21265365637; E-mail: ayoub.medinterne@gmail.com

Received date: September 05, 2017; Accepted date: September 25, 2017; Published date: October 03, 2017

Copyright: © 2017 Aomari A, et al. This is an open access article distributed under the terms of the Creative Commons Attribution License, which permits unrestricted use, distribution, and reproduction in any medium, provided the original author and source are credited.

Abstract

Aim: The upper gastrointestinal bleeding (UGB) are frequent reasons for urgent consultation. The aim of our study is to determine the causes of upper gastrointestinal Bleeding in patients in our department.

Materials and Methods: A retrospective study over 6 years between June 2011 and March 2017 covering 683 patients with a Upper gastrointestinal bleeding collected at the Gastroenterology II department of the military hospital of Instruction Mohamed V Rabat Morocco.

Results: The average age was 54 years, with a male dominance (75%). The causes of bleeding are dominated by gastroduodenal ulcers and rupture of esophageal varices. The endoscopic hemostasis was performed in 22% of patients, ligation of esophageal varices in 13% of cases, adrenaline injection in 8% of cases, use of hemoclips in 2% of cases and argon plasma coagulation (APC) in 2% of cases.

Conclusion: In our series Ulcerative pathology and portal hypertension are the main causes of upper gastrointestinal bleeding. The development of endoscopic hemostasis techniques has improved the prognosis of upper gastrointestinal bleeding.

Keywords: Upper gastrointestinal bleeding (UGB); Causes; Treatment

Introduction

The upper gastrointestinal bleeding (UGB) are frequent reasons for urgent consultation. They are severe and poor prognosis, sometimes fatal. Their etiological diagnosis is based on the endoscopic examination performed urgently. In the case of upper digestive bleeding the endoscopy should be performed as soon as possible after the hemodynamic stabilization of the patient. This last allows us to precise the location of the bleeding, its type and performed a hemostasis gesture in certain cases. The aim of our study is to determine the causes of upper gastrointestinal Bleeding in patients in our department.

Materials and Methods

It is a retrospective study over 06 years, between June 2011 and March 2017. Concerning 683 patients admitted in emergency of the military hospital Mohamed V Rabat Morocco and who presented a high digestive hemorrhage in form haematemesis or melena. After stabilization of the haemodynamic state of the patients in the emergency room, all the patients benefited from a digestive endoscopy in his service of hepatogastroenterology II of the military hospital V. epidemiological, clinical, endoscopic, and treatment were recorded and analyzed. The analysis was performed by SPSS Software Version 15.0 (SPSS Inc., Chicago, IL).

Results

Epidemiological data

The average age was 54 years, with a male dominance (75%) (512 Men, 171 women). Concerning the history of patients, 19% had liver cirrhosis, 9% had gastroduodenal ulcer disease, and 6% had a history of non-steroidal anti-inflammatory drugs (NSAIDs) use.

Clinical data

The clinical symptoms were hematemesis isolated in 49% of cases, melena isolated in 42% of cases and abundant hematochezia in 1% of cases. A blood transfusion was required in 30% of cases because the hemoglobin level was less than 7 g/dl (<7 g/dl). all patients benefited from oxygen therapy 3 L/min with a perfusion of isotonic saline solution 0.90%. Clinical examination was normal in 72% of cases, clinical signs of portal hypertension in 10% of cases, clinical signs of hepatocellular insufficiency in 8% of cases and epigastric pain in 10% of cases.

Morphological data

Digestive endoscopy was performed in all patients after stabilization of the haemodynamic state. The endoscopy was carried out in all our patients, the latter pointed to a peptic ulcer in 34% of the cases (n=236), (the duodenal localization and the type IIb according to the classification of Forrest was the most frequent in 80% of the cases) (Figure 1), oesophageal varices in 22% of the cases (n=154) (Figure 2), gastroduodenitis in 17% of the cases (n=118), oesophagitis in 10% of the cases (n=70), angiodysplasia in 4% of the cases (n=29) (Figure 3),

Mallory Weiss syndrome in 2% of the cases (n=16), gastric cancer in 3% of the cases (n=22), and in 5% of cases (n=38), the endoscopic aspect was normal.

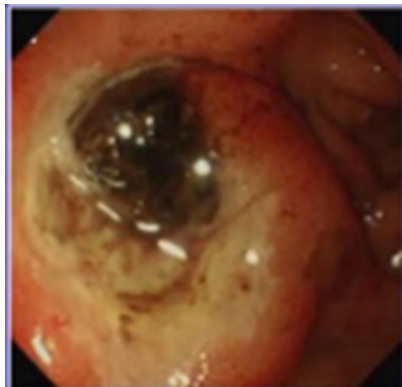

Figure 1: Peptic ulcer forrest class (Iib).

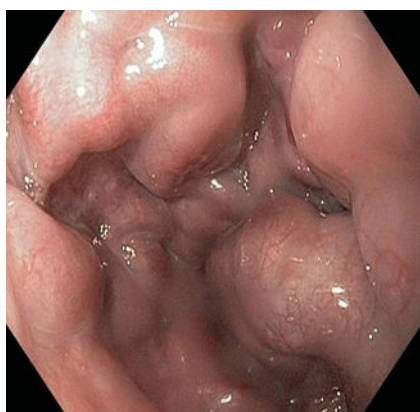


Figure 2: Oesophageal varices (Adherent clot).

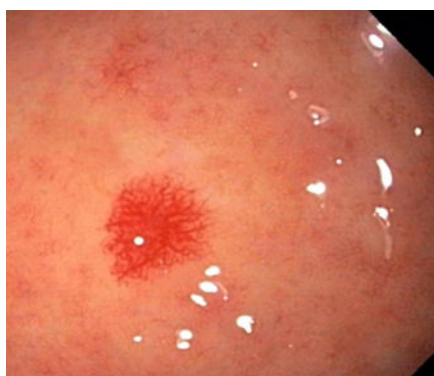

Figure 3: Gastric angiodysplasia.

Endoscopic treatment

During the endoscopy, there was active bleeding in 25% of cases. Endoscopic haemostasis was performed in 22% of patients (n=151): Ligation of the esophageal varices in 13% of cases, adrenaline injections in 8% of cases, the insertion of clips in 2% of cases and argon plasma coagulation (APC) in 2% of cases for angiodysplasia lesions (Figure 4). The 22 patients whose endoscopic examination was in favor of a bleeding tumor were treated surgically. In the absence of active bleeding during endoscopic examination, proton pump inhibitor (PPIs) therapy was indicated by intravenous injection. The evolution was good without recurrence of bleeding. Note also that no recurrence of bleeding occurred after endoscopic hemostasis.

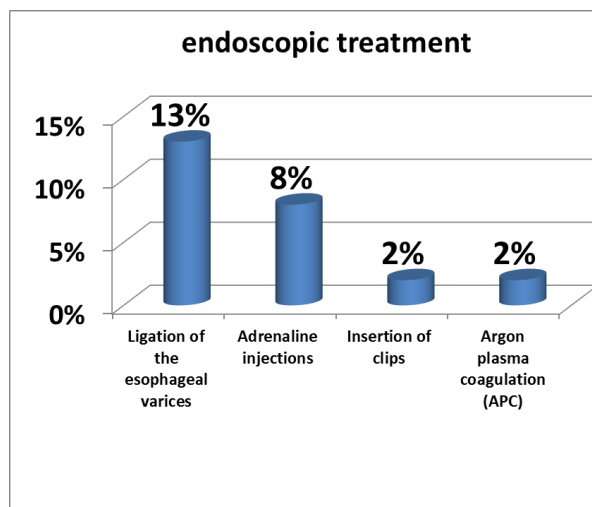


Figure 4: Endoscopic treatment.

Discussion

Upper gastrointestinal bleeding occurs above the ligament of Treitz as a result of duodenal or gastric ulcers, gastric or esophageal varices caused by cirrhosis of the liver, or Mallory-Weiss syndrome. Bleeding that requires more than three units of blood in 24 hours usually demands operative measures. The patient is usually an adult male between the ages of 30 and 50 years. Upper GI bleeding occurs above the ligament of Treitz and arises from the esophagus, stomach, or duodenum. The major causes of upper GI are: duodenal ulceration caused by peptic ulcer disease esophageal and/or gastric varices. Mallory Weiss syndrome, and gastric ulcers [1]. In our study mean age was 54 years and the most common cause was duodenal ulcers. Endoscopy is essential for the diagnosis of the cause of bleeding and endoscopic treatment can reduce re-bleeding, surgery, and mortality [2]. The majority of data published suggest that early endoscopy (generally defined as endoscopy within 24 hours) is safe and can reduce transfusion requirements and length of hospital admission. However, no mortality benefit could be identified with early endoscopy. Several studies have investigated the efficacy of urgent endoscopy (endoscopy performed with 6 or 12 hours) compared with elective endoscopy [3-5]. The results of these studies suggest that urgent endoscopy can reduce hospital stay and amount of blood transfusion. However, outcomes of recurrent bleeding, surgery, and deaths were not associated with urgent endoscopy. Based on these

results, early endoscopy within 24 hours seems to be mandatory for patients with peptic ulcer bleeding while urgent endoscopy within 1 to 4 hours is recommended for patients with clinical evidence of continued bleeding. Endoscopic treatment can be divided into injection, thermal, and mechanical methods (Clips). Injection therapies consists of epinephrine, sclerosants (absolute ethanol, polidocanol), and tissue adhesives (thrombin/fibrin glues). Injection of epinephrine is the most widely used method for hemostasis. It is easy to perform and requires less coordination between the endoscopist and the assistant compared to other methods. Epinephrine injection is effective at achieving initial hemostasis mainly due to a tampon effect [6]. However, epinephrine monotherapy is less effective than other monotherapies such as electrocoagulation, clips, or fibrin glues in preventing further bleeding [7]. Also, adding a second modality such as electrocoagulation or clips is significantly more effective than epinephrine alone in reducing further bleeding and surgery [7]. The optimal volume of epinephrine injection is not known; however, diluted solutions (1:10,000 or 1:20,000) are injected in 0.2 to 2 mL aliquots in all four quadrants of the bleeding stigma. Sclerosant injection significantly reduces further bleeding when compared with no endoscopic therapy [7]. However, sclerosants such as alcohol is not routinely used for treatment of bleeding peptic ulcers, possibly due to concerns for tissue necrosis. Absolute alcohol can be administered in 0.1 to 0.2 mL aliquots with limitations of 1 to 2 mL due to concerns of tissue injury [8]. Thermal contact therapy can be classified into contact or noncontact methods. Contact methods consists of heater probe or bipolar electrocoagulation and noncontact methods consist of argon plasma coagulation [9]. Thermal methods are significantly effective in achieving initial hemostasis, reducing further bleeding, surgery, and mortality. Currently, no significant difference has been found between the different thermal modalities. Clips have been found to be more effective than epinephrine injection in reducing further bleeding and surgery but less effective than thermal therapy. Clips likely do not induce tissue injury which would be a benefit over thermal therapies. Also, training the assistants in handling of the clip is needed for successful application. Another limitation of endoclips is that it is difficult to apply in fibrotic lesions [10]. Esophageal varices are caused by portal hypertension most commonly due to cirrhosis or to portal vein thrombosis. In patients with cirrhosis, the liver becomes fibrotic and hardened and the blood is unable to pass through the liver from the visceral veins. Pressure builds in the portal system and this directly causes enlargement of esophageal varices, which have the potential to rupture and bleed, causing serious clinical problems. If a patient presents with gastrointestinal bleeding and cirrhosis, they need to undergo urgent or emergent endoscopy and the source of the bleed needs to be identified. If the cause is esophageal varices, band ligation is the first-line treatment that should be applied. Patients who fail band ligation therapy and have continued bleeding are candidates for transjugular hepatic portosystemic shunting (TIPS) therapy. The first thing that should be done for a patient with esophageal bleeding, or cirrhosis and any gastrointestinal bleeding, is to provide volume resuscitation and an attempt to correct any coagulopathy. Endoscopic

examination allows the direct visualization of the varices and the source of bleeding, which can be active spurting or bleeding, or a red dimple, which is a sign of a recent bleed. Other causes of bleeds, including ulcers and portal gastropathy, can also be assessed at this time [11,12].

In our study, during the emergency endoscopic examination, active bleeding was in 25% of cases. The endoscopic treatment indicated was oesophageal ligation in 13% of cases, adrenaline injection in 8% of cases, use of clips in 2% of cases, and argon plasma coagulation in two cases for treatment of angiodysplasia. Evolution was good no recurrence of bleeding, after endoscopic hemostasis.

Conclusion

In our series Ulcerative pathology and portal hypertension are the main causes of upper gastrointestinal bleeding. The development of endoscopic hemostasis techniques has improved the prognosis of upper gastrointestinal bleeding.

References

1. Halmagyri AF (1970) A critical review of 425 patients with upper gastrointestinal hemorrhage. *Surg Gynecol Obst* 130: 419-430.
2. Cook DJ, Guyatt GH, Salena BJ, Laine LA (1992) Endoscopic therapy for acute nonvariceal upper gastrointestinal hemorrhage: A meta-analysis. *Gastroenterology* 102: 139-148.
3. Lin HJ, Wang K, Perng CL, Chua RT, Lee FY, et al. (1996) Early or delayed endoscopy for patients with peptic ulcer bleeding. A prospective randomized study. *J Clin Gastroenterol* 22: 267-271.
4. Lee JG, Turnipseed S, Romano PS, Vigil H, Azari R, et al. (1999) Endoscopy-based triage significantly reduces hospitalization rates and costs of treating upper GI bleeding: A randomized controlled trial. *Gastrointest Endosc* 50: 755-761.
5. Bjorkman DJ, Zaman A, Fennerty MB, Lieberman D, Disario JA, et al. (2004) Urgent vs. elective endoscopy for acute non-variceal upper-GI bleeding: An effectiveness study. *Gastrointest Endosc* 60: 1-8.
6. Lau JY, Barkun A, Fan DM, Kuipers EJ, Yang YS, et al. (2013) Challenges in the management of acute peptic ulcer bleeding *Lancet* 381: 2033-2043.
7. Laine L, McQuaid KR (2009) Endoscopic therapy for bleeding ulcers: An evidence-based approach based on meta-analyses of randomized controlled trials. *Clin Gastroenterol Hepatol* 7: 33-47.
8. Laine L (1990) Multipolar electrocoagulation versus injection therapy in the treatment of bleeding peptic ulcers. A prospective, randomized trial. *Gastroenterology* 99: 1303-1306.
9. Kim KB, Yoon SM, Youn SJ (2014) Endoscopy for nonvariceal upper gastrointestinal bleeding. *Clin Endosc* 47: 315-319.
10. Yeh RW, Kaltenbach T, Soetikno R (2006) Endoclips. *Tech Gastrointest Endosc* 8:211.
11. Yan BM, Lee SS (2006) Emergency management of bleeding esophageal varices: Drugs, bands or sleep? *Can J Gastroenterol* 20: 165-170.
12. Garcia-Pagan JC, Bosch J (2005) Endoscopic band ligation in the treatment of portal hypertension. *Nat Clin Pract Gastroenterol Hepatol* 2: 526-535.