

Unusual Cause of Abdominal Pain in a Child

Eyad Altamimi*

Department of Pediatrics, Mu'tah University, Jordan

*Corresponding author: Eyad Altamimi, Assistant Professor, Pediatric Gastroenterologist, Department of Pediatrics, Faculty of Medicine, Mu'tah University, Alkarak 61710, Jordan, Tel: 00962779126857; E-mail: eyadtamimi@mutah.edu.jo

Rec date: Apr 28, 2015, Acc date: Apr 29, 2015, Pub date: Apr 30, 2015

Copyright: © 2015 Altamimi E. This is an open-access article distributed under the terms of the Creative Commons Attribution License, which permits unrestricted use, distribution, and reproduction in any medium, provided the original author and source are credited.

Clinical Image

A 3-year-old boy presented with left upper abdominal pain mainly when eating. No nausea, vomiting or change in bowel habit. His exam showed a well-grown child with normal growth parameters. His vital signs were stable. He had no pallor or jaundice. His abdominal exam showed a fixed indentation at the left subcostal area. No tenderness or organomegaly and the rest of exam were not significant.

His basic work-up was normal. Abdominal CT scan showed that the anterior cartilaginous part of the left lower rib is abnormal, with

indentation on the abdominal wall and compressing of the anterior wall of the stomach (Figure 1).

During eating with the distention of the stomach, the compressing on the stomach wall exaggerated which seemed to cause him the pain. Patient was referred to surgery. The family refused any surgical intervention. The patient did well on follow-up, although the pain still present.

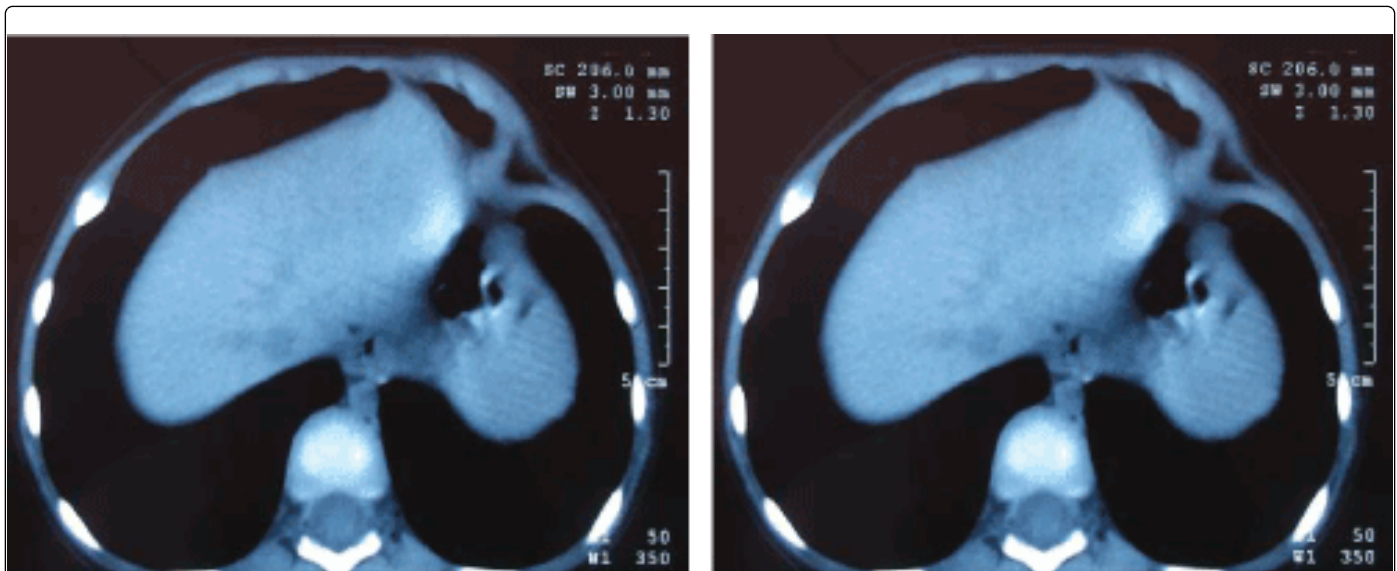


Figure 1: Abdominal CT scan.