

Tumor Therapy with *Amanita phalloides*: Remission of a Tumor Disease and Dietary Effect of Sugar

Isolde Riede*

Independent Cancer Research, Im Amann 7, D-88662 Überlingen, Germany

Abstract

Molecular events that cause tumor formation upregulate a number of HOX genes, called switch genes, encoding for RNAPolymeraseII transcription factors. Thus, RNAPolymeraseII is used to full extent in tumor cells but not in somatic cells. *Amanita phalloides* contains amanitin, inhibiting RNAPolymeraseII. Application of *Amanita phalloides* influences tumor cell (but not normal cell) activity. Dilutions of *Amanita phalloides* are applied to a patient with both, colon carcinoma and thyroid carcinoma. Monitoring tumormarkers, different doses of Amanita are applied. After two years of stabilization, somatic investigations and imaging methods reveal complete remission. Change of dietary practice with the addition of daily 70 gram sugar lead to increase of tumormarker values. Following dietary without sugar and reduced carbohydrates decrease tumormarker values. With sugar, tumor activity increase despite Amanita tumor therapy, therefore, poor carbohydrate diet supports the therapy.

Keywords: Tumor therapy; *Amanita phalloides*; Remission; Colon carcinoma; Thyroid carcinoma; Dietary effect

Introduction

Cell destroying therapies like chemotherapy, using the cellular program of apoptosis induction so far are not successful in elongating life of a patient. This lies within a resistance of tumor cells to many drugs, and their inherited inability to induce apoptosis [1]. In classic sense, *Amanita phalloides* is used to combat fear of death. In molecular sense, this extraction was newly discovered to have properties that inhibit the growth of tumor cells. Amanitin in the extract of Amanita inhibits RNAPolymeraseII (RNAPII) in all cells. RNAPII is used by 100% in tumor cells due to overexpression of switch genes, that use RNAPII [2,3]. Less RNAPII are active in normal cells. Inhibition of 50% of RNAPII reduces tumor cell activity without side effects. The immune system is able to detect and attack tumor cells, the possibility for stabilization and healing opens up. Amanita therapy can stabilize a number of tumor diseases [4,5,6]. Therapy optimized by monitoring is important. It is not necessary to encroach on the patient's quality of life. Dietary habits influence the risk of cancer. High levels of meat, especially pig consumption are a known risk factor for colon, breast, prostate, kidney, lung, and pancreas carcinomas. Cancer cells prefer to catabolize carbon hydrate, especially glucose. Positron Emission Tomography (PET-scan) uses radiolabeled glucose syrup. Glucose accumulates in tumor cells, which are scanned to detect the localization of active tumors. A number of cancer diets, for example from Dr. Coy or Ms. Budwig, reduce carbohydrate nutrition. It is crucial to avoid all types of sugars, including those in various processed products with extra sugar content. Tumor cells might grow faster with large amounts of easily absorbed sugars. Whereas some studies find, that lower consumption of total sugars are associated with lower risk to develop a tumor, others find that a diet with a low proportion of carbohydrates and a high proportion of fat might increase the risk of carcinoma [7,8]. So far, no tumor therapy based on only dietary regimen had been successful. Monitoring of the reaction of dietary consumption of sugar in a single patient is missing. To support all therapies, consumption of essential unsaturated fatty acids is important. They are found in high-quality oils such as flax seed oil. Essential fatty acids are nutrient for the cellular membranes, and keep them fluid. Olive oil in addition bears polyphenols, acting as anti-oxidants. Dietary antioxidants are emerging as potentially modifiable risk factors for tumor formation [9]. Antioxidants protect the cellular

membranes from oxidation, i.e. prevent saturation of the essential fatty acids. Obviously, there is a correlation between a damaged cell membrane function and functions of the immune cells communicating over membrane receptors.

Here a therapy of a patient with various cancer diseases is presented. In a novel approach, two different tumors in one patient are stabilized, upon monitoring of tumor markers with varying doses of Amanita. This results in complete remission of both tumor diseases after two years of Amanita treatment, carbohydrate reduced and sugarless diet. The patient ignored the diet, resulting in increased tumor marker values. Within the third year of treatment, the disease can be restabilized with a restarted carbohydrate reduced diet.

Materials and Method

Within ten years of therapeutic experience with Amanita, a therapy schema was developed, titrating *Amanita phalloides* dilutions in cancer patients with various tumor diseases, and monitoring tumormarkers, clinical picture, and imaging methods. Good results can be achieved in the stabilization of patients without pretreatments. *Amanita phalloides* is applied in D2, D3, and D4 dilutions for tumor therapy [Herbamed AG]. The medication, "certified by Riede", is created to inhibit 50% of RNAPII, with 100 ml D2, prescribed for example "100 ml *Amanita phalloides* (cert. Riede) D2". *Amanita phalloides* toxic effects might appear by uptake of ten liters of D2 at once. Anyhow, this dose lies far beyond the therapeutic dose of up to 50 ml per month. Depending on the urgency of treatment, the maximal daily dose is 4×20 of D2 drops. Standard dosing is 4×10 drops of D2 per day. This dose can be applied for years without side effects. Within 2 months 100 ml of D2 are

*Corresponding authors: Isolde Riede, Independent Cancer Research, Im Amann 7, D-88662 Überlingen, Germany, Tel: 49 7551 932 695; E-mail: riede@tumor-therapie.info

Received September 24, 2013; Accepted November 12, 2013; Published November 14, 2013

Citation: Riede I (2013) Tumor Therapy with *Amanita phalloides*: Remission of a Tumor Disease and Dietary Effect of Sugar. J Cell Sci Ther 4: 147. doi:10.4172/2157-7013.1000147

Copyright: © 2013 Riede I. This is an open-access article distributed under the terms of the Creative Commons Attribution License, which permits unrestricted use, distribution, and reproduction in any medium, provided the original author and source are credited.

administered. At this time, a change in monitoring parameters should be visible. Uptake perlinguale for 5 minutes is recommended. The drug is permissive through the oral mucosa. If the drug would be swallowed directly, it would reach the portal vein and is intercepted by the liver. Tumormarkers are monitored. Tumormarkers rise exponentially by growing of tumors in untreated patients. If the tumormarker values sink, tumor cell activity decreases. However, one single tumormarker is not sufficient for monitoring the therapy. Digestion of tumor cells by the immune system can cause the tumormarkers to rise, because lysing tumor cells can release tumormarker. This can be detected by measurement of Lactate-Dehydrogenase (LDH). LDH levels rise when cells lyse. If a tissue specific tumormarker and LDH rise, not a tumor growth, but tumor digestion is identified.

At the beginning of the therapy and after one or two years, magnetic resonance imaging (MRI) should evaluate the tumor dimensions. An untreated tumor appears as cavity in sonogramms, during therapy the density of the tumor tissue can change. If tumor is digested, the tumor can fill with cysts. During therapy, the blood circulation to the tumor might decrease. Tumor cells are highly active cells. Amanitin is a peptide, and is absorbed into tumor cells from the circulating blood. The tumor might contract. This can lead to increase or reduction in tumor pain. Amanitin accumulates and catabolizes slowly in the cells. Within half a year without treatment, amanitin is completely degraded.

The therapy can lead to a local swelling or other inflammation symptoms. Lymph nodes swell as a result of involvement of the immune system by digestion of the tumor, fever occurs. The tumor can bleed. Should severe side effects appear, it is recommended to reduce the dose to 5 drops of D2 per day for a week.

In addition to the Amanita therapy, dietary carbohydrates are reduced, and sugar completely avoided. Essential fatty acid uptake is increased, half a liter of plant oil should be ingested per week. Night primrose oil is sometimes additionally added. This oil contains very

long essential fatty acids, which serve as nutrient for prostaglandins, immune system hormones. The status of the essential fatty acids starvation in the body can roughly be measured with a cholesterol (total) test. Cholesterol levels are increased, when essential acids are missing. Membranes can incorporate cholesterol to gain fluidity. The topical application of zinc salve is recommended, zinc should not be taken internally, but rather through the skin. If zinc is taken orally, this will lead to iron deprivation, because zinc and iron use the same transporter in the gut cells, zinc has the higher affinity to the receptor and is transported with priority when present.

Results

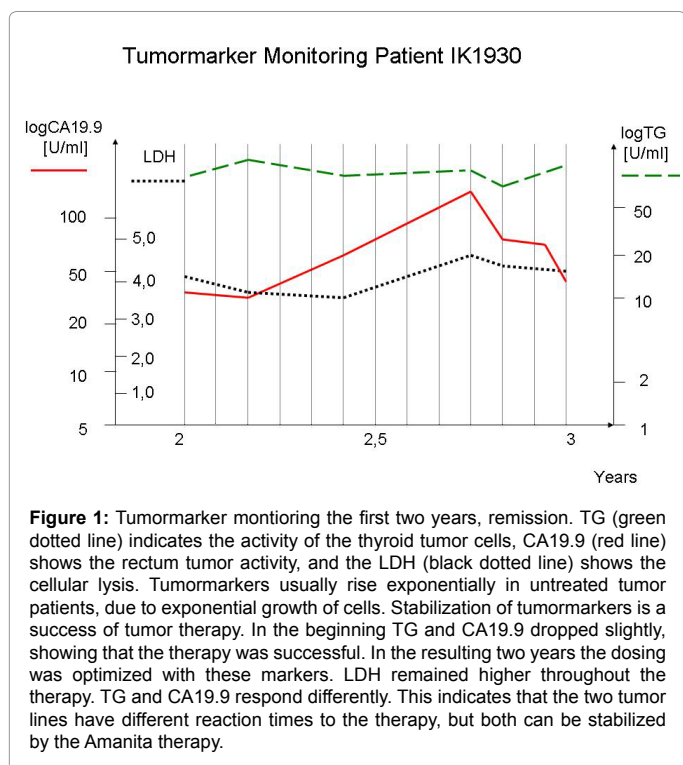
The patient was born in 1930; she worked as soloist-singer in the theater; after marrying she became registrar. She studied music and eventually began teaching music at the Gymnasium (German prep school). Life long she sang daily. During the war she smoked over a year and a half, up to 30 cigarettes a day, but gave it up because it damaged her singing voice. Her half-sister suffered ovarian cancer and died at 46; her older sister was diagnosed with rectal cancer but lived to be 90. Her cholesterol level was around 220 mg/dL and remained constant.

The patient was diagnosed in 1995 with rectal cancer which was removed surgically. In 1999 a relapse occurred that was also treated operatively, she obtained a stoma. No metastases were found nor affected lymph nodes. She obtained chemotherapy. Successive colonoscopies indicated ongoing polyp formation.

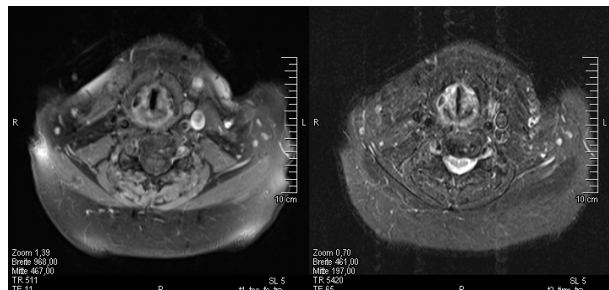
In March 2009 a thyroid cancer was diagnosed (pT3pNxcM0L1V1r0). After radiation therapy a large tumor (50 × 38 × 42 mm) was surgically removed. Tumor tissue around the esophagus and trachea could not be completely removed. Another radiation followed in March 2010, which could also not completely remove the tissue around the esophagus. A PET/CT scan showed a tumor in the jugular area, 37 × 42 × 36 mm, as well as a prominent lymph node, left cervically, measuring 55 mm. An MRI in October 2010 confirmed relapse. The patient was booked for an operation, but asked for time to think about her treatment.

She began Amanita therapy in mid-October 2010. She weighed 100 kg (220 lbs). Initial dose was 2 × 5 drops of D2, until test results were obtained. LDH and the tumor markers CA19.9 (pancreas, gallbladder, intestine) and Thyreoglobulin (TG, thyroid) were monitored. As CA19.9 and TG were both elevated, rectal tumor cells from 1995 and thyroid tumor cells from 2009 were both still active. The dose was increased to 2 × 10 drops of D2 per day. Figure 1 shows monitoring of the tumormarker over two years.

In December 2010 both markers showed a change; LDH was slightly elevated, which indicates cellular lysis, both tumor markers fell, the activity of the tumor cells was reduced. In January 2011 the patient noticed brown sputum after taking 150 ml of the D2. In March 2011, after taking 180 ml D2, she noticed yellow skin tone. The cysts in her larynx stabilized. The dose was lowered to 3 × 5 drops of D2 per day. In May 2011, after uptake of 200 ml D2, she experienced fever, vomiting, cough, and diarrhea. The TG was slightly elevated, and the dose was adjusted to 4 × 5 drops D2 per day. In June 2011 tumor markers increased, leading to an elevated dose of 4 × 10 drops D2 per day. In July 2011 she suffered an ileus, which was relieved by endoscopy and enema. CT scan showed no tumor involvement. In October 500 ml of D2 were taken, saliva was light brown. In December 2011 the patient suffered psychological crisis that needed no intervention. In December 2011 an MRI showed that the original tumor around the trachea disappeared (Figure 2).



MRI of Patient IK1930



No Remaining Tumor Visible

Figure 2: MRI shows remission. Shown are two separate MRI pictures from December 2011 on two different levels from the area where in 2009 and 2010 tumors were visible. Both the former swollen lymph node and the tumor around the trachea and esophagus disappeared.

Tumormarker Monitoring Patient IK1930

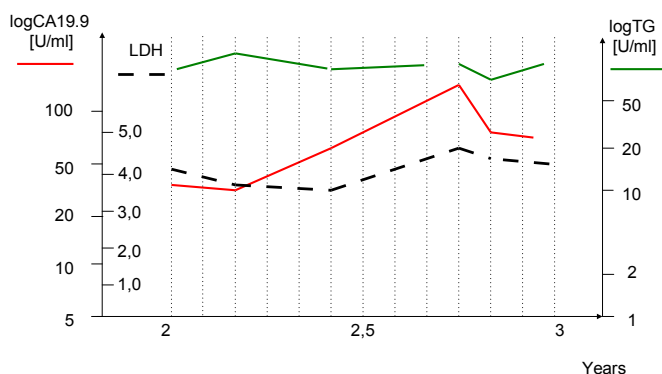


Figure 3: Tumormarker monitoring over a nutritional change. After two years and two months of stabilization and remission, the patient started to eat carbon hydrates, in average 30 grams sugar per day, whereas the Amanita therapy is continued. The TG level (green), representing thyroid cancer cells activity remains stable. CA19.9 (red) increases threefold, representing rectum carcinoma cells. The increase appears linear in the half-logarithmic graph, meaning exponential growth of cells. Seven months later, carbohydrate reduced and sugar free nutrition restabilizes the values.

During 2012 the patient continued uptake of 4×10 drops D2 daily, to further stabilize the tumor. In total, approximately 1.4 liters of D2 were taken within two years. In March 2012 the patient experienced a sticking pain in her throat, which radiated throughout her entire body and disappeared within 10 minutes. In May 2012 she realized that she could sing again, which she hadn't been able to do for years. In November 2012 bloody sputum occurred; she showed signs of a cold.

A colonoscopy from November 2012 showed disappearance of the polyps. Therefore it can be assumed that the patient achieved a full remission. After successful remission, the patient decided, to continue Amanita therapy, but not to follow further dietary suggestions. She began to eat a chocolate bar every day. This resulted in an increase of CA19.9 (Figure 3), TG levels were less affected. Anamnesis revealed the dietary fault, after half a year of continuous increase of CA19.9 to the threefold value.

Interestingly, only the colon tumor cells reacted upon the sugar uptake, but not the thyroid cancer cells. Restarting the sugar free diet decreased CA19.9 to half of the value within one month. The patient decided to continue Amanita therapy lifelong in conjunction with sugar free diet.

Discussion

Amanita therapy successfully stabilizes a number of tumor diseases, here treatment of a patient with two different active tumors is presented. Within two years, complete remission was achieved. The patient enjoyed high quality of life throughout the therapy, no hospitalization due to the tumor was required. Management of the therapy is easy, no infusions are necessary, the drug is stable at room temperature and the oral uptake can be embedded into everyday life. In most regimens, patients are defined as being healthy after remission, new upcoming tumors might presumably be as frequent as relapses. But monitoring tumor marker values reveal, that even after years of successful treatment with Amanita still tumor cells persist. Pausing the therapy leads to an increase of the monitoring markers. Thus, Amanita therapy is recommended as lifelong treatment. Scientific research recommends a balanced diet to protect against cancer. Most regimens use a carbohydrate reduced diet containing unprocessed components. Here through monitoring tumor markers, the effect of sugar consumption on tumor cell activity could be detected. Whereas the thyroid cancer cells are less affected, threefold increase of the activity of rectal tumor cells revealed. In sum, a supportive diet for cancer prevention and for cancer patients includes: vegetables, fruits, and wild herbs/plants in their natural state, and rich, high-quality unsaturated fatty acids in form of plant oils. Amanita therapy and dietary recommendations seem to offer new possibilities to many patients.

References

- Riede I (2012) Inhibition of Apoptosis in ALL-1 Leukemic Cell Lines: Allowance of Replication, Constant Repair Replication, Defect DNA Damage Control. J Cell Sci Ther 3: 133.
- Riede I (2004) Switch Genes in Tumor Formation.
- Rozovskaia T, Feinstein E, Mor O, Foa R, Blechman J, et al. (2001) Upregulation of Meis1 and HoxA9 in acute lymphocytic leukemias with the t(4 : 11) abnormality. Oncogene 20: 874-878.
- Riede I (2010) Tumor therapy with Amanita phalloides (death cap): stabilization of B-cell chronic lymphatic leukemia. J Altern Complement Med 16: 1129-1132.
- Riede I (2011) Tumor therapy with Amanita phalloides (Death Cap): stabilization of mammary duct cancer. TANG Intern J Genuine Trad Med 1: 5.1-5.3.
- Riede I (2012) Tumor Therapy with Amanita phalloides (Death Cap): Long Term Stabilization of Prostate Cancers. J Integr Oncol 1: 101.
- Fedirko V, Lukanova A, Bamia C, Trichopolou A, Trepo E, et al. (2013) Glycemic index, glycemic load, dietary carbohydrate, and dietary fiber intake and risk of liver and biliary tract cancers in Western Europeans. Ann Oncol 24: 543-553.
- Lagergren K, Lindam A, Lagergren J (2013) Dietary proportions of carbohydrates, fat, and protein and risk of oesophageal cancer by histological type. PLoS One 8: e54913.
- Ibibebe TI, Hughes MC, Nagle CM, Bain CJ, Whiteman DC, et al. (2013) Dietary antioxidants and risk of Barrett's esophagus and adenocarcinoma of the esophagus in an Australian population. Int J Cancer 133: 214-224.