

## Triploidy/Diploidy Mosaicism, Diandry and Uniparental Isodisomy: Fetus with Omphalocele and Contracted Finger

Fatma Silan<sup>1</sup>, Ayse Nur Cakir Gungor<sup>2</sup>, Mine Urfali<sup>1</sup>, Ahmet Uludag<sup>1</sup>, Evren Cavus<sup>2</sup>, Evrim Koc<sup>2</sup> and Ozturk Ozdemir<sup>1</sup>

<sup>1</sup>Department of Medical Genetics, Canakkale Onsekiz Mart University, Turkey

<sup>2</sup>Department of Obstetrics and Gynecology, Canakkale, Turkey, Canakkale Onsekiz Mart University, Turkey

\*Corresponding author: Prof. Dr Fatma Silan, Department of Medical Genetics, Canakkale Onsekiz Mart University Faculty of Medicine, 17100, Çanakkale, Turkey, Tel: 90 286 263 59 50- 1080; Fax:+90 286 2635956; E-mail: [fsilan@yahoo.com](mailto:fsilan@yahoo.com)

Rec date: May 18,2015; Acc date: July 14,2015; Pub date: July 21,2015

Copyright: © 2015 Silan F, et al. This is an open-access article distributed under the terms of the Creative Commons Attribution License, which permits unrestricted use, distribution, and reproduction in any medium, provided the original author and source are credited.

### Abstract

Omphalocele is an abdominal wall defect that bowel and/or other visceral organs herniate from umbilical ring, which is covered by peritoneal sac. Omphalocele pathogenesis is not clear but familial and genetical factors plays important role to development of omphalocele.

Twenty years old, 19 weeks 4 days pregnant, primigravid patient presented. In her ultrasonographic assessment omphalocele was detected and fetus was death. Pregnancy was terminated and genetic studies were performed from fetal blood and tissue biopsy. Karyotype from intracardiac blood sample was found 46, XX. QF-PCR analysis performed from the DNA obtained from fetal skin biopsy; 4:1 peak ratio observed in all the STR regions. This is the first case shows 4:1 peaks at QF-PCR. This finding was incompatible with karyotype. So mosaicism doubt occurred. FISH from skin biopsy showed diploid/triploid mosaicism.

Fetuses with omphalocele must be evaluated for additional anomalies and genetic consultation. Our case indicates high frequency of mosaicism and the importance of examination from different tissues with different types of genetic methods. Triploid cell line is found only in fibroblasts in about 70% of cases, so this mixoploidy syndrome is likely underdiagnosed. Performing genetic analysis from different tissues and using different techniques are very important for detecting mosaicism and not to miss the genetic etiology of stillbirths and anomalous fetuses.

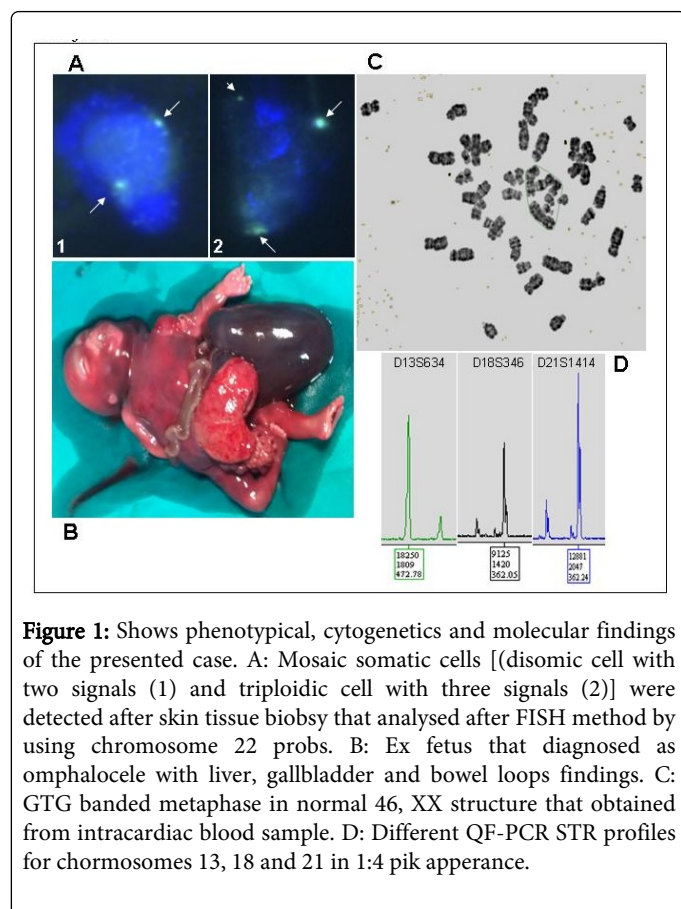
**Keywords:** Triploidy; Mosaic; QF-PCR; Omphalocele; Uniparental disomy; FISH

### Case

Twenty years old, primigravid patient presented. According to her last menstrual period she was 19 weeks 4 days pregnant. There were no significant findings in her background and medical history. She had no prenatal screening test results. In her last ultrasonographic assessment, omphalocele was determined and fetus was dead. Cardiac assessment couldn't be done because fetus was dead. Pregnancy terminated by 200 micrograms misoprostol sublingual per 6 hours. There were no complications during and after termination. While fetus examined morphologically, liver, gallbladder and bowel loops were detected in omphalocele (Figure 1B). Additionally, contractures observed in his left hand fingers 2 and 3 (Figure 1B). Autopsy couldn't be performed because his family didn't allow. So no more anomaly could be determined.

Genetic studies were performed from fetal blood and tissue biopsy. Also genetic karyotyping performed on both mother and father. After pregnancy termination, fetal intracardiac blood sample was obtained by heparinized injector. Metaphases were analyzed and karyotype was found 46, XX (Figure 1C). QF-PCR (Aneufast) analysis performed from the DNA was obtained from fetal skin biopsy. 1:4 peak ratio observed in all the STR regions (Figure 1D). This finding was incompatible with karyotype. So mosaicism doubt occurred.

Touch preparations from skin biopsy used for FISH analysis. Both 2 signals and 3 signals have been seen in different cells proved mosaicism (Figure 1A). Thus fetus evaluated 46 XX/ 69 XXX diploid / triploid mosaics. When fetal STR (Short Tandem Repeat) markers were compared with both maternal and paternal markers it is understood that 1 sized peaks were inherited from mother and 4 sized peaks were inherited from father (Table 1). We thought a triploid embryo gathered from a haploid ovum and a diploid sperm, then lost maternal set of chromosomes and become paternal uniparental isodisomy (diandry). There were no numerical or structural chromosomal aberrations in both maternal and paternal genotyping.



X22	217-222	222-228	222
HPRT	280-288	280	288-280
DXYS218	280-285	276-280	280
DXYS267	341	337	341-337

**Table 1:** Shows the specific QF-PCR STR values for chromosomes 13, 18, 21, X and Y for ex fetus and her parents. The triple unic markers were indicated in black color.

## Discussion

Omphalocele is an abdominal wall defect that bowel and/or other visceral organs herniate from umbilical ring which is covered by peritoneal sac. The prevalence for 11-14 weeks is 1:1000 and the incidence for live-born is 1-2, 5:10000 [1]. Omphalocele pathogenesis is not clear but familial and genetical factors play an important role to development of omphalocele [1]. In the 11-14 weeks, it can be diagnosed easily by ultrasound scan used for nuchal translucency. Prenatal detection rate varies between 83% to 100% [2]. Omphalocele risk increases with maternal age, associations with complex anomalies and umbilical cord cysts. The most common associated malformations are cardiac (up to 47%), genitourinary (40%), neural tube (39%) and diaphragmatic defects [3]. In recent studies, ectrodactyly, absence of thumb, polydactyly and clutch hand have associated with omphalocele [4]. But as far as we know our case is the first study as omphalocele with finger contracture.

Chromosomal abnormalities, especially aneuploidy can be detecting 30-69% cases [5]. The most common chromosomal abnormalities are trisomy 18, trisomy 13 and triploidy. Snijeder et al. published omphalocele in 22.5% of fetuses with trisomy 18, 9.1% of fetuses with trisomy 13 and 12.5% of fetuses with triploidy [6]. Gilbert presented 36 omphalocele cases, 17 fetuses trisomy 18 and only one with triploidy, 17 fetus diagnosed as normal chromosomes but none of them tested for different tissues and none of them diagnosed mosaic [7]. Chen reviewed chromosome anomalies at omphalocele and not only aneuploidies, partial duplications, deletions, marker chromosomes and uniparental disomy (UPD) of 14th chromosome are published [8]. Karyotyping is gold standard for structural chromosomal anomalies, but MLPA is also a good method for microdeletions/duplications, but none of them diagnose UPD. Array CGH and SNP array is new, expensive but a good method for both unbalanced chromosomal anomalies and UPD, but still limitations about mosaicism (like our case) and didn't enough for all cases. Fetuses with omphalocele must be evaluated for additional anomalies and genetic consultation. Our case indicates high frequency of mosaicism and the benefit of examination from different tissues with different types of genetic methods. In our case, if chromosome analysis had been performed only from cord blood, the result would have been found 46, XX which was a misdiagnosis. Analyze performed from skin biopsy was presented mosaicism.

Triploidy is a lethal chromosomal abnormality which has an extra haploid chromosome set from paternal (diandric) or maternal (dyginic). The prevalence is 1:3300 at 11<sup>th</sup>-14<sup>th</sup> weeks [9]. Clinical symptoms of triploidy is quite typical but is rarely reported in near-term stillborns and newborns. Large placenta and edematous fetus with macroglossia, facial clefts, eye defects, dysplastic cranial bones, omphalocele, meningomyelocele, syndactyly, and, in males, genital maldevelopment is suggestive of a triploid chromosomal constitution

STR	Mother	Father	Fetus
D13S258	236-369	240-273	236-240
D13S305	450	437-441	450-441
D13S361	196-287	196	196
D13S634	475-484	472-484	484-472
D13S797	432-440	432-440	432
D18S386	350-361	339-361	361
D18S390	417-421	409-413	417-413
D18S391	159	159	159
D18S535	145	145	145
D18S976	181	181-185	181-185
D21S1411	290	290-303	303
D21S1414	345-352	358-362	345-362
D21S1435	172	172-180	172-180
D21S1446	213-221	210	213-210
D21S1442	144	148-156	144-156
AMXY	105	105-110	105
SRY		463	

are typical clinical symptoms but as our case omphalocele can be the only major abnormality [10]. Most of the triploid fetuses are spontaneously aborted before 20<sup>th</sup> gestation week. After 20<sup>th</sup> gestation week, triploid fetuses are very rare. Wang et al. Reported a case with omphalocele and mosaic 14q trisomy. They also reported that mosaicism ratios are different for amniotic cell culture, placental cells and skin biopsy culture [11].

When fetal STR (Short Tandem Repeat) markers compared with both maternal and paternal markers it is understood that 1 sized peaks were inherited from mother and 4 sized peaks inherited from father. We thought a triploid embryo gathered from a haploid ovum and a diploid sperm has lost maternal chromosomal set and became paternal uniparental isodisomy (diandric).

In triploidies QF-PCR results, 1:1:1 or 1:2 peaks can be observed. Observation of 1:2 peaks of all markers means diploid chromosome set from one of the parents is homozygous. If there had been only triploidy peak ratios we would have seen 1:1:1 or 1:2 peaks. The result of 1:4 (1:2+2) peak ratios in QF-PCR is because of the DNA coming from triploid cells (1:2) and from diandric diploid cells (+2). This is the first case that shows 1:4 peaks at QF-PCR.

QF-PCR provides not only fast results from every tissue which DNA can be isolated without any need to cell culture, but also can determine the which parent's chromosome set is extra by STR analyses and also determine the failure in meiosis 1 or 2. In this respect, QF-PCR is superior to MLPA and microarray methods. Also FISH method is a useful technique for fast diagnosis of aneuploidy and mosaicism of uncultured cells. The usage of FISH and QF-PCR with uncultured cells eliminates the aneuploidies which can occur during cell culture period. Using different genetic technique in different tissues is useful for evaluating prenatal samples, fetus with anomalies, stillbirths, and neonatal deaths, complex aneuploidies which are incompatible with life and mosaic situations of these.

In this case, if genetic analysis had been performed only from cord blood, only karyotyping and/or FISH performed; the result would have been found 46, XX normal. So mosaic triploidy and diandry would be overlooked if QF PCR didn't. According to our study, it must be considered both omphalocele and fetuses with congenital anomalies which presented as "normal" karyotype can be diandric or dyginic or mosaic.

Quigley et al. report a case of 45, X/69, XXY mixoploidy in a neonate with ambiguous genitalia, 3<sup>th</sup>-4<sup>th</sup> finger syndactyly, and multiple congenital heart defects, which was chromosome analysis of lymphocytes found a 45, X karyotype, and cultured fibroblasts showed a 69, XXY karyotype. Because of triploid cell line is found only in

fibroblasts in about 70% of cases, this mixoploidy syndrome is likely underdiagnosed [12]. Also Daniel et al. reported four triploid/diploid mosaic cases and explained their origin with chimeric microsatellites [13].

## Conclusion

Multidisciplinary approach is important for the decision of termination of pregnancy, detection of the true etiological causes for the suitable genetic counseling. Performing genetic analyses from different tissues and using different techniques is very important for detecting mosaicism and not missing the genetic etiology of stillbirths and anomalous fetuses.

## References

1. Flagstad TM, Branchburg A, Blass HG, Vogt C (2014) Prenatal examination and postmortem findings in fetuses with gastroschisis and omphalocele. *Prenat Diagn* 34: 570-576.
2. Syngelaki A, Chelemen T, Dagkdis T, Allan L, Nicoladies KH (2011) Challenges in the diagnosis of fetal non-chromosomal abnormalities at 11-13 weeks. *Prenat Diagn* 31: 90-102.
3. St-Vil D, Shaw KS, Lallier M et al. (1996) Chromosomal anomalies in newborns with omphalocele. *J. Pediatr Surg* 31: 831-834.
4. Port-Lis M, Leroy C, Manouvrier S, Escande F, Passemard S, et al. (2011) A familial syndromal form of omphalocele. *Eur J Med Genet.* 54: 337-340.
5. Brantberg A, Blaas HG, Haugen SE, Eik-Nes SH (2005) Characteristics and outcome of 90 cases of fetal omphalocele. *Ultrasound Obstet Gynecol* 26: 527-537.
6. Snijders RJM, Sebire NJ, Souka A, Santiago C, Nicoladies KH (1995) Fetal exomphalos and chromosomal defects: relationship to maternal age and gestation. *Ultrasound Obstet Gynecol* 6: 250-255.
7. Gilbert WM, Nicolaides KH (1987) Fetal omphalocele: associated malformations and chromosomal defects. *Obstet Gynecol.* 70: 633-635.
8. Chen CP (2007) Chromosomal abnormalities associated with omphalocele. *Taiwan J Obstet Gynecol.* 46: 1-8.
9. Jauniaux E, Brown R, Snijders RJ et al. (1997) Early prenatal diagnosis of triploidy. *Am J Obstet Gynecol.* 176: 550-554.
10. Wertelecki W, Graham JM Jr, Sergovich FR (1976) The clinical syndrome of triploidy. *Obstet Gynecol.* 47: 69-76.
11. Wang JC, Li CF, Shaw DR (2007) Prenatally diagnosed mosaic trisomy 14q with omphalocele. *Prenat Diagn* 27: 1260-1261.
12. Quigley D, McDonald MT, Krishnamuthy V, Kishnani PS, Lee MM, et al. (2005) Triploid mosaicism in a 45,X/69,XXY infant. *American Journal of Medical Genetics* 138A: 171-174.
13. Daniel A, Wu Z, Darmanian A, Collins F, Jackson J (2003) Three different origins for apparent triploid/diploid mosaics. *Prenatal Diagn* 23: 529-534.