

## Transapical Paravalvular Leak Closure: A Case Report

Erdogan Ilkay, Cigdem Koca Tari\*, Alper Canbay and Aysel Yagmur

Department of Cardiology, Liv Hospital, Ankara, Turkey

\*Corresponding author: Cigdem Koca Tari, Department of Cardiology, Liv Hospital, Bestekar Street, Cankaya District, Ankara, Turkey; Tel: +90312 666 40 00; E-mail: cigdem.jp@gmail.com

Received date: 19 June, 2017; Accepted date: 25 June, 2017; Published date: 28 June, 2017

Copyright: © 2017 Ilkay E, et al. This is an open-access article distributed under the terms of the Creative Commons Attribution License, which permits unrestricted use, distribution, and reproduction in any medium, provided the original author and source are credited.

### Abstract

Paravalvular leak (PVL), a serious complication of valve surgery, can be treated with percutaneous techniques. In this article we present a case in which successful mitral PVL closure performed via transapical approach.

**Keywords:** Mitral Valve Replacement; Paravalvular Leak; Transapical Puncture

### Introduction

Paravalvular leak (PVL) which described as abnormal retrograde flow between sewing ring and native valve annulus is a known complication of valvular replacement [1,2]. Depending on its size and location, PVL may cause heart failure, hemolysis or both. Newer percutaneous techniques have been developed for treatment of PVL [3]. Here we present a case in which a transapical PVL closure have been successfully performed.

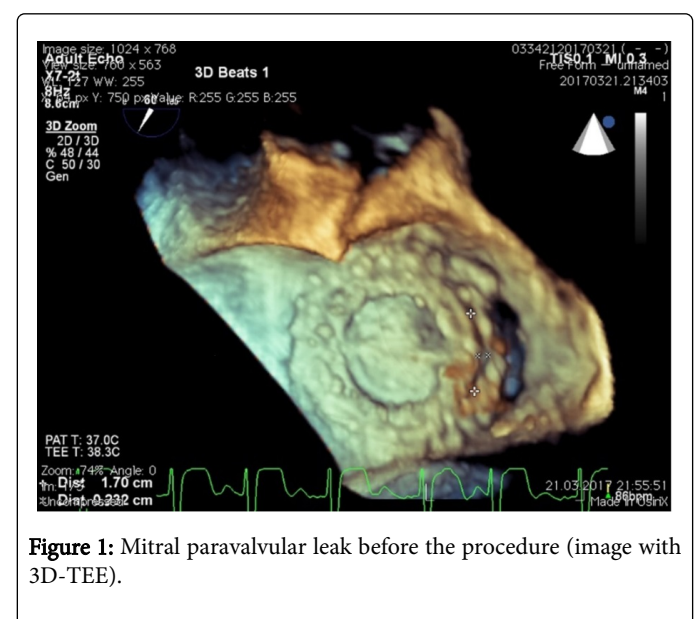
### Case

A 67 year old man, who had mitral and aortic valve replacement surgery 10 years ago admitted to our outpatient clinic with signs and symptoms of heart failure. He had three valvular operations which the two of them had been performed for treatment of paravalvular leak. He had fatigue, exertional dyspnea and signs indicating low output state. He had performed 100 meters in 6-minute walk test on admission. His pro-BNP was 3150 pg/ml. He had signs indicating hemolysis. His hemoglobin concentration was 9.1 g/dL and lactate dehydrogenase level was 321 IU/L. On transthoracic echocardiography (TTE) an anteromedially located PVL was observed. The paravalvular leak was located anteromedially, at 2 to 4 o'clock position by 3D transesophageal echocardiography (Figure 1). Considering his previous operations which substantially increase his risk for a redo surgery, a percutaneous treatment for PVL had planned. As he had both aortic and mitral valvular prosthesis, transapical approach (TA) for PVL closure was chosen.

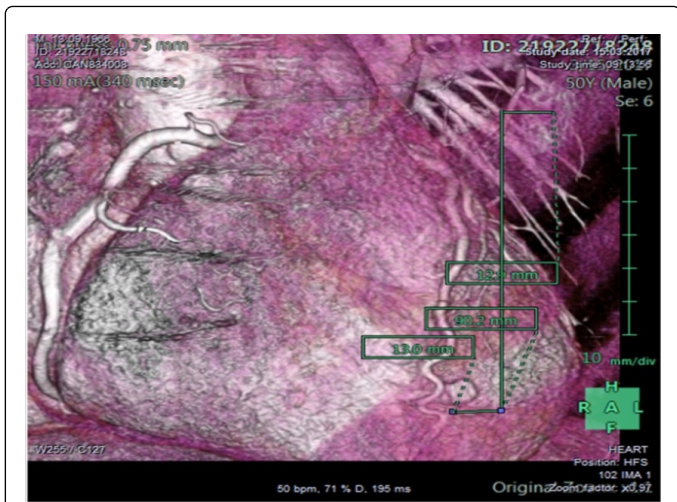
Upon decision to perform PVL via TA approach computer tomography angiography (CTA) performed to determine the appropriate access site. Left anterior descending artery was identified and a proper access site was determined 13 mm lateral to LAD, 12.9 mm inferior to second intercostal space (Figure 2). The proper angle was calculated from the access site to mitral PVL by CTA (Figure 3).

The skin above the pre-determined access site was marked. Before the puncture, a coronary angiogram was performed to determine exact localisation of LAD in order to prevent possible damage. A seldinger needle of 22 g size was used to puncture of LV. Upon receiving pulsatile flow at the tip, radiocontrast was injected through needle to ensure the

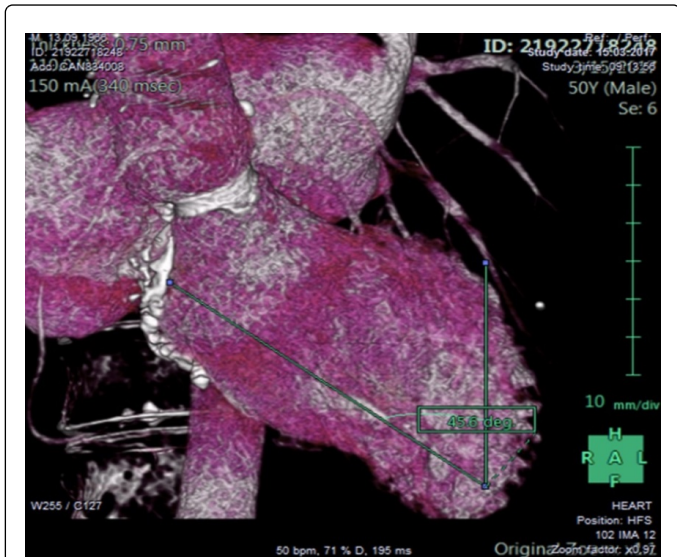position in LV. The sheath of 7F size and 25 mm length (Terumo, Japan) was introduced. After the access site was secured, heparin was administered. A 0.035" 260 mm length Radiofocus angled Terumo guidewire (Terumo, Japan) was advanced through anteromedially located PVL and the position of the wire confirmed in left atrium (Figure 4). The introducer sheath then advanced and positioned in the left atrium over the wire. The two Amplatzer Vascular Plug III (AVP III, St.Jude Medical) of 3 mm width and 14 mm length (AVP III, 9 AVP -143) were advanced and placed through mitral PVL sequentially via 3D TEE and flouroscopy guidance (Figure 5). The PVL diminished to minimal and no interaction with valvular prosthesis was observed (Figure 6). After successfully closing the PVL, the exit through LV apex was closed with Amplatzer Duct Occluder II (ADO II, St. Jude Medical). The ADO II (ADO II, 9PDA-004) was advanced through sheath and the system pulled back until it resides on LV apex. Then the system completely pulled back and the ADO II left in LV puncture site (Figure 7). No pericardial effusion was observed and the patient discharged on third post-operative day uneventfully.



**Figure 1:** Mitral paravalvular leak before the procedure (image with 3D-TEE).



**Figure 2:** Left ventricular access site determination with computer tomography angiography (CTA).



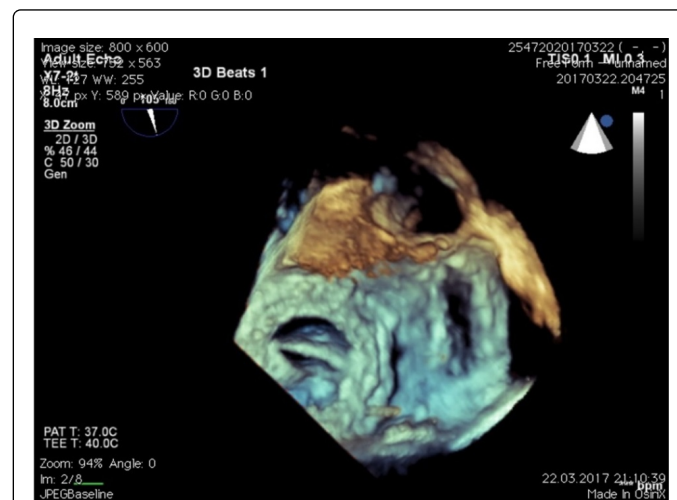
**Figure 3:** The angle between left ventricular access site and mitral paravalvular leak.

## Discussion

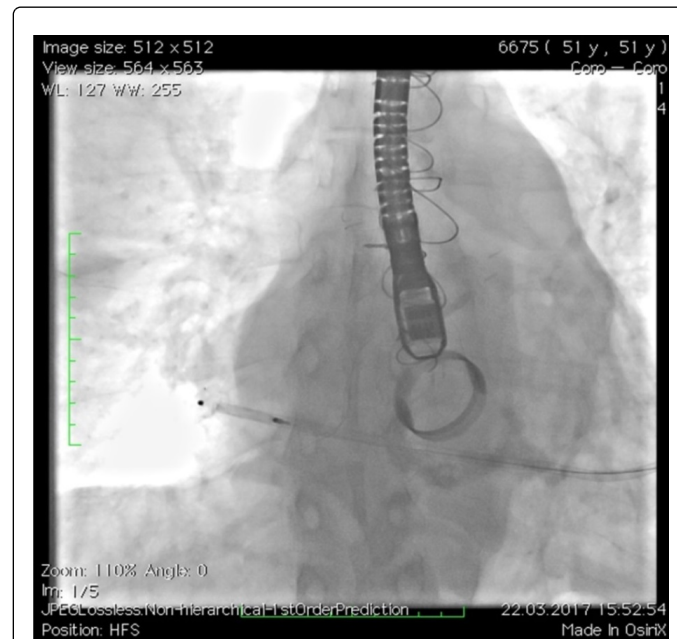
The reported incidence of PVLs range between 2% to 10% for aortic position and 7% to 17% for mitral position [1,2]. As PVL surgery has considerable risk for morbidity and mortality, a less invasive alternative have been developed. Hourihan performed the first reported transcatheter closure of PVL in 1992 with double umbrella device and since then the technique is considerably developed [3]. Percutaneous PVL closure has been shown to be safe and effective treatment in different series [4,5-7].

There are number of approaches for PVL closure including transeptal (TS) access, apical left ventricular (LV) access and retrograde femoral access. The choice of approach is mainly affected by the valve involved, location of PVL and local expertise. In the case

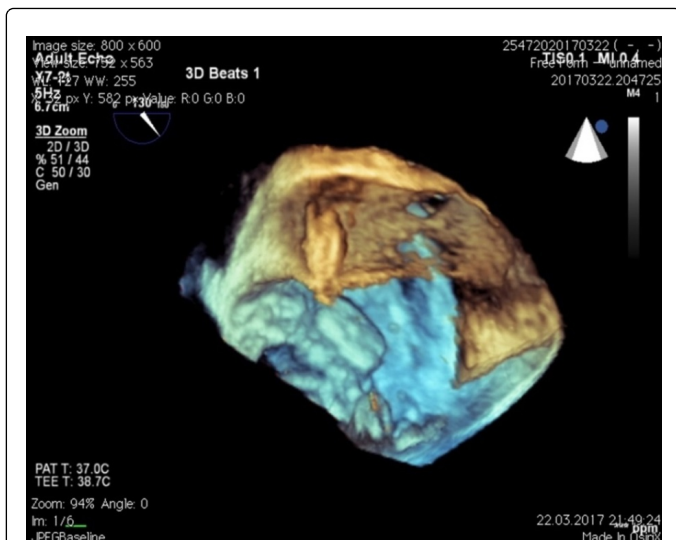
presented, presence of aortic valve prosthesis and anteromedial position of PVL led us to choose TA access. TA access can be provided by direct puncture or open surgical LV apical access via left anterolateral mini thoracotomy [8,9]. There is no direct comparison of open surgical and percutaneous TA access to date, so the decision is mainly dependent on experience of the operator. We choose to perform direct LV puncture as it is less invasive and traumatic, especially in this patient group whom require anticoagulation treatment. The LV puncture was confirmed with radiocontrast injection through the needle. A left ventriculogram could be used for patients who do not have aortic valvular prosthesis. In our case, the presence of aortic prosthesis disregards such an option.



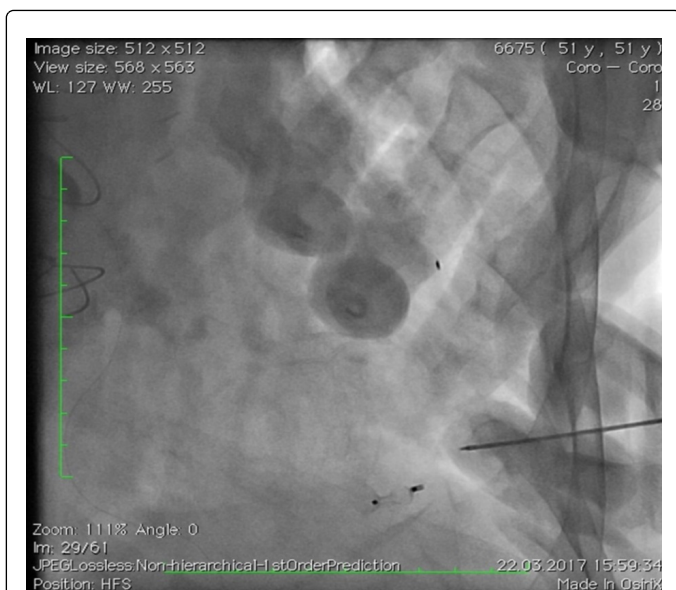
**Figure 4:** Terumo guidewire advanced through PVL.



**Figure 5:** Fluoroscopic image of catheter and Amplatzer Vascular Plug III advanced through PVL.



**Figure 6:** 3D TEE image of Two AVP III devices deployed.



**Figure 7:** Left ventricular puncture site successfully closed with Amplatzer Duct Occluder.

There is no specifically designed device or delivery system for PVL closure. We have chosen to use Amplatzer vascular plug III (AVP III, St. Jude Medical) which has an oblong shape and relatively small retention rims. The shape of AVP III provide advantage for closure of crescentic PVLs. It's feasibility and safety have been shown in clinical studies of transapical PVL closure [10,11].

Following percutaneous TA puncture, use of closure devices is recommended if the sheaths used are larger than 5F [12]. For smaller sheaths, the access site is generally occluded by LV myocardial motion. In accordance with previous reports we closed the puncture site with

an Amplatzer Duct Occluder II (ADO II, St. Jude Medical) as we had used a 7F sheath. Meticulous pre-procedure planning and safe exit from LV via using an occluder device enabled us to omit major complications of LV apical puncture such as laceration of coronary, pleural or intercostal vessels during access or hemothorax caused by bleeding from LV puncture site [12,13].

TA approach for percutaneous mitral PVL closure is associated with favorable outcomes and acceptable morbidity in patients with high surgical risk [8,9]. It also decreases procedure and fluoroscopy times, provides opportunity to directly cross mitral PVL defects. Although there are number of complications associated with procedure, careful patient selection and pre-procedural planning will improve the results.

## References

1. A Ionescu, Fraser AG, Butchart EG (2003) Prevalence and clinical significance of incidental paraprosthetic valvar regurgitation: a prospective study using transoesophageal echocardiography. *Heart* 89: 1316-1321.
2. Hammermeister K, Sethi GK, Henderson WG, Grover FL, Oprian C, et al. (2000) Outcomes 15 Years After Valve Replacement With a Mechanical Versus a Bioprosthetic Valve: Final Report of the Veterans Affairs Randomized Trial. *J Am Coll Cardiol* 36: 1152-1158.
3. Hourihan M, Perry SB, Mandell VS, Keane JF, Rome JJ, et al. (1992) Transcatheter umbrella closure of valvular and paravalvular leaks. *J Am Coll Cardiol* 20: 1371-1377.
4. Ruiz CE, Jelmin V, Kronzon I, Dudiy Y, Valle-Fernandez V, et al. (2011) Clinical Outcomes in Patients Undergoing Percutaneous Closure of Paraprosthetic Paravalvular Leaks. *J Am Coll Cardiol* 58: 2210-2217
5. Sorajja P, Cabalka AK, Hagler DJ, MD, Rihal CS (2011) Long-Term Follow-Up of Percutaneous Repair of Paravalvular Prosthetic Regurgitation. *J Am Coll Cardiol* 58: 2218-2224.
6. Krishnaswamy A, Kapadia SR, Tuzcu EM (2013) Percutaneous Paravalvular Leak Closure: Imaging, Techniques and Outcomes. *Circ J* 77: 19-27.
7. Klinger K, Eiros R, Isasti G, Einhorn B, Jelmin V, et al. (2013) Review of surgical prosthetic paravalvular leaks: diagnosis and catheter-based closure. *European Heart Journal* 34: 638-648.
8. Nijenhuis V, Swaans MJ, Post MC, Heijmen RH, de Kroon TL, et al. (2014) Open Transapical Approach to Transcatheter Paravalvular Leakage Closure A Preliminary Experience. *Circ Cardiovasc Interv* 7: 611-620.
9. Taramasso M, Maisano F, Latib A, Denti P, Guidotti A, et al. (2014) Conventional surgery and transcatheter closure via surgical transapical approach for paravalvular leak repair in high-risk patients: results from a single-centre experience. *Eur Heart J Cardiovasc Imaging* 15: 1161-1167.
10. Smolka G, Pysz P, Jasinski M, Gocoł R, Domaradzki W, et al. (2013) Transapical closure of mitral paravalvular leaks with use of amplatzer vascular plug III. *J Invasive Cardiol* 25: 497-501.
11. Cruz-Gonzalez I, Rama-Merchan JC, Arribas-Jimenez A, Rodriguez-Collado J, Martin-Moreiras J, et al. (2014) Paravalvular leak closure with the Amplatzer Vascular Plug III device: immediate and short-term results. *Rev Esp Cardiol (Engl Ed)* 67: 608-614.
12. Jelmin V, Dudiy Y, Einhorn BN, Kronzon I, Cohen HA, et al. (2011) Clinical Experience With Percutaneous Left Ventricular Transapical Access for Interventions in Structural Heart Defects, A Safe Access and Secure Exit. *JACC Cardiovasc Interv* 4: 868-874.
13. Pitta SR, Cabalka AK, Rihal CS (2010) Complications associated with left ventricular puncture. *Catheter Cardiovasc Interv* 76: 993-997.