

Tocilizumab and Regression of Rheumatoid Nodules in Patients with Rheumatoid Arthritis: 2 Case Report

Haider M Al Attia*

Internal Medicine and Rheumatology, Al Mazroui Medical Centre, Abu Dhabi, UAE

*Corresponding author: Haider M Al Attia, Consultant in Internal Medicine and Rheumatology, Al Mazroui Medical Centre, Abu Dhabi, UAE, Tel: 00971506137795; E-mail: haideralattia@hotmail.com

Received date: February 7, 2014; Accepted date: October 1, 2014; Published date: October 15, 2014

Copyright: © 2014 Attia HMA. This is an open-access article distributed under the terms of the Creative Commons Attribution License, which permits unrestricted use, distribution, and reproduction in any medium, provided the original author and source are credited.

Abstract

We report two cases of females with seropositive and deforming nodular rheumatoid arthritis. They responded well to TCZ therapy after failing to other anti RA therapeutics (DMARDs and biologics). The nodules disappeared following Tzc in both patients but they reappeared in one patient after 5 months of cessation of the TCZ.

Keywords: Rheumatoid Arthritis; Tocilizumab; Rheumatoid nodules; IL-6

Introduction

Rheumatoid nodules (RNs) grow as subcutaneous painless lumps over the bony prominences, close to affected joints, or they can be attached to tendons or fascia. Nodules may appear in other sites such as the vocal cords leading to hoarseness, lungs, heart and other internal organs. About 5% of RA patients may develop nodules in the first 2 years of onset, and the cumulative prevalence is about 25-35%. They are usually associated with severe form of RA and RF seropositive patients. Histologically, RNs are type-1-driven granulomata [1] and characterized by triple layered rheumatoid granuloma with central core of fibrinoid necrosis, a middle layer of palisading fibroblasts and histiocytes, and outer layer of granulation tissue [2,3]. RNs usually cause little in the way of problem however; in some cases they may become painful especially if the overlying skin breaks down. Symptoms nevertheless may develop if they involve some other internal organs [2-4].

Interleukin-6 on the other hand is known to invoke inflammation in RA via TNF-alpha and researchers turned their attention in recent years to the IL-6 in the search for novel treatment of RA. Tocilizumab

(TCZ) is a relatively new biologic that targets IL-6 receptors and is available for treatment of adults with RA. It has also shown to blunt joint damage and radiological progression of the disease [5]. However, despite the well established place of TCZ in RA, the literature is scanty in reporting its effect on the RNs. We were the first to report the disappearance of elbow nodules in a case of aggressive refractory RA nearly 2 years ago [6]. That coincided with another exciting report by other researchers on the regression of pulmonary nodules in a female with RA [7].

In this report we are presenting the response of another case of nodular disease along with an update on the earlier case while remaining on TCZ therapy.

Case 1

64 years old female with 37 year history of seropositive erosive rheumatoid arthritis. The patient became almost wheel-chair bound. She was diabetic too but non-smoker. In her country of origin she was treated with courses of methotrexate (MTX), hydroxychloroquine (PQL), salazopyrine (SSZ) and leflunomide (LEF) but never received any biologic treatment. Clinically, she had a flare of advanced deforming RA. Multiple nodules of hands, elbows (Figure 1) and the feet also were noticed.

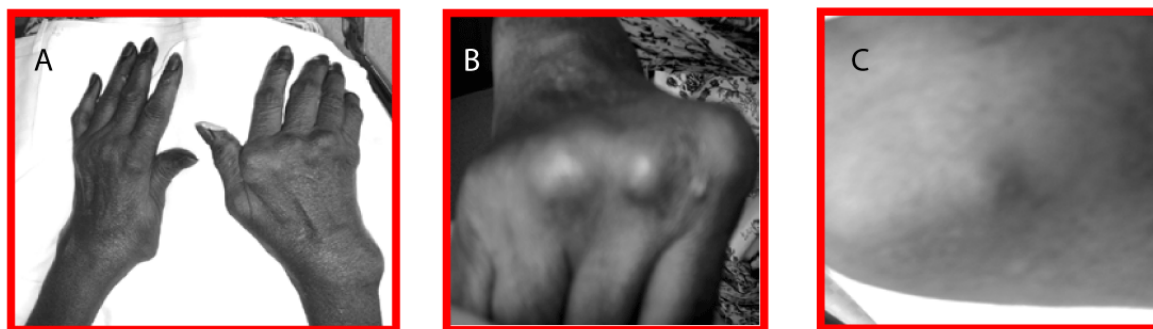


Figure 1: Multiple nodules of hands, elbows and feet.

ESR was 97 mm/1st hour, RF (IgG, Latex) 157(IU/ml), Anti CCP Abs: 738 U/ml (N<5), CRP 113 mg/L (N<6 mg/L). DAS 28 was 6.49 and HAQ score of 2.9. She made remarkable improvement on TCZ (of 8 mg/Kg iv monthly) with regression of nodules from early weeks of treatment and their disappearance after the 6th injection (Figure 2). By the time of her 11th injection the ESR dropped to 9 mm/h, CRP to 10.59 mg/L and DAS 28 reached 3.55. TCZ was the monotherapy for her RA. Both of RF and anti CCP Abs remained positive yet of lower levels than the initial ones.

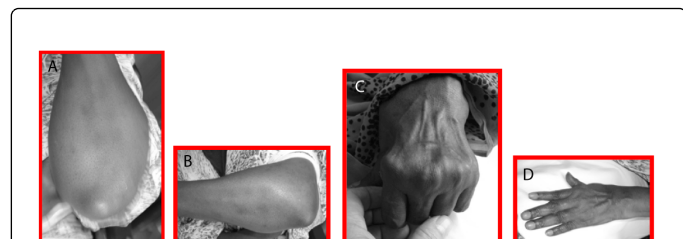

Figure 2: Improvement on TCZ with regression of nodules from early weeks of treatment and their disappearance after the 6th injection.

Unfortunately, she relapsed 5 months from cessation of TCZ because of her travel abroad. Upon return she was noticed to have a flare of RA which was accompanied by recurrence of the RNs mainly in the elbow (Figure 3). Her DAS 28 reached 6.13. She was recommenced in TCZ.

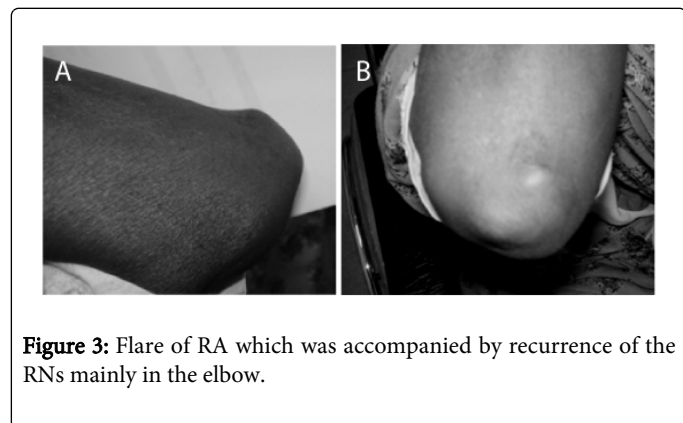


Figure 3: Flare of RA which was accompanied by recurrence of the RNs mainly in the elbow.

Case 2

This patient was reported earlier as being the first documented case of nodular refractory seropositive RA that had responded remarkably to monthly TCZ with a total disappearance of the olecranon nodules [6].

Regression of nodules had been witnessed in the early weeks of therapy and disappeared after the 4th injection. The patient had already failed to respond to courses of corticosteroids, MTX, LEF, Etanercept and Rituximab [5]. Now at the age of 42 and 13 year history of RA her condition remained stable following 30 injections of TCZ monotherapy without recurrence of nodules or disease flare. The latest DAS 28 was 2.52, ESR of 2 mm/h and negative CRP. Figure 4 shows the nodules pre (A) and post TCZ (B).

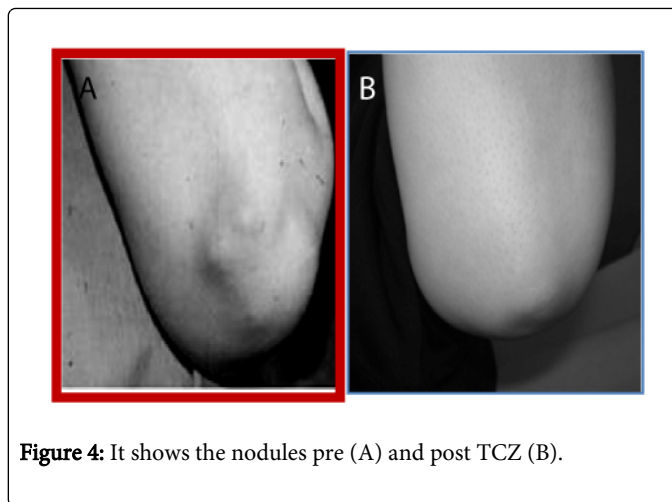


Figure 4: It shows the nodules pre (A) and post TCZ (B).

Discussion

The natural history of rheumatoid nodules is uncertain but they appear to modify with treatment of RA. Treatment of these nodules however, is rarely a priority however, surgical removal is often successful if they cause pain or pressure symptoms, and the injection of corticosteroids may help shrink the nodules [2,8]. Sometimes disease-modifying anti-rheumatic drugs (DMARDs) can also exert the same effect. Nodules disappearance has been reported with SSZ [9], and penicillamine [10]. Several reports indicated that MTX and LEF may have the disadvantage of tending to make the nodules worse [4,7,11]. Tumor necrosis factor (TNF) inhibitors do not have sustained or reliable effects on nodules in some reports [4,12,13] versus improvement reported by others [14]. The same may apply on B-cell depletion. In a very recent series report, regression of peripheral and pulmonary RNs observed in most patients treated with rituximab (RTX) [15]. However, that phenomenon of improvement was not observed in the patient reported by us earlier [6].

To the best of our knowledge, the current report represents the third documentation in the literature reporting a positive outcome of TCZ in RNs. Undoubtedly, the response to TCZ in these two cases reflect that the inhibition of IL-6 has a powerful and determinant effect on the regression of nodules. This is clearly, been supported by the improvement of RA disease as well. The recurrence of nodules in case 1 following the cessation of TZC is evidence as how important the role of IL-6 had been in these cases. Of note, the effect of TCZ on RNs was not an endpoint in previous large controlled and open-label studies [16,17].

It is becoming clear these days that, there is a degree of variability in the reported pathogenesis (cytokines profile) of analyzed nodules in a number of studies and this could possibly explain some of the varying outcome to the different treating agents. For instance IL-6 and IL-23 expression was identified in the majority of the analyzed nodules in one study [18] whereas in another work, the profile was different as the RNs commonly expressed TNF α (i.e., presence of IFN γ but not IL-2, and prominent expression of IL-1 β and TNF together with IL-12, IL-18, IL-15, and IL-10) [1]. Taking the latter results into consideration, the TNF α blockade should hypothetically at least be able to abolish these TNF dependent nodules. Yet, we are still witnessing conflicting clinical reports on the effect of anti TNF α

agents to the extent in some cases they have been associated with increased nodulosis.

The cases presented here make it plausible to hypothesize that TCZ had triggered the IL-6 in the joints and the nodules at the same degree. Such impressive outcome was very encouraging yet what remains is whether the outcome is sustainable or not. Only the constant follow up would have an answer to that. The recurrence of the RNs along with disease flare in the first case was alarming and reflected high degree of dependence on TCZ. However, until more reports are becoming available there are potential indications for this agent to be seriously considered in the peripheral and internal organs RNs too.

References

1. Hessian PA, Highton J, Kean A, Sun CK, Chin M (2003) Cytokine profile of the rheumatoid nodule suggests that it is a Th1 granuloma. *Arthritis Rheum* 48: 334-338.
2. García-Patos V (2007) Rheumatoid nodule. *Semin Cutan Med Surg* 26: 100-107.
3. Carmona L, González-Alvaro I, Balsa A, Angel Belmonte M, Tena X, et al. (2003) Rheumatoid arthritis in Spain: occurrence of extra-articular manifestations and estimates of disease severity. *Ann Rheum Dis* 62: 897-900.
4. Oldfield V, Dhillon S, Plosker GL (2009) Tocilizumab: a review of its use in the management of rheumatoid arthritis. *Drugs* 69: 609-632.
5. Emery P (2009) Tocilizumab-IL-6 inhibition for the treatment of rheumatoid arthritis. *Future Prescriber* 10: 5-9.
6. Al Attia HM, Abushawish M (2012) Treatment with tocilizumab leads to the disappearance of olecranon rheumatoid nodules. *Int J Dermatol* 51: 197-198.
7. Andres M, Vela P, Romera C (2012) Marked improvement of lung rheumatoid nodules after treatment with tocilizumab. *Rheumatology (Oxford)* 51: 1132-1134.
8. Baan H, Haagsma CJ, van de Laar MA (2006) Corticosteroid injections reduce size of rheumatoid nodules. *Clin Rheumatol* 25: 21-23.
9. Englert HJ, Hughes GR, Walport MJ (1987) Sulphasalazine and regression of rheumatoid nodules. *Ann Rheum Dis* 46: 244-245.
10. Dash S, Seibold JR, Tiku ML (1999) Successful treatment of methotrexate induced nodulosis with D-penicillamine. *J Rheumatol* 26: 1396-1399.
11. Braun MG, Van Rhee R, Becker-Capeller D (2004). Development and/or increase of rheumatoid nodules in rheumatoid arthritis patients following leflunomide therapy. *Rheumatology* 63: 84-7.
12. Kekow J, Welte T, Kellner U, Pap T (2002) Development of rheumatoid nodules during anti-tumor necrosis factor alpha therapy with etanercept. *Arthritis Rheum* 46: 843-844.
13. Toussiroit E, Berthelot JM, Pertuiset E (2009) Pulmonary nodulosis and aseptic granulomatous lung disease occurring in patients with rheumatoid arthritis receiving tumor necrosis factor-alpha-blocking agent: a case series *J Rheumatol* 36: 2421-7.
14. Derot G, Marini-Portugal A, Maitre B, Claudepierre P (2009) Marked regression of pulmonary rheumatoid nodules under etanercept therapy. *J Rheumatol* 36: 437-439.
15. Braun MG, Wagener P (2013) [Regression of peripheral and pulmonary rheumatoid nodules under therapy with rituximab]. *Z Rheumatol* 72: 166-171.
16. Smolen JS, Beaulieu A, Rubbert-Roth A, Ramos-Remus C, Rovensky J, et al. (2008) Effect of interleukin-6 receptor inhibition with tocilizumab in patients with rheumatoid arthritis (OPTION study): a double-blind, placebo-controlled, randomised trial. *Lancet* 371: 987-997.
17. Bykerk VP, Ostör AJ, Alvaro-Gracia J, Pavelka K, Ivorra JA, et al. (2012) Tocilizumab in patients with active rheumatoid arthritis and inadequate responses to DMARDs and/or TNF inhibitors: a large, open-label study close to clinical practice. *Ann Rheum Dis* 71: 1950-1954.
18. Stamp LK, Easson A, Lehnigk U, Highton J, Hessian PA (2008) Different T cell subsets in the nodule and synovial membrane: absence of interleukin-17A in rheumatoid nodules. *Arthritis Rheum* 58: 1601-1608.

This article was originally published in a special issue, entitled:
"Atherosclerosis and Rheumatic Diseases", Edited by Ihsane hmamouchi