

Thyroid Hormone-Induced Seizures A Case Report and Review of Literature

Philip S^{1,2,*}, Kuan C C², Hsu M C² and Lue H C^{2,3}

¹Division of Pediatric Cardiology and Epilepsy, St. Gregorios Cardio-vascular center, Parumala, Kerala, India

²Department of Pediatrics, Min-Sheng General Hospital, Tao-Yuan, Taipei, Taiwan

³National Taiwan University and Saint Mary's Hospital Luodong, Taipei, Taiwan

Abstract

Thyroxine may induce seizures in patients of all ages, and has been reported in only few cases. Electroencephalogram, computerized tomography and other imaging techniques may be helpful in early diagnosis. The measurement of thyroid hormone levels might be justifiable if the cause of convulsion in a patient is not apparent. We report a case of hyperthyroidism presented with a generalized tonic clonic seizures in a 14-year-old female patient and also a review of diagnosis, management and outcomes of the reported series of seizures in thyrotoxicosis.

Keywords: Generalized tonic clonic seizures; Electroencephalogram; Thyrotoxicosis

Introduction

Thyrotoxicosis is commonly associated with neurological manifestations, and very rarely induces seizures reported. To our knowledge, only 19 cases, 14 adults (n=14) and 5 children were reported in the English literature [1-14]. The incidence remains however still not known. We report here in an additional patient with hyperthyroidism and goiter that developed generalized tonic clonic seizures.

Case Report

A 14-year-old girl was brought to our emergency department with a chief complaint of generalized tonic clonic seizures with upward gaze of eye balls. She had a bicycle accident about 9 months prior to the attack of seizures and underwent splenectomy because of splenic rupture and internal bleeding. There had been no history of head injury or of seizure disorder in the family. A goiter was found on admission and no other symptoms of thyrotoxicosis like proptosis, tremor, profuse sweating, and emotional liability, except palpitations or weight loss.

Physical examination on admission revealed a blood pressure 110/70, heart rate 82/minute, and respiratory rate 22/minute. There was a mild thyroid enlargement without exophthalmosis, tremor, tachycardia, diplopia or pretibial myxoedema. Thyroid function test results confirmed hyperthyroidism. T4- 24.7 (6-2 µg/dl), T3 525.4 (100-200 mg/ml), TSH 0.01 (0.17-4.5 IU). Anti-microsomal antibody, anti-thyroglobulin and Ab-TSH receptor were increased to 528 IU/ml, 1600 and 79%.and other laboratory examination results were given in (Table 1).

The Computerized Tomography (CT) and magnetic resonance imaging had no significant organic lesions. EEG revealed slow waves mainly at bifrontal and anterior temporal areas (Figure 1A). Thyroid scan showed hypoechoic areas and Graves's disease was impressed. Anti-thyroid drug methimazole (Tapazole) and antiepileptic agent (Carbamazepine) were started after investigations. No recurrence of seizures was observed on antithyroid drug alone and EEG showed normal on follow up (Figure 1B).

Discussion

Thyrotoxicosis (TT) is an extreme state of hyperthyroidism and although uncommon, it is an exceedingly serious complication usually occurring in association with Graves's disease but rarely in conjunction

with toxic multinodular goiter [15]. Though the seizures were reported as one of the common symptoms of acute hyperthyroidism [16], it is rather uncommon [17] incidence may vary from 1% to 9% [5].

Thyroxine can induce seizures. Sundram et al. [6] presented a case of petitmal status epileptics in a 17 year old mentally retarded female patient after treating with L-thyroxine for her hypothyroidism with the suggested possibility of thyroxine induced seizures in a structurally damaged brain, and also Obeid T et al. [18] reported another case of juvenile myoclonic epilepsy exacerbated with absence seizures by thyroxine treatment for hypothyroidism [18]. A 54-year-old woman had also developed a first episode of convulsive seizure after taking a small amount of levothyroxine sodium over a short period of time [5]. The effect of thyroxine in these patients suggested that thyroid

White cell count	8410/10 ³
Neutrophils	50.9%,
Lymphocytes	37.1%,
Monocytes	8.9%
Eosinophils	2.9%,
Platelets	322/10 ⁶
Sodium	138mEq/L,
Potassium	3.8 mEq/L,
Chloride	104 mEq/L,
GOT	34 U/L,
Creatinine	0.5 mg/dl.
T4	24.7 micro g/dl
T3	525.4 mg/ml
TSH	0.01 IU
Anti-microsomal antibody	528 IU/ml,
anti-thyroglobulin	1600
Ab-TSH receptor	79%.

Table 1: Laboratory Examination Results.

*Corresponding author: Saji Philip, Division of Pediatric Cardiology and Epilepsy, St. Gregorios Cardio-Vascular Center, Parumala, Mannar 689626, Kerala, India, Tel: +91-479-2310665; Fax: 91-479-233379; E-mail: tfcsaji@yahoo.co.in

Received May 28, 2012; Accepted July 20, 2012; Published July 23, 2012

Citation: Philip S, Kuan CC, Hsu MC, Lue HC (2012) Thyroid Hormone-Induced Seizures A Case Report and Review of Literature. *Pediat Therapeut* 2:129. doi:10.4172/2161-0665.1000129

Copyright: © 2012 Philip S, et al. This is an open-access article distributed under the terms of the Creative Commons Attribution License, which permits unrestricted use, distribution, and reproduction in any medium, provided the original author and source are credited.

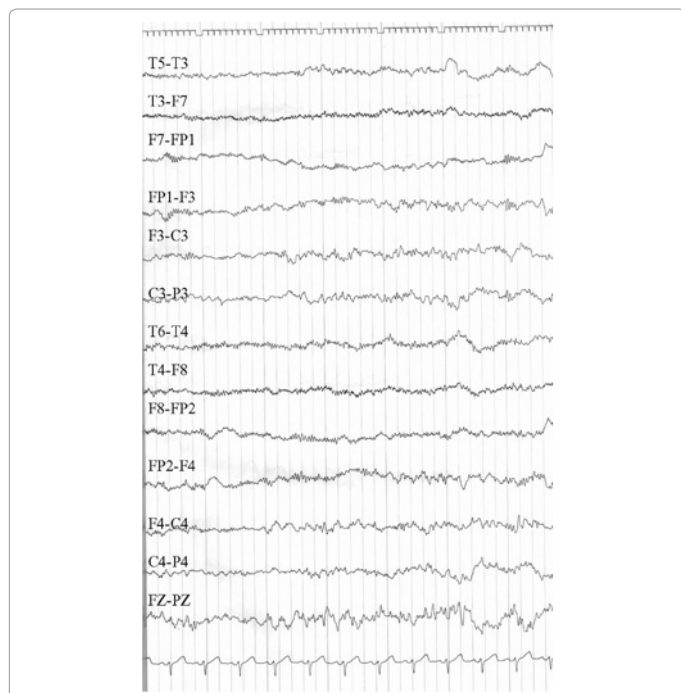


Figure 1A: showed bilateral slow waves in bifrontal areas with anterior temporal slowing at one day after admission.

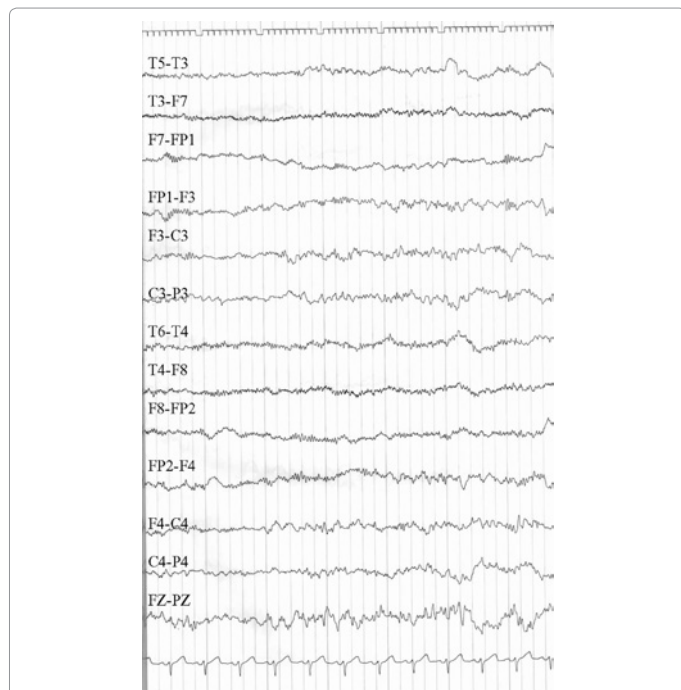


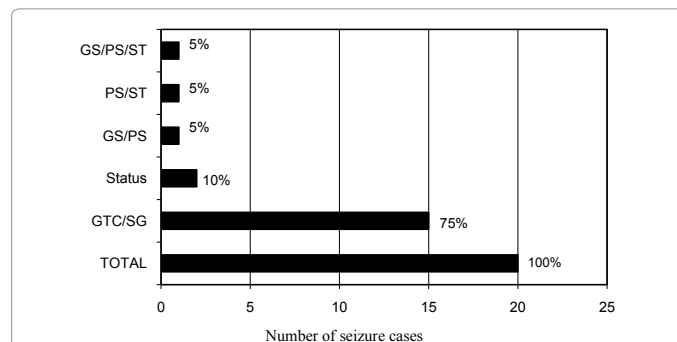
Figure 1B: showed normal pattern of EEG after two months follow up.

hormones may directly act on cerebral tissue and induce seizures by lowering the seizure threshold [19]. All cases of Seizures in Superior Sagittal Sinus (SSS) thrombosis were known cases of Hyperthyroidism. TT may produce hypercoagulability, venous stasis and subsequent development of SSS thrombosis, hemorrhages and seizures. Hence SSS thrombosis should also be considered for differential diagnosis of seizures in thyrotoxicosis [12,14] 75% cases (n=15/20) had presented with Generalized Tonic Clonic Seizures (GTC) in both adult and

pediatric age group (n=3/5). (Supplementary Table 2) shows type of seizures and EEG findings in reported cases of thyroid dysfunction. Seizures may vary from GTC 75% (n=15) including secondary generalization, and status 10% (n=2) or in combination (Figure 2).

A characteristic EEG pattern in patients with TT had been reported. Increased alpha rate, paroxysmal slow activities and high amplitude beta waves (fast activity) [2,19-21]. The excess of slow activity in temporal regions, along with fast activity of high amplitude in the frontal region in EEG is characteristic of hyperthyroidism [22]. Though the typical patterns described in hyperthyroidism by many authors, EEG in reported series of seizures in hyperthyroidism showed various patterns and mainly manifested as bilateral or unilateral diffuse slowing. EEG of our case showed bilateral slow waves mainly in bifrontal and anterior temporal areas which was similar to the reported cases of hyperthyroidism with seizures. Condon et al have investigated the EEG records of 27 cases of TT without seizure and 63% (n=17) of his patients had abnormal EEG and 7 cases had definite spike discharges [20]. Our observation from those studies found that EEG may not be positive in all cases of hyperthyroidism with seizures, and also positive EEGs in all cases of hyperthyroidism may not manifest clinical seizures. There were no significant differences in EEG between adult and pediatric age group. The seizure occurrence in male (n=7) to female (n=13) was 1:1.4 and no differences in the pattern of clinical seizures or EEG were observed between male and female group.

A correlation was found between the severity of hyperthyroidism and several EEG parameters. However, Zander et al. [22] study showed that after treatment the regression of EEG abnormalities were incomplete [22]. All the reported cases with seizures were showed abnormal (88%) and all positive EEGs were reverted to normal within 3-6 months of antithyroid treatment except one case, was not in euthyroid state and then follow up EEG was normal by increasing dose of antithyroid drug. Hence EEG may be taken as one of the guidelines for the thyroid treatment response in case of associated clinical seizures. If EEG is not reverted to normal, the risk of seizure recurrence may be high and thyroid function test should be repeated for to achieve euthyroid state. The reversibility of the phenomena suggests that neuronal changes are functional rather than organic in nature [3]. Hyperthyroidism was diagnosed by clinical examination of thyroid, laboratory data and thyroid scan. Among the reported cases, 55% (n=11) underwent CT scan examination and 27% (n=3) showed intracranial hemorrhages, proved as sagittal sinus thrombosis associated with TT. CT may be helpful to investigate the other causes of seizure disorders, especially cases presenting with focal signs and



GS: Generalised Seizures; SG: Secondary Generalization; PS: Partial seizures; ST: Status

Figure 2: Bar diagram for various seizure patterns occurring in patients presented with thyroid dysfunction.

also to rule out the possible uncommon association of superior sagittal sinus thrombosis in TT [12,14]. We also suggest that CT should be included in our routine investigation list especially in a comatose patient presenting with seizures where basic investigations proved to be hyperthyroidism.

The regimen used for treating TT was Propylthiouracil (PTU), lugols iodine, propranolol and dexamethasone with additional vitamin B complex in few cases, was successful in regaining consciousness in all cases during the acute phase and no mortality was reported. Various AEDs, either carbamazepine, or phenytoin, or sodium valproate and additional diazepam or clonazepam were used to treat seizures in the acute phase. In a study of thyroid function in patients who were taking carbamazepine and oxcarbamazepine showed that carbamazepine can lower serum thyroid hormones [23]. Antiepileptic drugs may be useful and justified during the initial treatment of seizures till you reach the diagnostic confirmation and then antithyroid drug alone will be helpful to prevent seizure recurrences except in proved SSS thrombosis where AED may be continued in view of hemorrhagic and thrombotic lesions. The mechanism of seizure induction is still obscure. Increased thyroxine and triiodothyronine levels influence the activity of sodium potassium adenosine-triphosphatase, leading to severely altered concentrations of sodium in cerebral cells, which can induce a lower threshold for seizures at least in animals [24-26]. The administration of thyroxine in the rat decreases the animal's threshold for pentylenetetrazol (Metrazol) or electro shock-induced seizures; whereas thyroidectomy, or administration of propylthiouracil produces reverse effect [27].

Conclusion

Hyper function of the thyroid may induce seizures, even without much clinical manifestations of thyrotoxicosis. From the review of literatures, we suggest that the measurement of thyroid hormone levels might be justifiable if the cause of convulsion in a patient is not apparent. Antithyroid drug alone will be helpful to prevent seizures once the diagnosis is established. And cases presenting with encephalopathy with focal neurological deficit, possible association of SSS thrombosis should be considered.

References

1. Skanse B, Nyman GE (1956) Thyrotoxicosis as a cause of cerebral dysrhythmia and convulsive seizures. *Acta Endocrinol (Copenh)* 22: 246-263.
2. Chapman EM, Maloof FB (1956) Bizarre clinical manifestations of hyperthyroidism. *N Engl J Med* 254: 1-5.
3. Wohl MG, Shuman CR (1957) Atypical syndromes in hyperthyroidism. *Ann Intern Med* 46: 857-867.
4. Korczyn AD, Bechar M (1976) Convulsive fits in thyrotoxicosis. *Epilepsia* 17: 33-34.
5. Jabbari B, Huott AD (1980) Seizures in thyrotoxicosis. *Epilepsia* 21: 91-96.
6. Sundaram MB, Hill A, Lowry N (1985) Thyroxine-induced petit mal status epilepticus. *Neurology* 35: 1792-1793.
7. Aiello DP, DuPlessis AJ, Pattishall EG 3rd, Kulin HE (1989) Thyroid storm. Presenting with coma and seizures. In a 3-year-old girl. *Clin Pediatr (Phila)* 28: 571-574.
8. Primavera A, Brusa G, Novello P (1990) Thyrotoxic encephalopathy and recurrent seizures. *Eur Neurol* 30: 186-188.
9. Safe AF, Griffiths KD, Maxwell RT (1990) Thyrotoxic crisis presenting as status epilepticus. *Postgrad Med J* 66: 150-152.
10. Lin CS, Yiin KT, Lin WH, Huang SY (1992) Thyrotoxicosis accompanied with periodic seizure attacks a case report and review of literature. *Zhonghua Yi Xue Za Zhi (Taipei)* 50: 335-337.
11. Radetti G, Dordi B, Mengarda G, Biscaldi I, Larizza D, et al. (1993) Thyrotoxicosis presenting with seizures and coma in two children. *Am J Dis Child* 147: 925-927.
12. Siebert CE, Smelt AH, de Bruin TW (1995) Superior sagittal sinus thrombosis and thyrotoxicosis. Possible association in two cases. *Stroke* 26: 496-497.
13. Li Voon Chong JS, Lecky BR, Macfarlane IA (2000) Recurrent encephalopathy and generalised seizures associated with relapses of thyrotoxicosis. *Int J Clin Pract* 54: 621-622.
14. Ra CS, Lui CC, Liang CL, Chen HJ, Kuo YL, et al. (2001) Superior sagittal sinus thrombosis induced by thyrotoxicosis. Case report. *J Neurosurg* 94: 130-132.
15. Mackin JF, Canary JJ, Pittman CS (1974) Thyroid storm and its management. *N Engl J Med* 291: 1396-1398.
16. Ingbar HI. Thyroid storm or thyroid crisis (1978) In: SC Werner and SH Ingbar (Eds), *The Thyroid* Harper and Row, New York, p 801.
17. Smith DL, Looney TJ (1983) Seizures secondary to thyrotoxicosis and high-dosage propranolol therapy. *Arch Neurol* 40: 457-458.
18. Obeid T, Awada A, al Rajeh S, Chaballout A (1996) Thyroxine exacerbates absence seizures in juvenile myoclonic epilepsy. *Neurology* 47: 605-606.
19. Wilson WP, Johnson JE (1964). Thyroid hormone and brain function. I. The EEG in hyperthyroidism with observations on the effect of age, sex, and reserpine in the production of abnormalities. *Electroencephalogr Clin Neurophysiol* 16: 321-328.
20. Condon JV, Becka DR, Gibbs FA (1954) Electroencephalographic abnormalities in hyperthyroidism. *J clin Endocrinolmetab* 14: 1511-1518.
21. Gibbs FA, Gibbs EL (1941) *Atlas of electroencephalography*. Vol 1. Addison-Wesley press, inc., Cambridge, Mass.
22. Zander Olsen P, Stoier M, Siersbaek-Nielsen K, Molholm Hansen J, Scholer M, et al. (1972) Electroencephalographic findings in hyperthyroidism. *Electroencephalogr Clin Neurophysiol* 32: 171-177.
23. Isojärvi JI, Turkka J, Pakarinen AJ, Kotila M, Rättyä J, et al. (2001) Thyroid function in men taking carbamazepine, oxcarbazepine, or valproate for epilepsy. *Epilepsia* 42: 930-934.
24. Atterwill CK, Kingsbury AE, Balázs R (1983) Effect of thyroid hormone on neural development in vitro. *Monogr Neural Sci* 9: 50-61.
25. Timiras PS, Woodbury DM, Ag SL (1955) Effect of thyroxine and triiodothyronine on brain function and electrolyte distribution in intact and adrenalectomized rats. *J Pharmacol Exp Ther* 115: 154-171.
26. Woodbury DM, Hurley RE, Lewis NG, McArthur MW, Copland WW, et al. (1952) Effect of thyroxin, thyroidectomy and 6-n-propyl-2-thiouracil on brain function. *J Pharmacol Exp Ther* 106: 331-340.
27. Robins J. Thyroid storm. In: Krieger DT & Bardin CW. (eds) (1985) *Current Therapy in endocrinology and metabolism*. BC Decker Inc, Philadelphia 59-61.