

The Use of Hyaluronidase to Treat the Excess of Cross-Linked Hyaluronic Acid Following Aesthetic Medicine Procedures: A Practical Point of View

Evgenyia Ranneva*

Dermatologist, Skin Tech Pharma Group, Castelló d'Empúries, Girona, Spain

*Corresponding author: Evgenyia Ranneva, Dermatologist, Skin Tech Pharma Group, 17486 Castelló d'Empúries, Girona Spain, Tel: 699018934; E-mail: drranneva@clinicahera.es

Received date: April 03, 2017; Accepted date: August 01, 2017; Published date: August 08, 2017

Copyright: © 2017 Ranneva E. This is an open-access article distributed under the terms of the Creative Commons Attribution License; which permits unrestricted use; distribution; and reproduction in any medium; provided the original author and source are credited.

Abstract

Polymers formed by hyaluronic acid are generally catalyzed by Hyaluronidase and the product contains oligomers. Hydrolysis of the bond present in between the N-acetyl-Dglucosamine and D-glucuronic acid is responsible for such chemical process. Huge literature support is present supporting the application of this process for reducing cellulitis fibrosis. In the recent times, potential granulomatous reactions are being treated through this process as well as aiding in dissolving excess hyaluronic acid filler. Implication of hyaluronidase includes simple jabbing of hyaluronidase enzyme prepared with sterile solution. Generally, the solution consist sterile lyophilized hyaluronidase preparation with sterile saline medium. After conducting the allergy testing direct injection can be given to the problem area for treatment. Assessment of allergy is mandatory as the enzyme hyaluronidase protein may invoke sensitization in the patient. The expected outcome is mostly rapid and definitive.

Introduction

Hyaluronic acid (HA) is a natural polymer constituting the major glycosaminoglycan present in the extracellular matrix of human tissues. It is found in almost all body fluids and tissues. Nevertheless around 50% of the total content of hyaluronic acid in human is found in the skin. Market success of hyaluronic acid as filler agent is due to its biocompatibility properties and the fact that is very simple to inject, which makes it the safest filler available. Since the organism of linear hyaluronic acid can be easily degraded by enzymes, such as hyaluronidase and free radicals, residence time of the organism of linear hyaluronic acids is relevantly shorter. Moreover linear hyaluronic acid has low mechanical strength, therefore the linear hyaluronic acid present a limited number of applications. Manufacturers of hyaluronic filler have developed a modified hyaluronic acid prolonging the life of hyaluronic acid and increasing its mechanical properties in tissue by chemical cross-linking of the hyaluronic acid chains. Therefore, the cross-linked hyaluronic acid is most preferably used to treat facial wrinkles and folds, augment the lips, and for volumisation in the face, hands and body.

Cross-linked hyaluronic acid application should follow precautionary measures as several side-effects such as granuloma, over-correction and different types of infection has been observed. Other rare observations include local necrosis due to the vascular compression and lung embolism when the vaginal route of administration is selected. Even though these reports of side-effects are documented, more or less they are not common and thus allowing the comparatively safe use of cross-linked hyaluronic acid.

Nevertheless, physicians should always be aware and able to treat adverse events complications that may occur due to excess of injections or inappropriate anatomic injection. To date the only way of treating such adverse events is by using hyaluronidase.

Hyaluronidase specifically plays a role in polymer degradation for hyaluronic acid. This natural enzyme is important in diminishing

fibrosis and often in reducing the symptoms of inflammation. Alongside, the same enzyme is specifically involved in spermatozoids penetration as well as maintaining the balance of hyaluronic acid content in the body. On the contrary, hyaluronidase is utilized by some cancer cells for tissue penetration. Few animals use this enzyme along with their venoms to better diffusion of the toxins. As part of the process, degraded hyaluronic acid polymer, which is turning into oligomers, can survive the immune system as they no longer considered as foreign bodies similar to the precursor protein.

The activity of the enzyme is very specific, hydrolyzing the links between N-acetyl-D-glucosamine and D-glucuronic acid. In aesthetic medicine it is used in cases of over-correction, fibrosis, granuloma, and also for reducing the risk of an eventual vascular compression and or occlusion, which could lead to skin necrosis (Figure 1).

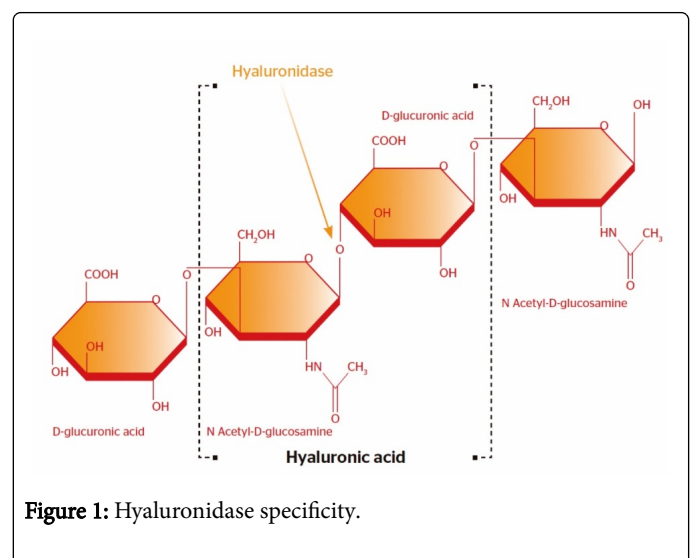


Figure 1: Hyaluronidase specificity.

Expectation is quite less related to benefit of injecting hyaluronidase with relation to injecting or reducing immune response due to other molecules such as silicone, collagen and polylactic acid. At present, Hyaluronidase is applied in lyophilized form of 1500 IU properly combined with sterile saline.

Patients' examples in the present article were treated with Desinfiltral a hyaluronidase sold by skin tech pharma group as described by other physicians [1-4].

How to use hyaluronidase?

Records suggest that more than a decade Hyaluronidase is being used. The lead author of this article is pioneer person in applying the same towards reducing cellulitis fibrosis. Anaesthesia associated application is widely accepted for quick penetration to the targeted tissues, thus immensely aiding in local anaesthesia based procedure. As mentioned earlier, records on allergic reactions or sensitivity due to the application of hyaluronidase is sporadic and most of the reports are related to the ophthalmic surgery, especially in relation to the application of retrobulbar or peribulbar anaesthesia. There is a report of anaphylactic shock in a case of epidurally administration of hyaluronidase [5]. It has been observed that allergy development occurs due to the subsequent injection of Hyaluronidase where patients have already taken one dose earlier. This allows developing and expressing sensitivity during succeeding injections. Thus, considering the possible allergic conditions, allergic test is necessary. The allergic reactions are either type I or type IV hypersensitivity reactions, where onset of allergic response may occur immediately (anaphylactic shock), may take some hours or intermediate time period or make have a delayed response which may take from few days to weeks to express the response and associated symptoms. The type I immediately reaction is symptomized by rash, itching, oedema, respiratory distress, local pains, nausea, hypotension and vomiting. Immediate medical attention is mandatory in such situation. Anaphylactic shock and similar other immediate reactions including respiratory distress and urticaria is observed which resulted followed by intravascular injection and reported as part of the chemotherapy applied for cancer treatment. Administration of corticoid along with antihistamine and adrenaline has aided in reducing the clinical symptoms of the allergic reactions. Pressor agents should be used to treat the low blood pressure on an urgent basis whenever required.

After repeated subcutaneous injection, the occurrence of a transitory delayed or intermediate (24 hours) reaction is not uncommon and takes the appearance of large, reddish, swollen and itchy macules that disappear after a few days without any treatment. Topical corticoid cream can also be used during the active period of allergic reaction. Furthermore, hyaluronidase injections have to be entirely avoided in such cases.

Intradermal tests are more sensitive than prick tests and are important to gauge a potential allergy to hyaluronidase. Prick tests and blood immunoglobulin E (IgE) levels are not always sufficient to predict an allergic reaction. Performing this test is quite simple: 1500 IU of hyaluronidase are diluted in 8-10 ml saline solution, with each ml containing up to 150 iu. Then, 0.1 ml of this dilution is injected subcutaneously to the forearm. The patient is kept in the clinic for an average of 60 minutes. Any reaction (e.g. itching, swelling, redness) at the injection point signifies that the patient should not receive treatment. A subcutaneous test is recommended for all patients prior to the injection of hyaluronidase.

Granuloma

Being a natural polymer with sequential and structural similarity as of the oligomers, hyaluronic acid can deceive the immune system and can be recognized as a natural part of the human body. Formation of the granuloma or other allergic reactions occurs due to the modification of the original protein, cross-linking of the side chains or contamination of the actual product during purification. These reactions may appear even after years of the treatment taken. The inflammation caused for this reason can leave a mark on the patient as calor, rubor, dolor, tumour which may sustain long. Often granuloma may require separate surgical treatment or long time for natural healing. Natural hyaluronidase, majorly accumulated in the dermis, may not be able to act on the hyaluronic acid as it is considered as foreign body; therefore, the product requires elimination through other immune process such as inflammatory reaction and engulfment through phage cells.

In the particular case of granuloma, a reddish swollen tumour on the site of injection of hyaluronic acid is secondary to an immune reaction against the polymer. The patient in Figure 2 received a cross-linked hyaluronic acid injection to the malar area a few months previously, and without any problem. A strong inflammatory reaction associated with a local granulomatous reaction appeared a few days after a thermogenic radiofrequency treatment. As visible in Figures 2 and 3, the whole area was swollen and the entry points of the previous implant appeared swollen and red. The patient was treated with three careful successive injections of low of ovine hyaluronidase, with a complete return to her normal appearance after the third injection. No side-effects were noted immediately or even some weeks after the injections.

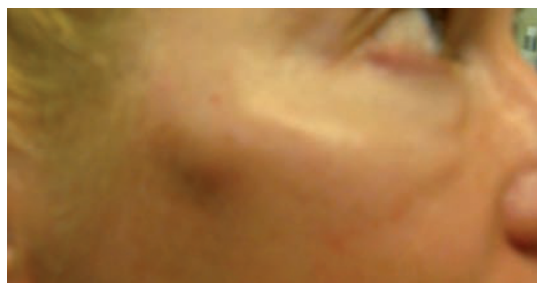


Figure 2: Granuloma of hyaluronic acid appeared after local thermogenic treatment.

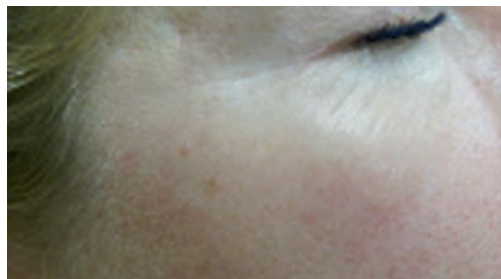

Figure 3: Result after treatment with three injections of low-dose ovine hyaluronidase.

Vascular compression and occlusion and the risk of necrosis

Hyaluronidase, by quickly breaking down the hyaluronic acid polymer, is able to reduce the risk of skin necrosis secondary to vascular compression if injected early, according to the medical literature [6-8]. Unfortunately, injection after 24 hours has been shown to be rather inefficient. Kim et al. [6] experimented using intra-arterial injection of hyaluronic acid in a rabbit ear, followed by an injection of hyaluronidase both 4 and 24 hours later. A late injection did not reduce the size of necrosis, while an earlier injection significantly reduced the size of skin necrosis. Hyaluronidase should therefore be immediately injected in cases of symptoms suggesting vascular compression or occlusion.

Cross-linked hyaluronic acid excess in the pre orbital area

The injection of hyaluronidase fortunately erases any cross-linked hyaluronic acid very quickly, but the speed will generally depend on the strength of the cross-linking. In these cases, the delay between the injection of hyaluronic acid and hyaluronidase is not relevant even when injected years later, hyaluronidase is able to cut the polymer. Reports show that hyaluronidase is able to dissolve hyaluronic acid injections in the periorbital area, even 5 years after the original injection. Again, intradermal testing should be carried out prior to injection. The task is to evaluate the volume and concentration of hyaluronidase to be injected in order to dissolve the excess only, without dissolving every hyaluronic acid molecule outside the injection area. There is no known consensus on this point, but it is known that some hyaluronic acids are more resisting to hyaluronidase than others. Hyaluronic acid excesses can occur after superficial injections (mesotherapy-like injections) of cross-linked hyaluronic acid (Figure 4). In such cases, one injection of one drop of hyaluronidase (1500 ui diluted in 4 ml saline solution), directly inside the tumefaction induced by the hyaluronic acid, can quickly resolve the problem, no matter what the delay is between hyaluronic and hyaluronidase injections. Hyaluronic excesses usually occur after injections to periorbital wrinkles or correction to under-eye circles, giving the puffy eye appearance seen in Figures 5 and 6. In the case of Figure 7, a cross-linked hyaluronic acid had been injected into the under-eye circles 2 years previously. The patient was informed that the hyaluronic acid had no tendency to disappear and of any surgical possibility of erasing the puffiness to the lower eyelids. Injection of hyaluronidase was therefore decided on, using an ovine lyophilised hyaluronidase, with a dilution of 4 ml saline solution for 1500 iu. After an allergy test showing a lack of immediate reactivity in the patient, three injection points of 0.1 ml each were carried out on each side. As the product is presented in a 1 ml syringe, with a 32 G needle, retro-injections should be performed directly inside the area showing the excess of hyaluronic acid. Injections here should be quite deep, as hyaluronic injections to this area are usually performed close to the bone. No side-effects, except transitory ecchymoses and local oedema, should be expected in normal conditions.

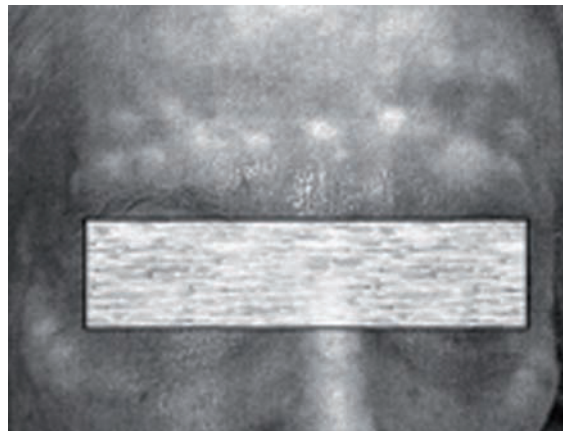


Figure 4: Intra-dermal injections of cross-linked hyaluronic acid.

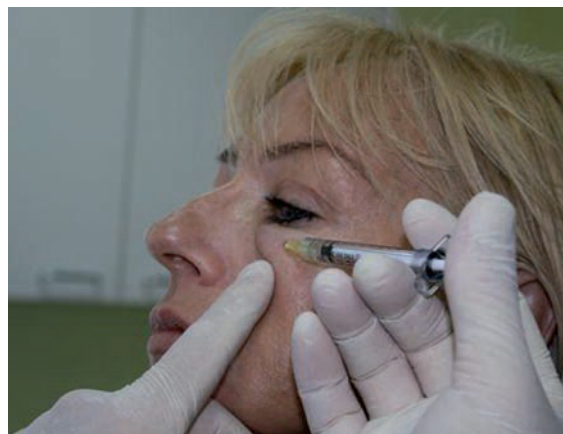

Figure 5: Intralesional injections of hyaluronidase.

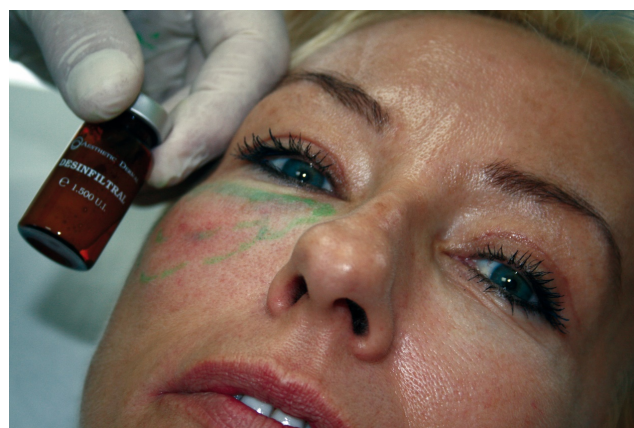

Figure 6: Periorbital wrinkles or correction to under-eye circles, giving the puffy eye appearance due to excessive Hyaluronic injection.

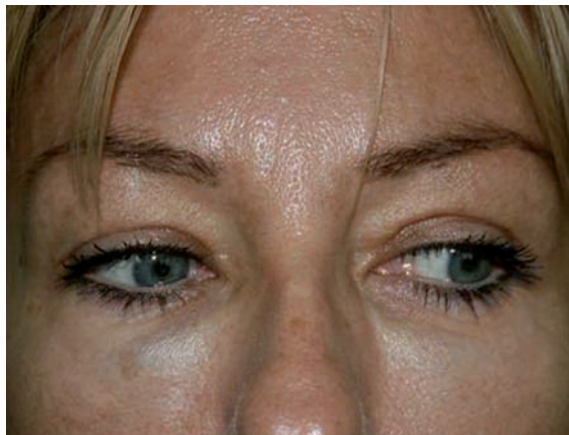

Figure 7: Puffy eyes as a result of hyaluronic acid excess.

The result of the injection began to be visible after 1 hour, when the patient was allowed to leave the clinic. Figure 8 shows the definitive result after day 3 — a complete disappearance of injected hyaluronic acid and a return to the original state with wrinkles and under-eye circles. A new injection of hyaluronic acid was carried out 2 weeks after the hyaluronidase treatment in order to fill this area without excess. No problems were experienced as a result of the corrective injection.



Figure 8: Result following correction with hyaluronidase.

Many cases of crosslinked hyaluronic acid excesses have also been witnessed in lip augmentation. The authors have only had one experience of general hyaluronic acid excess in this area, which was sent to the clinic by a colleague. The injection of hyaluronidase allowed for the correction of the problem over a few days, and without side-effects.

Tyndall effect

Superficial injections of hyaluronic acid can give the skin a different colour around the entire injection area compared with normal colouring. The skin may appear blueish, but in this case the resulting colour was different (Figure 9). Cross-linked hyaluronic acid had been injected a few months previously and the patient, even if happy to see the disappearance of circles around the eyes, wanted the change in colour to be removed. Hyaluronidase was injected, very superficially, in order to place the product exactly inside the non-accepted coat of hyaluronic acid. Hyaluronidase was diluted in 4 ml saline solution (precise number of units) and, after an intradermal allergy test, 0.2 ml were released in three retro-injection lines: 75 units of hyaluronidase were therefore injected on each side. Figure 10 shows the result 30 minutes after the superficial injection. A further correction can be carried out, but the delay for a new correction has not yet been defined. The authors prefer to wait for at least 1 week between hyaluronidase injection and a new hyaluronic acid implant.




Figure 9: Tyndall effect.

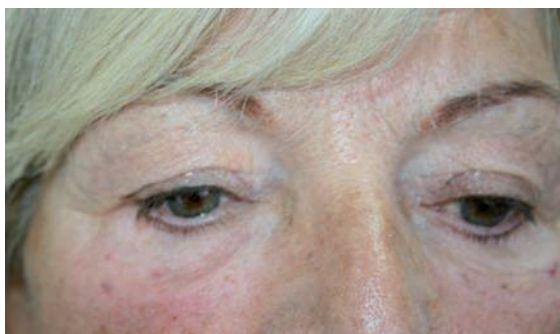

Figure 10: Correction of Tyndall effect following treatment with hyaluronidase.

Conclusion

Cross-linked hyaluronic acid fillers are actually widely used in aesthetic medicine. Hyaluronic acid is considered a very safe implant but nevertheless, can result in some side-effects. Hyaluronidase is a simple treatment that gives an immediate result, rubbing out excesses and even granuloma. It is also used for melting fibrotic areas. Hyaluronidase should therefore be included in our therapeutic armamentarium against the side-effects of hyaluronic acid. The main

concern for using hyaluronidase is a possible allergic reaction, making an intradermal test necessary before every treatment.

References

1. Lacoste C, Hersant B, Bosc R, Noel W, Meningaud JP (2016) Use of hyaluronidase to correct hyaluronic acid injections in aesthetic medicine. *Rev Stomatol Chir Maxillofac Chir Orale* 117: 96-100.
2. Andre P, Haneke E (2016) Nicolau syndrome due to hyaluronic acid injections. *J Cosmet Laser Ther* 18: 239-244.
3. Rzany B, Becker-Wegerich P, Bachmann F, Erdmann R, Wollina U (2009) Hyaluronidase in the correction of hyaluronic acid-based fillers: A review and a recommendation for use. *J Cosmet Dermatol* 8: 317-323.
4. Andre P, Levy PM (2007) Hyaluronidase offers an efficacious treatment for inaeesthetic hyaluronic acid overcorrection. *J Cosmet Dermatol* 6: 159-162.
5. Lee HK, Choi EJ, Lee PB, Nahm FS (2011) Anaphylactic shock caused by the epidurally- administered hyaluronidase. *Korean J Pain* 24: 221-225.
6. Kim DW, Yoon ES, Ji YH, Park SH, Lee BI, et al. (2011) Vascular complications of hyaluronic acid fillers and the role of hyaluronidase in management. *J Plast Reconstr Aesthet Surg* 64: 1590-1595.
7. Glaich AS, Cohen JL, Goldberh LH (2006) Injection necrosis of the glabella: Protocol for prevention and treatment after use of dermal fillers. *Dermatol Surg* 32: 276-281.
8. Hirsch RJ, Lupo M, Cohen JL, Duffy D (2007) Delayed presentation of impending necrosis following soft tissue augmentation with hyaluronic acid and successful management with hyaluronidase. *J Drugs Dermatol* 6: 325-328.