

The Distribution of Anti-NKG2A and NKG2C Positive Cells in Lichen Palnopilaris

Hideki Maejima*, Tomonori Taniguchi, Yasuyuki Amoh, Shiro Niiyama and Kensei Katsuoka

Department of Dermatology, Kitasato University School of Medicine 1-15-1 Kitasato, Sagami-hara, Kanagawa 228-8555, Japan

Abstract

Background: Lichen planopilaris (LPP) is a rare alopecia disorder. The histopathological features of LPP may resemble discoid lupus erythematosus (DLE). However, LPP usually lacks interfollicular inflammation, which differentiates it from DLE.

Methods: Skin biopsies were taken from subjects with early-stage LPP and DLE. The biopsies were evaluated for anti-CD56, anti-CD94, and anti-NKG2A/C/D-positive cells; the results were compared among two diseases.

Results: Anti-CD4, -CD8, and -CD94 positive cells mainly infiltrate the perifollicular dermis from the infundibulum to the hair isthmus in patients with LPP. Anti-CD56 and-NKG2C-positive cells were observed in the hair isthmus and bulge area (LPP) and in the infundibulum (DLE). In LPP, anti-NKG2A-positive cells were mostly seen in the infundibulum ($p < 0.05$), but there were no significant differences in the number of anti-NKG2A-positive cells between the infundibulum, hair isthmus, or bulge area in subjects with DLE.

Conclusions: Our results show differences in the localization of anti-NKG2A/C-positive cells between subjects with LPP and those with DLE. The inflammation in LPP initially originates in the hair isthmus and/or bulge followed by the interfollicular upper dermis. However, anti-NKG2A-positive cells prevent further enlargement of the inflammatory lesion in the interfollicular upper dermis of subjects with LPP.

Keywords: Lichen palnopilaris (LPP); Natural killer group 2A (NKG2A); NKG2C; Discoid lupus erythematosus (DLE); DNAX activating protein of 12 kDa (DAP12)

Abbreviation: AA: Alopecia Areata; DLE: Discoid Lupus Erythematosus; DAP12: DNAX Activating Protein of 12 kDa; LP: Lichen Planus; LPP: Lichen Palnopilaris; NKG: Natural Killer Group

Introduction

Alopecias are broadly subdivided into scarring and non-scarring variants [1]. A stereotypical example of the former is lichen planopilaris (LPP). LPP may resemble discoid lupus erythematosus (DLE) of the scalp both clinically and histopathologically. LPP most commonly presents with hyperkeratotic follicular papules and spines surrounded by a mild erythema (Figures 1a and 1b). Natural killer (NK) cells directly affect proinflammatory cytokines in alopecia areata (AA) [2] and LP [3] and the clinical and histopathological features of late-stage LPP make it difficult to discern from DLE. NKG2C and NKG2D are activating receptors of natural killer (NK) cells [4-7]. NKG2A receptor regulates the function of NK cell or cytotoxic T(NKT) cell [7]. NKG2 families have important roles in the pathology of lichen planus (LP), AA, rheumatoid arthritis, and systemic lupus erythematosus [2,3,8,9]. The CD94 receptor is located on NK cells and enables them to discriminate between healthy cells and pathogen-infected or tumor cells by binding to the major histocompatibility complex (MHC), class I [10]. Anti-CD56 positive cells are NK and NKT cells, which cause inflamed skin or activate CD8 cells that release perforin and granzyme in LP and AA [2,3]. We hypothesize NK or NKT cell may play important role in pathogenesis in LPP as well as LP or AA. Our aim is to clarify the immunohistochemical differences between LPP and DLE. We investigated the localization of anti-CD56 and -NKG2A/C/D-positive cells from subjects with LPP and compared the results with those from subjects with DLE.

Methods

Subjects and methods

Scalp skin specimens were obtained for LPP diagnosis from one male and five female samples (mean age 37.7 ± 19.9 , disease duration 1.96 ± 1.1 years) after receiving written informed consent. Cryosections (using only anti-NKG2D stain) were fixed in compound and paraffin sectioning (for used other kinds of stain) was performed

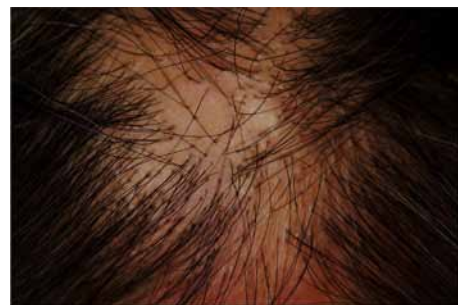


Figure 1a: Clinical appearance of lichen planopilaris.

*Corresponding author: Hideki Maejima, Department of Dermatology, Kitasato University School of Medicine, 1-15-1 Kitasato, Sagami-hara, Kanagawa, Japan, Tel: +81-427-78-8468; Fax: +81-427-78-8628; E-mail: hm4765@yahoo.co.jp

Received December 23, 2012; Accepted January 25, 2013; Published January 29, 2013

Citation: Maejima H, Taniguchi T, Amoh Y, Niiyama S, Katsuoka K (2013) The Distribution of Anti-NKG2A and NKG2C Positive Cells in Lichen Palnopilaris. J Clin Exp Dermatol Res 4: 167. doi:10.4172/2155-9554.1000167

Copyright: © 2013 Maejima H, et al. This is an open-access article distributed under the terms of the Creative Commons Attribution License, which permits unrestricted use, distribution, and reproduction in any medium, provided the original author and source are credited.

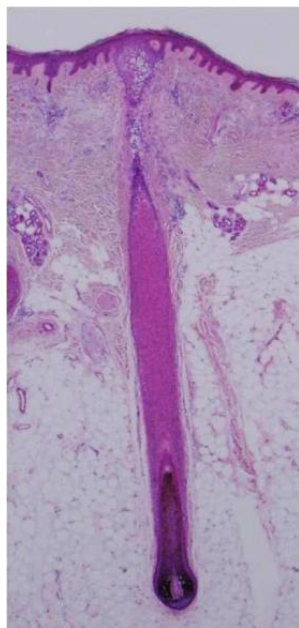


Figure 1b: Histopathologic features of lichen planopilaris Inflammatory cells are shown in the perifollicular dermis of the infundibulum and hair isthmus.

for immunohistochemistry and stored at -80°C . Lesional skin biopsies were also taken and stored (in the same manner as above) from five samples with DLE (two males and three females with scalp lesions, mean age 65.6 ± 13.8). Patients with DLE were chosen for control because LPP may resemble DLE of the scalp both clinically and histopathologically.

Immunohistochemistry

Skin tissues were routinely fixed in 10% formalin and then embedded in paraffin. Serial paraffin sections were deparaffinized, rehydrated, and incubated in methanol containing 0.3% H_2O_2 for 30 min to block endogenous peroxidase activity. After washing with distilled water, the sections were incubated with anti-CD3 ($\times 100$) (DAKO, Copenhagen, Denmark), anti-CD4 ($\times 100$) (DAKO), anti-CD8 ($\times 100$) (DAKO), anti-CD56 ($\times 10$) (NICHIREI, Tokyo, Japan), anti-CD94 ($\times 100$) (GeneTex, Irvine, CA, USA), anti-NKG2A ($\times 50$) (Abcam, Tokyo, Japan), anti-NKG2C ($\times 100$) (GeneTex), or anti-NKG2D ($\times 50$) (Abcam) overnight at 4°C , then washed with PBS and further incubated with ChemMate ENVISION kit/horseradish peroxidase-conjugated (Dako, Copenhagen, Denmark) for 30 min at room temperature. After washing, the sections were treated with 0.02% 3,3'-diamino-benzidine and 0.006% H_2O_2 in 50 mM Tris-HCl (pH 7.5) at room temperature, counterstained with hematoxylin, dehydrated, clarified, and mounted.

Statistical analysis

Paired and unpaired t-tests were used to evaluate the results of paired comparisons of two or three groups. When the paired comparison involved a large number of types, the repeated-measures method was used with the significance level set at $p < 0.05$.

Results

Numerous anti-CD3, -CD4, -CD8, and -CD94-positive T cells were observed in the perifollicular dermis of the infundibulum to the hair

isthmus in subjects with LPP and DLE (Figures 1c and 2a). Anti-CD94 and anti-NKG2D-positive cells infiltrated the infundibulum, hair isthmus, and bulge area but not the lower portion in the LPP and DLE samples (Table 1). Numerous anti-CD 56-positive cells also infiltrated the follicular epithelium and perifollicular dermis of the hair isthmus and bulge area in subjects with LPP (Figures 1d and 1e). There were



Figure 1c: Numerous anti-CD4-positive cells infiltrating the epithelium and the perifollicular dermis on the infundibulum, hair isthmus, and bulge area of LPP.

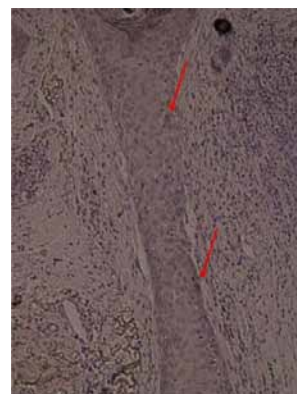


Figure 1d: Anti-CD56-positive cells are shown in the epithelium of the hair isthmus of LPP.

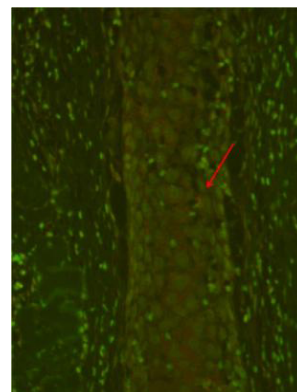


Figure 1e: Anti-CD56/NKG2C-positive cells shown in the epithelium of the hair isthmus of LPP (double stain, yellow: anti-CD56, red: anti-NKG2).

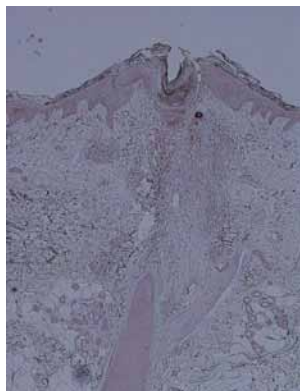


Figure 1f: Numerous anti-NKG2C-positive cells in the perifollicular dermis and epithelium of the infundibulum, but few positive cells are in the hair isthmus.

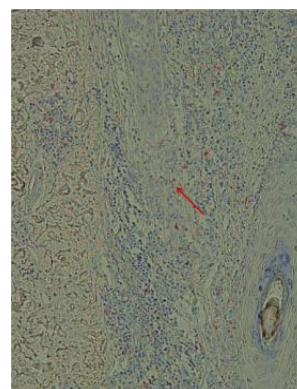


Figure 2b: Anti-CD56-positive cells are shown in the epithelium of the hair isthmus of DLE.



Figure 2a: Numerous anti-CD4-positive cells infiltrated the dermis, epidermis, and pilosebaceous apparatus with the exception of the lower portion of the hair of the DLE sample.

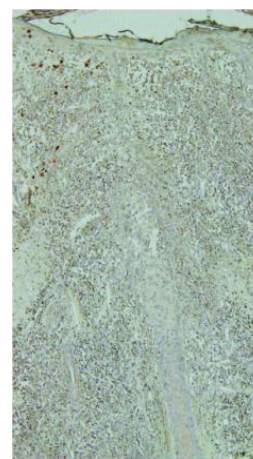

Figure 2c: A few diffuse, infiltrating anti-NKG2A-positive cells are shown in the dermis, perifollicular dermis, and epithelium of the infundibulum and hair isthmus of DLE.

significantly increased numbers of anti-CD56-positive cells in the hair isthmus compared to the lower portion of the LPP samples ($p < 0.05$), but there were no significant differences seen among the hair sites of the DLE samples (Figure 2b and Table 1).

Anti-NKG2C-positive cells were significantly increased on the hair isthmus and bulge compared to other areas in the LPP samples, but not the DLE samples (Figures 1e and Table 1). Anti-NKG2A-positive cells were observed in the infundibulum and the hair isthmus in the LPP samples but not the DLE samples (Figure 1f and 2c). The distributions of anti-NKG2A and NKG2C positive cells in patients with LLP were different from those cells in DLE patients (Table 1). We showed differences between patients in LPP and with patients in DLE.

Discussion

LPP is a rare alopecia that affects the hair isthmus and develops a scar that may not be distinguishable from DLE [1]. The onset of inflammation in LPP is still unclear. We investigated the expression of anti-CD4, -CD8, -CD56, -CD94, and -NKG2A/C/D inflammatory cells in biopsy samples from subjects with LPP and DLE. NKG2C, an activating NK-cell receptor of the C-type lectin superfamily, binds

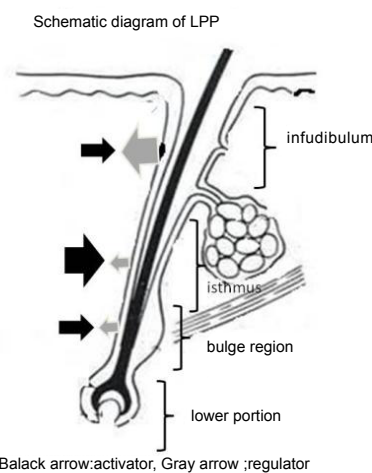


Figure 3: The balance of NKG families and anti-CD56-positive cells in the LPP samples.

	LLP				DLE			
	infundibulum	isthmus	bulge	lower position	infundibulum	isthmus	bulge	lower position
CD3	160±91.2	169±150	151±160	9.1±11.2	298±101	281±150	143±96.2	7.6±10.8
CD4	74.8±46.6	98.0±127	87.0±85.1	4.8±8.3	194±99.0	183±110	67.0±30.6	1.0±2.2
CD8	70.0±45.7	53.7±39.5	38.0±41.9	0.7±1.6	91.8±23.0	79.0±44.6	66.4±78.2	4.4±2.2
CD56	15.1±18.3	14.8±11.8	24.0±13.4	2.5±5.2	32.0±34.2	39.0±37.9	15.4±15.5	0.4±0.9
CD94	26.5±13.9	17.3±29.1	30.1±40.8	1.8±2.9	86.6±61.5	61.8±34.8	52.6±43.6	12.6±18.7
NKG2A (regulator)	62.5±15.9	30.3±37.8	8.8±10	0.8±2.0	112±40.8	124±85.3	60.2±45.4	1.0±2.3
NKG2C (activator)	10.3±28.7	143±111	36.5±31.3	11.5±24.9	122±18.6	119±86.4	59.1±49.2	4.6±5.3
NKG2D (activator)	82.8±55.9	48.5±38	57±114	0.5±1	128±12.6	80.3±14.4	42.3±18.3	2.5±1.7

*There were significant differences among each two groups (p < 0.05)

Table 1: A comparison of the number of infiltrating positive cells of anti-CD4, -CD8, -CD56, -CD94, -NKG2A, -NKG2C, and -NKG2D in the hair infundibulum, isthmus, bulge area, and lower portions of LPP and DLE.

to HLA-E and noncovalently associates with DAP12 [11]. NKG2D belongs to the C-type lectin-containing immunoreceptors with a tyrosine-based activation motif, shares little sequence homology with the NKG2 receptor family members, and does not appear to pair with CD94 [12]. NKG2A (regulator NK) resists NK as well as cytotoxic T cell-mediated lysis in vitro, while NKG2D functions as a co-stimulatory receptor in the adaptive immune system, or as both a primary recognition structure and a co-stimulatory receptor in the innate immune system [13].

Our results show that anti-CD4 (helper and inducer), -CD56 (NK and NKT), -NKG2C (activator NK), and -NKG2D (activator NKT)-positive cells in LPP samples are present in the follicular epithelium of infundibulum, isthmus, and bulge area. Therefore, inflammatory cells may destroy the sebaceous gland and hair stem cells, causing a scarring alopecia that may be similar to DLE [1,14,15] (Table 1). In LPP, anti-CD56/NKG2C-positive cells are shown in the isthmus epithelium in the same manner that anti-CD56/NKG2C cells are shown in the perifollicular dermis on the hair bulb of AA [2] and in the upper dermis on the marginal lesion of LP [3]. This suggests that the hair isthmus is possible to alternative inflammatory lesions of LPP (Figures 1d, 1e and 3). These findings may indicate a different histopathological and clinical mechanism for LPP which usually lacks inflammation in the interfollicular dermis, and differentiates it (histopathologically and

clinically) from DLE. However, inflammation enlarges the interface between the epidermis and the interfollicular upper dermis of late-stage LPP [1]. Therefore, why does inflammation not develop from the infundibulum to the interfollicular upper dermis in LPP? Our data reveals that anti-NKG2A (NK suppressor)-positive cells are present in the infundibulum of LPP but that those cells readily infiltrate from the perifollicular infundibulum to the bulge (except the lower portion) as well as the interfollicular dermis of DLE. These findings suggest that inflammation occurs in the hair isthmus and bulge area, but that anti-NKG2A-positive cells prevent the inflammatory cells from extending into the interfollicular upper dermis of LPP (Figure 3).

References

- Sellheyer K, Bergfeld WF (2006) Histopathological evaluation of alopecias. Am J Dermatopathol 28: 236-259.
- Ito T, Ito N, Saatoff M, Hashizume H, Fukamizu H, et al. (2008) Maintenance of hair follicle immune privilege is linked to prevention of NK cell attack. J Invest Dermatol 128: 1196-1206.
- Carbone T, Nasorri F, Pennino D, Donnarumma M, Garcovich S, et al. (2010) CD56 high CD16- NK cell involvement in cutaneous lichen planus. Eur J Dermatol 20: 724-730.
- Bauer S, Groh V, Wu J, Steinle A, Phillips JH, et al. (1999) Activation of NK cells and T cells by NKG2D, a receptor for stress-inducible MICA. Science 285: 727-729.

5. Wu J, Song Y, Bakker AB, Bauer S, Spies T, et al. (1999) An activating immunoreceptor complex formed by NKG2D and DAP10. *Science* 285: 730-732.
6. Pende D, Rivera P, Marcenaro S, Chang CC, Biassoni R, et al. (2002) Major histocompatibility complex class I -related chain A and UL16-binding protein expression on tumor cell lines of different histotypes: analysis of tumor susceptibility to NKG2D-dependent natural killer cell cytotoxicity. *Cancer Res* 62: 6178-6186.
7. Kronenberg M (2005) Toward an understanding of NKT cell biology: progress and paradoxes. *Annu Rev Immunol* 23: 877-900.
8. Walsh CE, Ryan EJ, O'Farrelly C, Golden-Mason L, FitzGerald O, et al. (2011) Differential Expression of NK Receptors CD94 and NKG2A by T Cells in Rheumatoid Arthritis Patients in Remission Compared to Active Disease. *PLoS One*.
9. Li WX, Pan HF, Hu JL, Wang CZ, Zhang N, et al. (2010) Assay of Tand NK-cell subsets and the expression of NKG2A and NKG2D in patients with new-onset systemic lupus erythematosus. *Clin Rheumatol* 29: 315-323.
10. López-Botet M, Bellón T (1996) Natural killer cell activation and inhibition by receptors for MHC class I. *Curr Opin Immunol* 11: 301-307.
11. Lanier LL, Corliss B, Wu J, Phillips JH (1998) Association of DAP12 with Activating CD94/NKG2C NK Cell Receptors. *Immunity* 8: 693-701.
12. Lazetic S, Chang C, Houchins JP, Lanier LL, Phillips JH (1996) Human natural killer cell receptors involved in MHC class I recognition are disulfide-linked heterodimers of CD94 and NKG2 subunits. *J Immunol* 157: 4741-4745.
13. Diefenbach A, Tomasello E, Lucas M, Jamieson AM, Hsia JK, et al. (2002) Selective associations with signaling proteins determine stimulatory versus costimulatory activity of NKG2D. *Nat Immunol* 3: 1142-1149.
14. Amoh Y, Maejima H, Niiyama S, Mii S, Hamada Y, et al. (2011) Hair follicle stem cell marker nestin expression in regenerating hair follicles of patients with alopecia areata. *Eur J Dermatol* 21: 209-212.
15. Sellheyer K, Atanaskova-Mesinkovska N, Nelson P, Bergfeld WF (2011) Differential expression of stem cell markers in lichen planopilaris and alopecia areata *Br J Dermatol* 165: 1143-1156.