

## Successful Endoscopic Laser De-roofing of Simple Prostatic Cyst Causing Bladder Outlet Obstruction-A Case Study

Ravisankar G Pillai\* and Ziad Al Naieb

Urologist, Royal Bahrain Hospital, Kingdom of Bahrain

### Abstract

The cysts of prostate are common but the information regarding classification, diagnosis and treatment of prostate cysts are rare in literature. We present the case report of a patient presented with severe lower urinary tract symptoms since 1 year. He was investigated using ultrasound scan to find that he has a simple prostatic cyst close to the bladder neck. The uroflowmetry and post void scan showed indirect evidence of bladder outlet obstruction. He had a cystoscopy and was treated with de-roofing of the prostatic cyst using 980 nm diode laser. He had tremendous symptomatic improvement and good recovery without catheterization. The ejaculatory functions were also preserved after the treatment. We also discuss about the available recent classification of cysts of prostate gland.

**Keywords:** Prostate; Cysts; Laser; Transurethral

**Abbreviations:** LUTS: Lower Urinary Tract Symptoms; IPSS: International Prostate Symptoms Score; QOL: Quality of Life; KUB: Kidney Ureter Bladder; TRUS: Trans Rectal UltraSound; CT: Computerized Tomography; MRI: Magnetic Resonance Imaging; DRE: Digital Rectal Examination

### Case Report

A 43 years old gentleman presented to our clinic with complaints of lower urinary tract symptoms (LUTS). The symptoms were straining to pass urine, dysuria, frequency, urgency discomfort in inguinal and abdominal region. Decrease in flow was severe that he strained to maintain a flow and had frequency every one hour. All his symptoms were present since 1 year but severe since 3 months. He is a known diabetic on regular oral hypoglycemic agents since 10 years. DRE was done in the clinic and was normal with normal prostate size and no tenderness. Urine analysis and culture came out to be normal. Serum total PSA test was 0.5 ng/ml. International Prostate Symptoms Score (IPSS) at presentation was 28 and Quality of Life score (QOL) was 6 at presentation.

Ultra Sound Scan KUB showed both kidneys are of average size, shape with regular outline, no evidence of masses, back pressure or cystic changes. Good cortico-medullary differentiation and adequate parenchymal thickness. No evidence of free or loculated intra-peritoneal or pelvic fluid collections. The maximum capacity of the urinary bladder was 500 ml with no masses or calculi. Post void residual urine was significant at 240 ml. Prostate was of average size (2.87×3.09×3.26-15.138 cc) (Figure 1) but with an anechoic oval lesion with thin and smooth walls near the midline very close to the bladder neck probably a prostate cyst. The size of the prostate cyst was 1.06×1.14×1.59 (Figures 2 and 3).

Uroflowmetry showed a max flow of 5.7 ml/sec and a mean flow of 2.7 ml/sec for a voided volume of 230 ml. (Figure 4). The impression was a bladder outlet obstruction due to a Prostate cyst or a bladder neck hyper trophy.

### Management

After the initial visit he was prescribed an alpha blocker, Tamsulosin 0.4 mg once daily for 4 weeks but his symptoms were not showing improvement. He opted to have cystoscopy and necessary treatment than waiting further on medication. There are some case studies available about transurethral treatment of prostate cysts. We had a discussion about the facilities available at our institution. He

opted to go for cystoscopy and laser de-roofing of the cyst if required and opted not to have folley catheter after the procedure.

Under general anesthesia cystoscopy was done using 23 F laser cystoscope. One shot of ceftizoxime 1 gm was given with induction. During the urethrocytoscopy we identified a hemispherical mass arising from the prostate surface obstructing the entire bladder neck region. The bladder neck was looking like a crescent valve (Figures 5-7). The center of the prostate lesion was initially incised using a 980 nm diode laser with 600 micron side firing fiber. The cyst ruptured after incision and a cloudy fluid was expelled out through the opening. The bladder wash was sent for culture. The walls were vaporized to de-roof the cyst (Figure 7). The appearance of bladder neck and prostate came back to normal after de-roofing (Figure 8). No bleeding was noticed and no catheter was put in. Patient voided spontaneously after recovery from anesthesia.

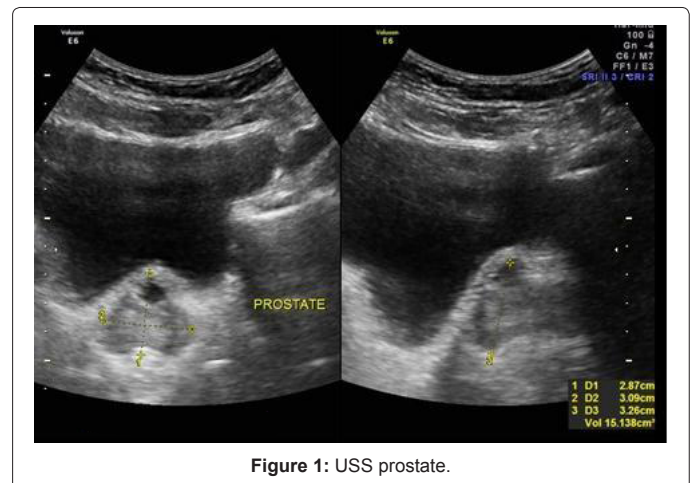


Figure 1: USS prostate.

\*Corresponding author: Ravisankar G Pillai, Urologist, Royal Bahrain Hospital, Kingdom of Bahrain, E-mail: [gopakravi@gmail.com](mailto:gopakravi@gmail.com)

Received February 02, 2013; Accepted February 28, 2013; Published March 02, 2013

Citation: Pillai RG, Naieb ZA (2013) Successful Endoscopic Laser De-roofing of Simple Prostatic Cyst Causing Bladder Outlet Obstruction-A Case Study. Med Surg Urol 2: 107. doi:10.4172/2168-9857.1000107

Copyright: © 2013 Pillai RG, et al. This is an open-access article distributed under the terms of the Creative Commons Attribution License, which permits unrestricted use, distribution, and reproduction in any medium, provided the original author and source are credited.

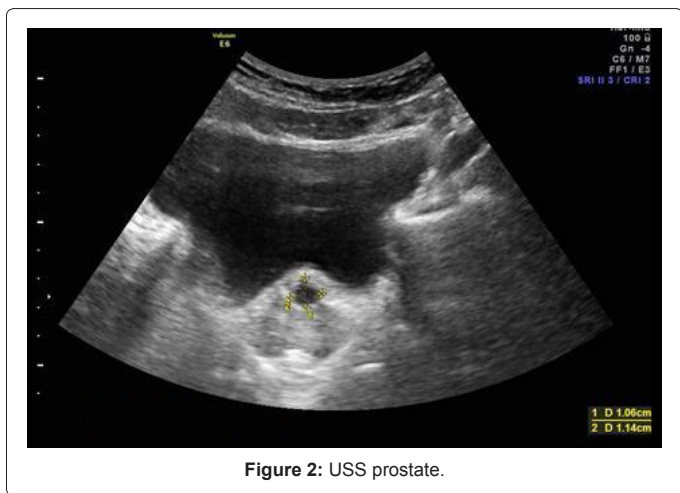


Figure 2: USS prostate.

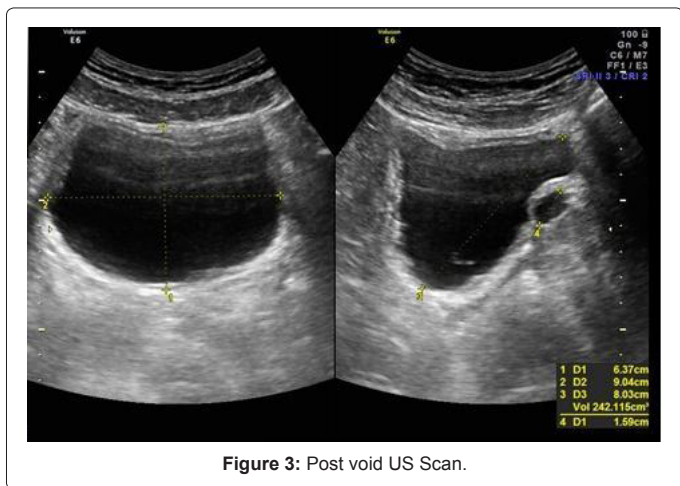


Figure 3: Post void US Scan.

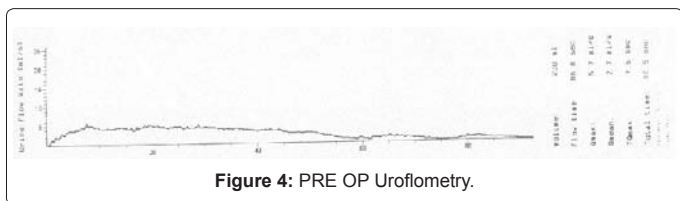


Figure 4: PRE OP Uroflowmetry.

He was discharged on the same day. Post operatively his symptoms disappeared and flow has come back to normal. The bladder wash culture came out to be normal with no growth. At 4 weeks post-operative period the uroflowmetry was repeated to show maximum flow of 26.7 ml/sec and a mean flow of 14.4 ml/sec for a voided volume of 495 ml (Figure 9). The QOL and IPSS score also came back to normal after 4 weeks post operatively. The repeat IPSS was 2 and QOL score was 1. No side effects were noticed except the mild dysuria for 1 week time. Because of the tremendous improvement in symptoms he declared the dysuria as not bothersome. He was allowed to have sexual activity after 2 weeks and he acknowledged having normal ejaculatory function without pain or discomfort.

## Discussion

### Cystic lesions of prostate

The regular use of ultrasound scan for evaluating Lower Urinary Tract Symptoms has shown up different cystic lesions of prostate

gland. There are many classifications available in the literature about cystic lesions in and around prostate gland. A complete classification of prostatic cyst described by Galosi et al. shows six distinct types based on TRUS and pathological features (Table 1) [1]. According to them the best modality to identify the details of prostatic cysts is trans-rectal sonographic examination. It was reported an approximately 1% incidence of congenital prostatic cysts at autopsy [2]. The incidence of prostate cyst reported in apparently healthy men is around 7.6% [3]. The incidence of prostatic cysts showed a bimodal distribution across age groups. The incidence in the youngest age group of 35-40 years was 10.1%, and the incidence in the oldest age group of 61-65 years was 11.6% [4]. The same study found a statistically significant increasing trend in the incidence of cysts with increasing prostatic weights. In approximately 5% of patients presented with lower urinary tract symptom the cause was attributed to prostate cysts [4].

**The midline cysts:** The midline prostatic cysts are located in the midline and arise from the region of the verumontanum and between the seminal vesicles, usually extend cephalad to the prostate gland. The midline prostate cysts include cysts of prostatic utricle, cystic dilatation of the prostatic utricle and enlarged prostatic utricle [1]. The histological feature of cysts of prostatic utricle is that the outlet to the urethra is

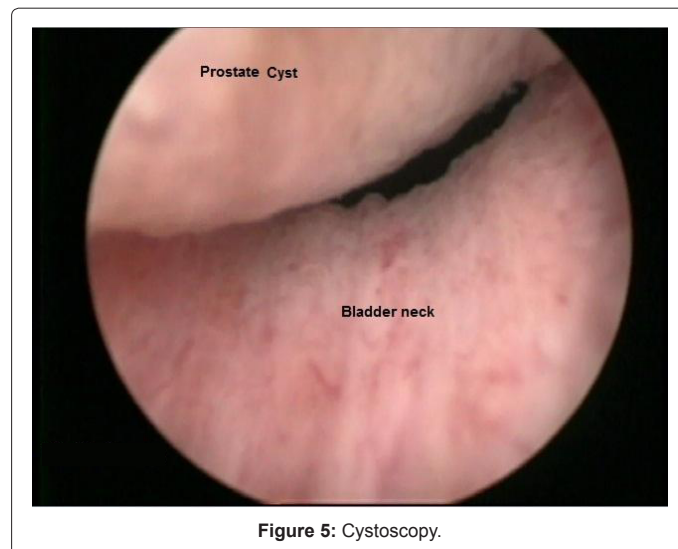


Figure 5: Cystoscopy.

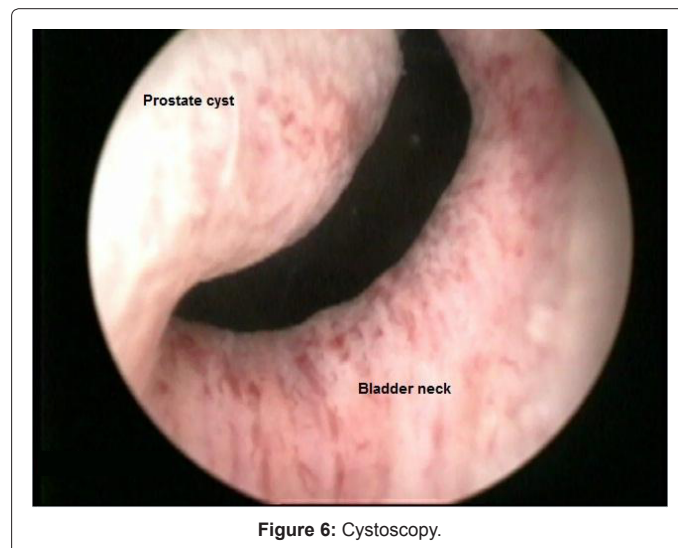
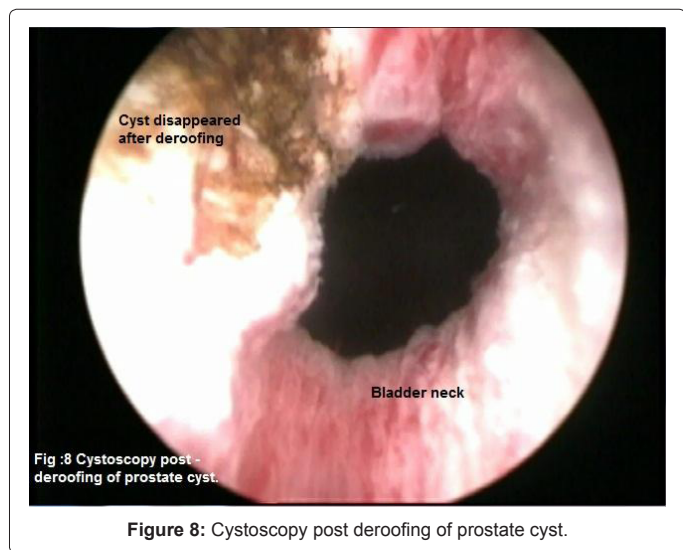
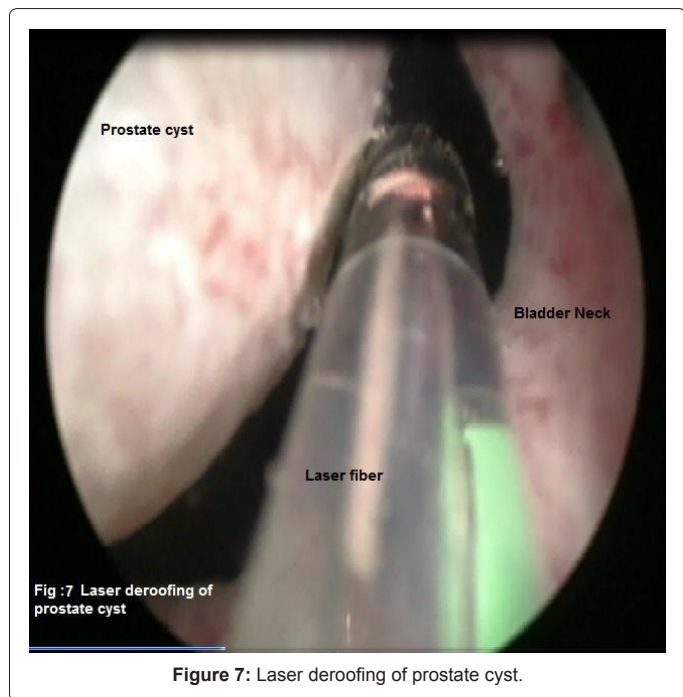


Figure 6: Cystoscopy.



absent while in the cystic dilatation of prostatic utricle the outlet to the urethra is present [5]. Clinical features overlap and include pelvic mass, obstructive and irritative urinary tract symptoms, hematuria, and suprapubic or rectal pain. Since cystic utricle communicate with the urethra and hence urine may pool and cause post void dribbling [6,7]. The enlarged prostatic utricle is usually identified in young patients with associated congenital anomalies like hypospadiasis or virilization defects. Histologically it is tubular structure communicating with the urethra [8].

**The cysts of ejaculatory duct:** Ejaculatory duct cysts are rare. They are due to obstruction of the ejaculatory duct that may be congenital or acquired [9]. On imaging by TRUS, these lesions appear to be cystic structures unilateral or bilateral along the ejaculatory duct just in midline or lateral to the midline in the central zone of the prostate. On aspiration they contain fructose or spermatozoa. Ejaculatory duct cysts commonly contain calculi. Sometimes they may contain pus or

hemorrhage. The symptoms usually present are hematospermia or dysuria.

**The cysts of parenchyma:** The simple cysts of retention cyst are acquired cysts due to obstruction of the glandular ductules, causing retention of prostatic secretions and dilatation of the acini [10]. They usually appear as smooth-walled, unilocular simple cysts and rarely become symptomatic. They occur in any glandular zone of the prostate and TRUS features are anechoic content usually less than 8 mm with thin and smooth wall or hairline septa [11]. The anatomical locations are lateral subcapsular, periurethral or in the bladder neck. The symptoms usually arise when the cyst size goes more than 3 cm but can occur with smaller cyst if the location is near the bladder neck.

The other group under this category is multiple cysts which are subdivided into ductal ectasia or microcysts, small cystic nodule and large multicystic nodule. The ductal ectasia can be related to the retention of secretions or due to simple atrophy. In TRUS duct ectasia appears as homogenous texture of the tissue with small anechoic lacunar spaces [10,12]. The small cystic nodules are a bunch of packed small cysts which may be related to simple atrophy or cystic degeneration of benign prostatic hypertrophy. Large multicystic nodules are composed of numerous simple cysts of different shapes and sizes packed together and which bulge the prostate capsule or the urethra. They are usually seen in transitional zone or in the peripheral zone [13].

**Complicated cysts:** Diabetic patients are at risk of getting prostatic abscess from acute bacterial infection, most often with *Escherichia coli*. The classical clinical signs and symptoms include fever, chills, dysuria, urinary frequency and urgency, hematuria, and pain. The suspicion of a prostate abscess is raised when along with clinical symptoms and elevated PSA, a cystic lesion with thickened walls, septations, or heterogeneous contents is seen in TRUS scan. Occasionally there can be granulomatous prostatitis with hypoechoic lesion in patients who had BCG therapy for TCC of urinary bladder. Some times isoechoic lesions with decreased blood flow are seen in TRUS after prostate biopsy. These are hemorrhagic cysts [14].

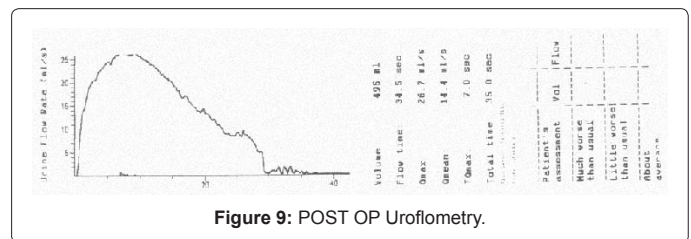


Figure 9: POST OP Uroflometry.

Classification of the Cysts of the Prostate Gland [1]	
1. Midline Cyst	
α)	Cysts of the PU.
β)	Cystic dilatation of the PU.
χ)	Enlarged prostatic utricle.
2. Cyst of the ED	
3. Cyst of the parenchyma.	
α)	Simple (retention cyst).
β)	Multiple.
i.	Ductal ectasia.
ii.	Small cystic nodule.
iii.	Large multicystic nodule.
4. Complicated cyst.	
α)	Infectious.
β)	Hemorrhagic
5. Cystic tumor	
6. Cyst secondary to other diseases.	

Table 1: Classification of the cysts of the prostate gland.

**Cystic tumor:** Cystic changes can be noticed in both benign and malignant prostate neoplasms. Cystadenoma is a rare benign tumor that can grow to a large size. TRUS features are multi-locular mass in the prostate with solid, anechoic content with thick and irregular walls or hairline septa.

Prostatic cystadenocarcinoma can be seen in TRUS as multiseptate cystic mass with thickened irregular walls. It may show features of infiltration of the capsular limit [15]. Rarely, high grade ductal prostate cancer, leiomyoma or liposarcoma in the prostate may have cystic elements. An MRI is indicated for local staging and if there is heterogeneity of signal intensity of the cystic components and the presence of soft-tissue elements in the lesion, we suspect a neoplastic cause [16].

**Cyst secondary to other diseases:** Parasitic cystic lesion from echinococcus and bilharziasis are rare in western countries but are recorded in endemic regions [17].

## Treatment

The literature about treatment of prostate cyst is rare. Trans-perineal ultrasound guided or CT guided or MRI guided aspiration as a diagnostic and therapeutic modality has been described in the literature [6,18]. Some case studies of Trans-urethral resection of the retention cyst are also available [18]. We couldn't identify any literature about the laser treatment of prostate cysts.

## Ethical Aspects

Written informed consent was obtained from the patient for publication of this case report and accompanying images.

## Competing Interests

We declare that we have no competing interests.

## Conclusion

Midline prostate cyst can be a reason for bladder outlet obstruction. The patient will have tremendous improvement in symptoms with trans-urethral de-roofing of the cyst wall. The laser application made it even easy and catheter less day case procedure. The improvement in quality of life and preservation of ejaculatory function is probably the benefit of laser vaporization. We need further studies to compare the benefit of other transurethral methods of de-roofing the cyst wall and laser de-roofing. But because of the rarity of symptomatic prostate cysts, this will be difficult. The other aspects of prostate cysts like infertility and impact of treatment also needs to be addressed in further studies.

## References

- Galosi AB, Montironi R, Fabiani A, Lacetera V, Gallé G, et al. (2009) Cystic lesions of the prostate gland: an ultrasound classification with pathological correlation. *J Urol* 181: 647-657.
- Moore RA (1937) Pathology of the prostatic utricle. *Arch Pathol* 23: 517-52.
- Ishikawa M, Okabe H, Oya T, Hirano M, Tanaka M, et al. (2003) Midline prostatic cysts in healthy men: incidence and transabdominal sonographic findings. *AJR Am J Roentgenol* 181: 1669-1672.
- Dik P, Lock TM, Schrier BP, Zeijlemaker BY, Boon TA (1996) Transurethral marsupialization of a medial prostatic cyst in patients with prostatitis-like symptoms. *J Urol* 155: 1301-1304.
- Kato H, Komiyama I, Maejima T, Nishizawa O (2002) Histopathological study of the müllerian duct remnant: clarification of disease categories and terminology. *J Urol* 167: 133-136.
- Shabsigh R, Lerner S, Fishman IJ, Kadmon D (1989) The role of transrectal ultrasonography in the diagnosis and management of prostatic and seminal vesicle cysts. *J Urol* 141: 1206-1209.
- Kato H, Hayama M, Furuya S, Kobayashi S, Islam AM, et al. (2005) Anatomical and histological studies of so-called Müllerian duct cyst. *Int J Urol* 12: 465-468.
- Hinman F Jr (1993) Prostate and urethral sphincters. In: *Atlas of Uro-Surgical Anatomy*. Philadelphia: WBSaunders Co 345-388.
- Littrup PJ, Lee F, McLeary RD, Wu D, Lee A, et al. (1988) Transrectal US of the seminal vesicles and ejaculatory ducts: clinical correlation. *Radiology* 168: 625-628.
- Patel U, Rickards D (2002) Transrectal ultrasound of the abnormal prostate—less common prostate abnormalities. In: *Handbook of Transrectal Ultrasound and Biopsy of the Prostate*. Edited by Uand Patel D. Rickards London: Martin Dunitz 85-90.
- Yasumoto R, Kawano M, Tsujino T, Shindow K, Nishisaka N, et al. (1997) Is a cystic lesion located at the midline of the prostate a müllerian duct cyst? Analysis of aspirated fluid and histopathological study of the cyst wall. *Eur Urol* 31: 187-189.
- Hamper UM, Epstein JI, Sheth S, Walsh PC, Sanders RC (1990) Cystic lesions of the prostate gland. A sonographic-pathologic correlation. *J Ultrasound Med* 9: 395-402.
- Søndergaard G, Vetner M, Christensen PO (1987) Periferal cystic hyperplasia of the prostate gland. *Acta Pathol Microbiol Immunol Scand A* 95: 137-139.
- Herranz Amo F, Verdú Tartajo F, Díez Cordero JM, Lledó García E, Bueno Chomón G, et al. (1999) Hemorrhagic prostatic cyst following ultrasound guided biopsy. A case report. *Arch Esp Urol* 52: 379-380.
- Tuziak T, Spiess PE, Abrahams NA, Wrona A, Tu SM, et al. (2007) Multilocular cystadenoma and cystadenocarcinoma of the prostate. *Urol Oncol* 25: 19-25.
- Allen EA, Brinker DA, Coppola D, Diaz JI, Epstein JI (2003) Multilocular prostatic cystadenoma with high-grade prostatic intraepithelial neoplasia. *Urology* 61: 644.
- Papanicolaou N, Pfister RC, Stafford SA, Parkhurst EC (1987) Prostatic abscess: imaging with transrectal sonography and MR. *AJR Am J Roentgenol* 149: 981-982.
- Halpern EJ, Hirsch IH (2000) Sonographically guided transurethral laser incision of a Müllerian duct cyst for treatment of ejaculatory duct obstruction. *AJR Am J Roentgenol* 175: 777-778.