

## Strategy of Endoscopic Pancreatic Duct Drainage for Recurrent Chronic Pancreatitis

Yoshiaki Kawaguchi\*, Masami Ogawa, Atsuko Maruno, Hiroki Yuhara, Hiroyuki Ito and Tetsuya Mine

Department of Gastroenterology, Tokai University School of Medicine, Isehara, Japan

### Abstract

**Background:** Methods of pancreatic duct (PD) drainage for recurrent chronic pancreatitis (CP) include endoscopic drainage combined with ESWL and surgical drainage. Although the endoscopic drainage has become widespread as this method is minimally invasive, there are cases in which stent removal is difficult. We retrospectively examined the current status of endoscopic drainage for recurrent CP at our hospital.

**Methods:** This study included 66 patients with recurrent CP (57 men and 9 women with a mean age of  $59 \pm 14$  years, including 58 patients with alcoholic CP) who underwent endoscopic drainage between April 2006 and April 2012. Based on the initial images of PD, the patients were classified into the following types to compare their backgrounds and treatment processes: pancreatolithiasis (Stone) type (7 patients), PD stenosis (Stenosis) type (18), and Stone+Stenosis type (41). Moreover, patients with PD stent were divided into the following groups to compare their backgrounds and treatment processes: stent-removed group and stent-maintained group in which the stent could not be removed.

**Results:** The procedure was successful in 61 patients (92%). Complete pain relief without analgesics was achieved in 60 patients (91%). The early complications were post-ERCP pancreatitis in 11 patients (2.7%, all mild in severity), and hemorrhage, basket impaction, and rupture of the pancreatic duct in 1 patient (0.5%) each. The late complications were pancreatic ductitis (0.7%), stent displacement (0.5%), stent migration (1.5%), and tear during removal of stent (1%). In Stone type patients, the mean number of procedural sessions and the number of patients who required at least 1 year of treatment were significantly smaller than in those with PD stenosis (Stenosis type or Stone+Stenosis type) ( $P=0.0133$  and  $P=0.0043$ , respectively). Patients with Stenosis type had a significantly smaller mean number of procedural sessions ( $P=0.0423$ ) and a significantly lower incidence of complications ( $P=0.0366$ ) than those with Stone+Stenosis type. Comparison between the stent-removed and stent-maintained groups revealed no significant differences in the mean number of procedural sessions, the number of patients with implantation of a stent with a diameter (thicker than 8.5-Fr), or the incidence of complications. In the stent-removed group, the number of patients who required at least 1 year of treatment was significantly smaller ( $P=0.0285$ ).

**Conclusions:** In the short term, endoscopic stenting combined with ESWL was effective for pain relief, was associated with a low incidence of complications, and could be performed safely and effectively. For Stonetype recurrent CP, endoscopic therapy is highly effective and useful. On the other hand, from the long-term perspective, there are cases, especially among those with the Stone+Stenosis type, in which stent removal is difficult. Thus, surgical drainage should also be considered.

**Keywords:** Recurrent chronic pancreatitis; Pancreatic stent; ESWL; Pancreatic stone; Pancreatic duct stenosis

### Introduction

Recurrent chronic obstructive pancreatitis is attributed to pancreatic flow obstruction caused by PD stenosis, pancreatolithiasis, pancreas divisum, etc., and the consequent increased internal pressure in the caudal PD [1-3]. Methods of PD decompression include surgical procedures, such as pancreatectomy and pancreaticojejunostomy, as well as endoscopic PD stenting combined with extracorporeal shock wave lithotripsy (ESWL). Previous reports showed favorable results of PD stenting, with success rates of 72-100% and symptom relief rates of 65-87% [4-11]. At present, minimally invasive endoscopic therapy is widely employed [12]. However, prospective randomized controlled trials comparing endoscopic therapy and surgical drainage have been conducted and shown surgical drainage to be more effective [13,14]. Further studies are needed for optimal selection of therapeutic methods.

Endoscopic PD stenting combined with ESWL is itself a minimally invasive procedure and is in widespread use. However, there are problems with diagnosing whether a stenotic lesion of PD is benign or malignant, deciding on whether the procedure is indicated, techniques for management of severe stenosis, types of stents to be implanted (diameter and form), duration of implantation, and complications. After a stent is implanted especially, in more than a

few cases it cannot be removed and must repeatedly be replaced with a new one. If such cases can be predicted before stenting, surgical drainage might be applied as an initial procedure. In this study, we retrospectively examined the current status of endoscopic therapy for recurrent CP, especially endoscopic PD stenting, at our department. Moreover, we aimed to analyze patient background data by dividing patients undergoing PD stenting into a group in which the stent was removed and a group in which the stent could not be removed, remained implanted, and thus had to repeatedly be replaced with a new one.

### Patients and Methods

#### Patients

Between April 2006 and April 2012, endoscopic drainage was

\*Corresponding author: Yoshiaki Kawaguchi, Department of Gastroenterology, Tokai University School of Medicine, Isehara, Japan; E-mail: [y711kawa@is.icc.u-tokai.ac.jp](mailto:y711kawa@is.icc.u-tokai.ac.jp)

Received March 11, 2013; Accepted March 25, 2013; Published March 27, 2013

**Citation:** Kawaguchi Y, Ogawa M, Maruno A, Yuhara H, Ito H, et al. (2013) Strategy of Endoscopic Pancreatic Duct Drainage for Recurrent Chronic Pancreatitis. Pancreatic Dis Ther S3: 002. doi:10.4172/2165-7092.S3-002

**Copyright:** © 2013 Kawaguchi Y, et al. This is an open-access article distributed under the terms of the Creative Commons Attribution License, which permits unrestricted use, distribution, and reproduction in any medium, provided the original author and source are credited.

performed in 86 patients with recurrent CP (436 procedures). Among them, 66 patients who received some form of treatment for PD were selected as the study population (410 procedures; 57 men (86%) and 9 women (14%) with a mean age of  $59 \pm 14$  years [range, 34-80 years]); causes of recurrent CP were alcohol consumption in 58 patients (87%), pancreas divisum in 1 (2%), postoperative anastomotic stenosis in 1 (2%), and idiopathic in 6 (9%) (Table 1). The breakdown of the 20 excluded patients was as follows: 11 undergoing only endoscopic retrograde cholangiopancreatography (ERCP) and cytology, 6 undergoing only endoscopic bile duct stenting, and 3 in whom cannulation of PD was not performed (due to post-pancreatectomy in 1, groove pancreatitis in 1, and only choledocholithotripsy in 1).

### Diagnosis of chronic pancreatitis

RecurrentCP was diagnosed based on images obtained by extracorporeal and endoscopic ultrasound (EUS), computed tomography (CT), magnetic resonance imaging (MRI), and ERCP in addition to biochemical data. In all patients, the imaging findings of PD met the definition of severe pancreatitis according to the Cambridge criteria [15].

### Indications for endoscopic pancreatic duct drainage

At our hospital, endoscopic PD drainage is indicated for (1) symptomatic patients, (2) asymptomatic patients whose pancreatic function may be preserved, and (3) patients with alcoholic pancreatitis who can abstain from drinking.

### ESWL

When the disease was attributable to pancreatolithiasis and calcification, ESWL was performed as needed. An electromagnetic lithotripter (Dornier Lithotripter S, Dornier MedTech, Wessling, Germany) was used for 41 patients. The locations of the stones were placed in the shock-wave focus employing an X-ray focusing system. ESWL was performed as needed according to the size and number of stones and followed by endoscopic therapy.

### Classification based on initial ERCP findings

Based on the initial images of PD, recurrent CP was classified into 3 types: pancreatolithiasis (Stone) type in 7 patients (11%) (Figure 1a), PD stenosis (Stenosis) type in 18 (27%) (Figure 1b), and Stone+Stenosis type in 41 (62%) (Figure 1c). There were 59 patients (89%) with PD stenosis (Table 2).

For all patients with the Stone type, ESWL was performed as needed, and stones were removed with a basket or a balloon catheter. A PD stent (5- or 7-Fr) was used only for prevention of impaction. Unless there are residual stones, it would be unnecessary to leave the stent implanted. For patients with the Stenosis type, a PD stent was implanted to drain pancreatic juice and to dilate PD. Because it is especially important to differentiate theStenosis type from pancreatic cancer, cytology and biopsy were performed. For 34 patients with the Stone+Stenosis type, stones were fragmented by ESWL and removed.

	n (%)
Sex (male/female)	57 (86%) / 9 (14%)
Age (years)*	$59 \pm 14$ (34-80)
Cause Alcohol	58 (87%)
Divisum	1 (2%)
Post-op	1 (2%)
Idiopathic	6 (9%)

\*Mean  $\pm$  SD

Table 1: Patient Characteristics (n=66).

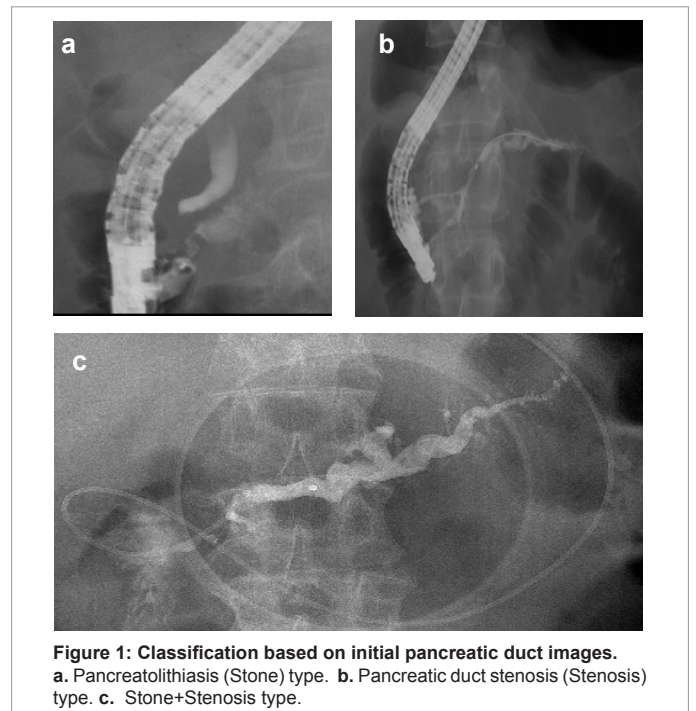


Figure 1: Classification based on initial pancreatic duct images. a. Pancreatolithiasis (Stone) type. b. Pancreatic duct stenosis (Stenosis) type. c. Stone+Stenosis type.

	n (%)
Pancreatolithiasis (Stone) type	7 (11%)
Pancreatic duct stenosis (Stenosis) type	18 (27%)
Pancreatolithiasis (Stone)+Pancreatic duct stenosis (Stenosis) type	41 (62%)

Table 2: Initial ERCP findings.

A PD stent was implanted to drain pancreatic juice and dilate PD. Because removal of pancreatic stones is often difficult in the presence of PD stenosis, lithectomy was performed as soon as possible. Even when there were residual stones, a stent was implanted. Removal of residual stones was postponed until the next procedure.

### Endoscopic Therapy

#### Crossing the stenosis with a guidewire

ERCP was performed with a JF-240, a JF-260V or a TJF-260V (Olympus Medical Systems Corp., Tokyo, Japan) under conscious sedation with diazepam and pethidine. We attempted to cross the stenotic lesion with a guidewire (Jagwire™ High Performance Guidewire, Boston Scientific Corp., Natick MA, USA). Upon successfully crossing the stenosis, Intra Ductal Ultra Sonography (IDUS) after the initial procedure, brushing cytology, pancreatic juice cytology, and biopsy were performed to exclude cancer. When crossing of a stenotic lesion was difficult due to the severe stenosis, an approach via the minor papilla was attempted.

#### Dilation of stenosis

After crossing the sites of stenosis, the stenotic lesions were dilated with a dilation catheter (6-,7-, or 9-Fr, Soehendra Biliary Dilation Catheter, Cook Medical., Bloomington, IN, USA) or a dilation balloon catheter (Hurricane™ RX Balloon Dilation Catheter, 6 mm in diameter and 2 cm in length, Boston Scientific Corp., Natick MA, USA). In case of difficulty with dilation, a Soehendra Stent Retriever

(5- or 7-Fr, Cook Medical., Bloomington, IN, USA) was used to attempt dilation of stenotic lesions.

### Pancreatic duct stenting

After dilation, a straight (GeenenPancreatic Stent Sets, Cook Medical., Bloomington, IN, USA) or S-ShapedPancreatic Stent (Olympus Medical Systems Corp., Tokyo, Japan) 5-, 7-, 8.5-, or 10-Fr polyethylene stent with multiple side holes was implanted in the stenotic lesion.

### Lithectomy

The stones in PD were removed with a basket catheter (Flower Basket or TetraCatch, Olympus Medical Systems Corp., Tokyo, Japan) or a balloon catheter (Offset Balloon Catheter, Zeon Medical Inc., Tokyo, Japan) during ERCP. In order to facilitate lithectomy, papillotomy was applied to the bile duct orifice and the PD orifice.

### Treatment protocol

Every 3 months, a stent was removed, and pancreatography was performed for assessment. In patients with residual stenosis, a stent was implanted again. At this point, a stent with a larger diameter was used if possible. Finally, the stent should be removed within 1 year. When symptoms of pancreatitis were caused by stent occlusion, the stent was replaced. When there were residual stones, they were removed as needed at the time of replacing the stent.

### Study items

The current status of endoscopic PD drainage at our hospital was retrospectively examined by comparing patients according to the above-described classification based on the images of PD. The study items were patient characteristics, outcomes after therapy, complications, and follow-up results. Out of the 66 patients undergoing endoscopic therapy, 7 patients with Stone type, 5 with treatment failure, 1 undergoing only bile duct stenting, and 1 undergoing only dilation of PD were excluded; and the remaining 52 were divided into the stent-removed group of 24 and the stent-maintained group of 28. In the stent-maintained group, the following patients were excluded: 5 with less than 3 months of stenting, 1 with failure of continuation of stenting, 2 deaths from intercurrent disease, and 1 drop-out case. The remaining 19 patients were ultimately included in the stent-maintained group and compared to the 24 patients in the stent-removed group (Figure 2).

### Statistical Analysis

Results were expressed as means (SD) or as a percentage of the total number of patients. A  $\chi$ -squared analysis or a two-tailed Fisher's exact test was used to compare differences between the two groups. A P value of less than 0.05 was considered to be significant. All analyses were performed using statistical software (Stat View Ver.5.0, SAS Institute, Cary, NC, United States).

### Results

#### Success rate of the procedure

The procedure was successful in 61 patients (92%), unsuccessful in 5. In 4 of the 5 patients, although the procedure was not completed due to large stones or PD being full of stones, PD dilation decreased. In other words, PD dilatation improved in 65 patients (98%). The breakdown of the procedures was concomitant ESWL in 41 patients (62%), PD stenting in 51 (77%), bile duct stenting in 14 (21%), and an

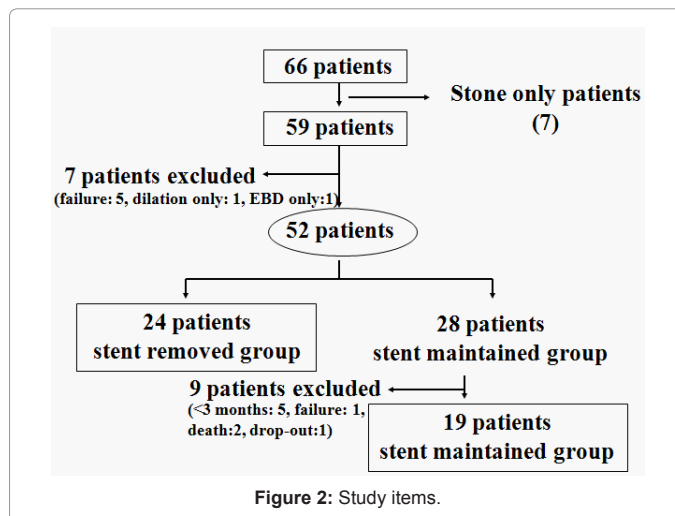


Figure 2: Study items.

	n (%)
Procedural success rate	61 (92%)
Reduction rate of pancreatic duct dilatation	65 (98%)
Concomitant ESWL	41 (62%)
Pancreatic duct stenting	51 (77%)
Bile duct stenting	14 (21%)
Approach via minor papilla	14 (21%)

Table 3: Procedural success rates and breakdown of treatment methods.

	n (%)
Complete pain relief	60/66 (91%)
Partial pain relief	5/66 (7%)
No improvement	1/66 (2%)

Table 4: Outcomes after Therapy.

approach via the minor papilla in 14 (21%) (Table 3).

### Outcomes after therapy

Complete pain relief with no requirement for analgesics was achieved in 60 patients (91%). Partial pain relief with reduction in the doses of analgesics was achieved in 5 patients (7%). There was no improvement in 1 patient (2%). Thus, effects, to some degree, were observed in 65 patients (98%) (Table 4).

### Complications

We examined a total of 407 procedures including 229 PD stenting procedures. The early complications were ERCP-induced pancreatitis in 11 patients (2.7%, all mild in severity) and hemorrhage, basket impaction, and rupture of PD in 1 patient (0.2%) each. The late complications were pancreatic ductitis in 3 patients (0.7%), stent displacement in 2 (0.5%), PD stent migration in 4 (1%, retrieved in all patients), bile duct stent migration in 2 (0.5%, retrieved in all patients), and tear during removal of PD stent in 4 (1%, retrieved in 3 patients) (Table 5).

### The pancreatolithiasis (Stone) type vs. the types including pancreatic duct stenosis

Comparison between Stone type and the types including pancreatic duct stenosis (Stenosis type or Stone+Stenosis type) revealed no significant differences in sex, age, or causes. In Stone type, the mean number of procedures was significantly smaller (P=0.0133),

	n (%)
Early stage	
ERCP-induced pancreatitis	1 (2.7%): mild in all
Hemorrhage	1 (0.2%): after EST
Basket impaction	1 (0.2%)
Rupture of pancreatic duct	1 (0.2%)
Perforation	0 (0%)
Duodenal mucosal injury	1 (0.2%)
Late stage	
Pancreatic ductitis	3 (0.7%)
Stent displacement	2 (0.5%)
Stent migration	4 (1%)
	2 (0.5%)
Tear during pancreatic duct stent removal	4 (1%)
Pancreatic duct-portal vein fistula	1 (0.2%)

**Table 5:** Complications (total procedures: 407, ERPD: 229).

	Stone type (7)	Stone+Stenosis type (41) or Stenosis type (18)	P value
Male sex	7/7 (100%)	51/59 (86%)	0.5842
Age, mean±SD (year)	55 ± 12	60 ± 12	0.4323
Cause: Alcohol	7/7 (100%)	51/59 (86%)	0.5842
Bile duct stenting	0 (0%)	14/59 (24%)	0.3303
Pancreatic duct stenting	0 (0%)	52/59 (88%)	<.0001
Approach via minor papilla	0 (0%)	14/59 (24%)	0.3303
Mean number of procedures	2.1 (1-3)	6.7 (1-23)	0.0133
Treatment duration>1 year	0/7 (0%)	34/59 (58%)	0.0043
Complications	0 (0%)	19/59 (32%)	0.1793

**Table 6:** Stone type vs. the types including pancreatic duct stenosis.

	Stone+Stenosis type (41)	Stenosis type (18)	P value
Male sex	35/41 (85%)	16/18 (89%)	>.9999
Age, mean±SD (year)	60 ± 11	59 ± 13	0.8321
Cause: Alcohol	35/41 (85%)	16/18 (89%)	>.9999
Bile duct stenting	11/41 (27%)	3/18 (17%)	0.5163
Pancreatic duct stenting	35/41 (85%)	17/18 (94%)	0.4217
Inability to implant a pancreatic duct stent	5/41 (12%)	0/18 (0%)	0.3101
Approach via minor papilla	12/41(29%)	2/18 (11%)	0.1891
Removal of a pancreatic duct stent	16/41(39%)	8/18 (44%)	0.6964
Mean number of procedures	8.0 (2-23)	3.7 (1-17)	0.0423
Treatment duration>1 year	24/41 (59%)	10/18 (56%)	0.8310
Maximal stent diameter>8.5 Fr	16/41 (39%)	8/18 (44%)	0.6964
Complications	16/41 (39%)	2/18 (11%)	0.0366

**Table 7:** Stone+Stenosis type vs. Stenosis type.

and there were significantly fewer patients who required at least 1 year of treatment (P=0.0043). No difference was observed in the incidence of complications (Table 6).

### The pancreatolithiasis+pancreatic duct stenosis (Stone+Stenosis type)type vs. the pancreatic duct stenosis (Stenosis) type

Comparison between Stone +Stenosis type and Stenosis type revealed no significant differences in sex, age, causes, the number of patients with failed PD stenting, or the number of patients in whom a PD stent was removed. In Stenosis type, the mean number of procedures was significantly smaller (P=0.0423), and the incidence of complications was also significantly lower (P=0.0366). However, there

	Stent-removed group (24)	Stent-maintained group (19)	P value
Male sex	23/24 (96%)	15/19 (79%)	0.1529
Age, mean ± SD (year)	60 ± 12	61 ± 11	0.8325
Cause: Alcohol	23/24 (96%)	18/19 (95%)	>.9999
Concomitant ESWL	21/24 (90%)	17/19 (89%)	>.9999
Bile duct stenting	5/24 (21%)	3/19 (16%)	>.9999
Approach via minor papilla	4/24 (17%)	6/19 (32%)	0.2952
Mean number of procedures	7.5 (2-17)	7.0 (1-23)	0.8321
Treatment duration>1 year	6/24 (25%)	11/19 (58%)	0.0285
Maximal stent diameter>8.5 Fr	12/24 (50%)	8/19 (42%)	0.6062
Complications	5/24 (21%)	7/19 (37%)	0.3137

**Table 8:** Stent-removed group vs. Stent-maintained group.

was no difference in the number of patients who required at least 1 year of treatment (Table 7).

### Stent-removed group vs. Stent-maintained group

Comparison between the stent-removed and stent-maintained groups revealed no significant differences in sex, age, causes, concomitant ESWL, the mean number of procedures, implantation of a large stent with a diameter (thicker than 8.5-Fr), or the incidence of complications. In the stent-removed group, the number of patients who required at least 1 year of treatment was significantly smaller (P=0.0285) (Table 8).

### Discussion

In this study, male patients with alcoholic recurrent chronic obstructive pancreatitis accounted for approximately 90% of the subjects. Although this figure is consistent with those in previous reports, the number of female patients with alcoholic chronic pancreatitis has also been increasing in recent years [1-12]. When alcohol consumption is a cause of pancreatitis, an important condition for treatment is whether patients can abstain from drinking. Although it can be assumed that drinking will often be resumed after alleviation of symptoms, such as pain, in many cases, it is difficult to assess the degree of compliance with abstinence.

Moreover, 90% of patients with recurrent chronic obstructive pancreatitis had stenotic lesions. Approximately 80% of the patients required PD stenting, and 60% required concomitant ESWL. There are also reports describing favorable outcomes as having been achieved with only lithotripsy, such as ESWL, without stenting [16-18]. However, because our study included many patients with stones combined with stenosis, we considered lithotripsy alone to be insufficient treatment. Because the basis of managing recurrent chronic obstructive pancreatitis is treatment for stenosis, it was suggested that a combination of pancreatic duct stenting and ESWL is necessary.

Moreover, endoscopic stenting combined with ESWL was effective for pain relief, was associated with a low incidence of complications of endoscopic therapy, and could be performed safely and effectively. This result is consistent with the favorable 84% success rate of drainage/pain relief with stenting reported by Costamagna et al. [19]. Endoscopic therapy combined with ESWL was demonstrated to be an extremely effective therapeutic method in the short term.

Based on the comparison of patients classified according to the initial images of PD, those with Stone type had a significantly smaller number of procedures and significantly shorter treatment duration than patients with pancreatic duct stenosis (Stone+Stenosis type or Stenosis type). Because therapeutic effects and outcomes are favorable

in patients with only pancreatolithiasis, they may be good candidates for endoscopic therapy combined with ESWL. Moreover, compared to patients with Stenosis type, those with Stone+Stenosis type included more patients who required ESWL, and they tended to undergo a significantly larger number of procedures and had a significantly higher incidence of complications. There were also refractory cases and those in which a stent could not be removed. Treatments, including surgical drainage, for patients with Stone+Stenosis type, who accounted for 62% in this study, may need to be reconsidered.

In this study, the success rates and outcomes of endoscopic PD drainage were favorable and appeared to be satisfactory as short-term effects. In terms of long-term effects, however, the inability to remove a stent would require regular replacement of stents and consequently reduce quality of life for patients. We believe that surgical drainage should have been selected for patients whose stent could not be removed. It would be better if patient in whom stent removal would be difficult could be predicted beforehand. In this regard, further studies are needed.

In hopes of achieving dilation of a stenotic lesion by stenting, we have attempted the implantation of PD stents with the largest possible diameter (8.5- or 10-Fr). However, comparison between the stent-removed and stent-maintained groups suggested that stents with a larger diameter might not contribute to dilation of stenotic lesions. In recent years, implantation of a covered metallic stent based on this premise of removal has been reported [20,21]. Because a dilating effect can be expected, this procedure may be useful in cases with pancreatolithiasis in the caudal pancreatic duct. However, there are concerns regarding the duration of implantation and complications, such as migration, displacement, and difficulty removing the stent. Studies focusing on the safety of this strategy are needed.

In the stent-removed group, the duration of implantation tended to be shorter than that in the stent-maintained group. In cases with solitary pancreatic duct stenosis or pancreatolithiasis, early treatment may prevent progression of pathological conditions. For patients who would require long-term implantation of a stent, it may be better to consider surgical drainage given the possible complications associated with stent replacement and adverse effects of long-term stenting, as well as medical costs.

In order to achieve favorable outcomes with endoscopic therapy, selection of patients appears to be extremely important. Farnbacher et al. reported that the only index predicting long-term remission of pain after endoscopic drainage is short disease duration [22]. Future studies should focus on how to determine whether endoscopic therapy or surgical drainage should be selected as the initial treatment.

## References

1. Gulliver DJ, Edmunds S, Baker ME, Paine S, Baillie J, et al. (1992) Stent placement for benign pancreatic diseases: correlation between ERCP findings and clinical response. *AJR Am J Roentgenol* 159: 751-755.
2. Guda NM, Partington S, Freeman ML (2005) Extracorporeal shock wave lithotripsy in the management of chronic calcific pancreatitis: a meta-analysis. *JOP* 6: 6-12.
3. Kawaguchi Y, Tetsuya M (2012) Endoscopic Therapy for Chronic Recurrent Pancreatitis. *Journal of Gastroenterology and Hepatology Research* 1: 283-288.
4. Cremer M, Deviere J, Delhaye M, Baize M, Vandermeeren A (1991) Stenting in severe chronic pancreatitis: results of medium-term follow-up in seventy-six patients. *Endoscopy* 23: 171-176.
5. Rösch T, Daniel S, Scholz M, Huijbregtse K, Smits M, et al. (2002) Endoscopic treatment of chronic pancreatitis: a multicenter study of 1000 patients with long-term follow-up. *Endoscopy* 34: 765-771.
6. Dite P, Ruzicka M, Zboril V, Novotný I (2003) A prospective, randomized trial comparing endoscopic and surgical therapy for chronic pancreatitis. *Endoscopy* 35: 553-558.
7. Ponchon T, Bory RM, Hedelius F, Roubein LD, Paliard P, et al. (1995) Endoscopic stenting for pain relief in chronic pancreatitis: results of a standardized protocol. *Gastrointest Endosc* 42: 452-456.
8. Smits ME, Badiga SM, Rauws EA, Tytgat GN, Huijbregtse K (1995) Long-term results of pancreatic stents in chronic pancreatitis. *Gastrointest Endosc* 42: 461-467.
9. Byrne RL, Gompertz RH, Venables CW (1997) Surgery for chronic pancreatitis: a review of 12 years experience. *Ann R Coll Surg Engl* 79: 405-409.
10. Weber A, Schneider J, Neu B, Meining A, Born P, et al. (2007) Endoscopic stent therapy for patients with chronic pancreatitis: results from a prospective follow-up study. *Pancreas* 34: 287-294.
11. Sasahira N, Tada M, Isayama H, Hirano K, Nakai Y, et al. (2007) Outcomes after clearance of pancreatic stones with or without pancreatic stenting. *J Gastroenterol* 42: 63-69.
12. Nguyen-Tang T, Dumonceau JM (2010) Endoscopic treatment in chronic pancreatitis, timing, duration and type of intervention. *Best Pract Res Clin Gastroenterol* 24: 281-298.
13. Cahen DL, Gouma DJ, Nio Y, Rauws EA, Boermeester MA, et al. (2007) Endoscopic versus surgical drainage of the pancreatic duct in chronic pancreatitis. *N Engl J Med* 356: 676-684.
14. Cahen DL, Gouma DJ, Laramée P, Nio Y, Rauws EA, et al. (2011) Long-term outcomes of endoscopic vs surgical drainage of the pancreatic duct in patients with chronic pancreatitis. *Gastroenterology* 141: 1690-1695.
15. Axon AT, Classen M, Cotton PB, Cremer M, Freeny PC, et al. (1984) Pancreatography in chronic pancreatitis: international definitions. *Gut* 25: 1107-1112.
16. Dumonceau JM, Costamagna G, Tringali A, Vahedi K, Delhaye M et al. (2007) Treatment for painful calcified chronic pancreatitis: extracorporeal shock wave lithotripsy versus endoscopic treatment: a randomised controlled trial. *Gut* 56: 545-552.
17. Wong T (2007) Endoscopic versus surgical treatment for chronic pancreatitis. *N Engl J Med* 356: 2101.
18. Delhaye M, Deviere J (2007) Endoscopic versus surgical treatment for chronic pancreatitis. *N Engl J Med* 356: 2101-2102.
19. Costamagna G, Bulajic M, Tringali A, Pandolfi M, Gabbrielli A, et al. (2006) Multiple stenting of refractory pancreatic duct strictures in severe chronic pancreatitis: long-term results. *Endoscopy* 38: 254-259.
20. Park do H, Kim MH, Moon SH, Lee SS, Seo DW, et al. (2008) Feasibility and safety of placement of a newly designed, fully covered self-expandable metal stent for refractory benign pancreatic ductal strictures: a pilot study (with video). *Gastrointest Endosc* 68: 1182-1189.
21. Moon SH, Kim MH, Park do H, Song TJ, Eum J, et al. (2010) Modified fully covered self-expandable metal stents with antimigration features for benign pancreatic-duct strictures in advanced chronic pancreatitis, with a focus on the safety profile and reducing migration. *Gastrointest Endosc* 72: 86-91.
22. Farnbacher MJ, Schoen C, Rabenstein T, Benninger J, Hahn EG, et al. (2002) Pancreatic duct stones in chronic pancreatitis: criteria for treatment intensity and success. *Gastrointest Endosc* 56: 501-506.

This article was originally published in a special issue, [Therapeutic Endoscopy](#) handled by Editor(s), Dr. Vien X Nguyen, Mayo College of Medicine, USA