

## Spontaneous Uterus Rupture in the Post-partum

Pafumi C\*, Leanza V, Carbonaro A, Stracquadanio M, Leanza G and D'Agati A

Department of Gynaecology and Obstetrics, Assisted Department of Reproduction, University of Catania, Italy

### Abstract

Uterine rupture occurs when the integrity of the myometrial wall is compromised. It could interest the uterine body (prior to labour) or the lower segment (during labour). The main causes of uterine rupture are obstetric anamnestic factors and/or the administration of oxytocin.

The authors report the case of a 37 years old patient with risk factors for uterine rupture of precedent endometritis post-abortion. After the expulsion of the placenta the mother had continuous blood loss, for this reason she was subjected to subtotal hysterectomy. Histological examination revealed the absence of decidua in the uterine fundus and thinning of the myometrium. Histological examination of the lesion at the site commented that there was infiltration of the chorionic villi into the endometrium, and this is undoubtedly the features of placenta accreta.

**Keywords:** Endometritis; Post-partum; Uterine rupture

### Introduction

Uterine rupture is potentially life-threatening to both mother and baby. It occurs when the integrity of the myometrial wall is compromised. This usually occurs during the last weeks of pregnancy, labour or delivery. However, damage to the uterus prior to labour is usually in the uterine body while damage during labour is usually in the lower segment. One of the main predisposing factors for uterine rupture is the scarring of the uterus due to a previous surgery, namely caesarean sections [1]. A study conducted in 2005 by the World Health Organisation on the worldwide prevalence of uterine rupture resulted in a median of 0.053% [2]. At present, poor antenatal care, cephalopelvic disproportion, uterine scars and oxytocin administration are considered to be the most important etiopathogenetic factors [3]. Other risk factors to consider are congenital anomalies, age, multiparity and curettages (especially the ones complicated by perforation, fibrosis and/or adenomyosis). Very few cases of spontaneous uterine rupture in pregnant women without known risk factors have been reported in scientific literature [4].

### Case Report

We report a case of a 37 years old woman from Italy, at the second pregnancy, with a previous abort and a previous spontaneous birth, who gave birth vaginally at the thirty-ninth weeks gestation. The baby weighed 2970 grams at birth. After spontaneous delivery, the patient began to bleed and was subjected to curettage. Continuing blood loss, it was decided to make a subtotal hysterectomy. The piece

removed showed a breach in the left margin of the uterus. Histological examination showed in the uterine fundus the absence of decidua, thinning of the myometrium, utero-placental arteries thrombosed. This was the starting point of the break which extended up into the uterine margin during the expulsion of the foetus. After subtotal hysterectomy the patient had a normal postoperative course and now is in excellent health.

### Discussion

The peculiarity of this case report is that the uterine rupture was spontaneous and occurred in a patient with endometritis post-abortion.

The main causes of uterine rupture in pregnancy are related to obstetric anamnesis and / or the administration of oxytocin. The main obstetric anamnestic factors are represented by previous gynaecological operations on the uterus, previous caesarean sections, scraping due to abortions and their complications. During the course of pregnancy there are some factors that can cause spontaneous rupture of the uterus and silent during labour: foetal macrosomia and abnormal foetal presentation [5,6].

The patient in question did not present any of these diseases. She gave birth at term a fetus of 2970 gr. vertex presentation in the left front. It was the histological examination of the uterus that revealed a possible cause: the absence of decidua in the site of placenta implantation and thinning of the myometrium, which probably represented the "locus minoris resistentiae" which started a silent and, at first, incomplete breaking of the uterus, which then led to a full thickness tear, due to myometrial hematoma that was forming in the meantime.

May be the "locus minoris resistentiae" occurred for metritis post-abortion.

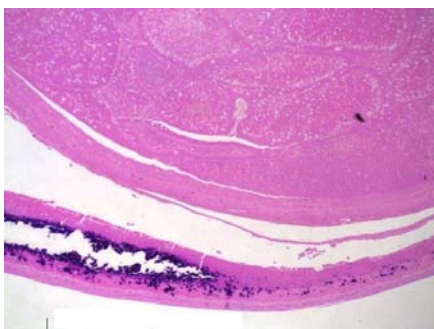


Figure 1: Uterus Rupture.

\*Corresponding author: Carlo Pafumi, MD, Department of Gynaecologic and Obstetrics, University of Catania, via p. metastasio 43 - 95127 - Catania, Italy, Tel: +390957435541; E-mail: [pafumi@unict.it](mailto:pafumi@unict.it)

Received January 03, 2012; Accepted April 04, 2012; Published April 06, 2012

Citation: Pafumi C, Leanza V, Carbonaro A, Stracquadanio M, Leanza G, et al. (2012) Spontaneous Uterus Rupture in the Post-partum. J Cell Sci Ther 3:123. doi:10.4172/2157-7013.1000123

Copyright: © 2012 Pafumi C, et al. This is an open-access article distributed under the terms of the Creative Commons Attribution License, which permits unrestricted use, distribution, and reproduction in any medium, provided the original author and source are credited.

---

### Acknowledgment

Valentina Pafumi has carried out English language editing for this article.

### References

1. Hofmeyr GJ, Say L, Gülmezoglu AM (2005) WHO systematic review of maternal mortality and morbidity: the prevalence of uterine rupture. *BJOG* 112: 1221-1228.
2. Walsh CA, O'Sullivan RJ, Foley ME (2006) Unexplained prelabor uterine rupture in a term primigravida. *Obstet Gynecol* 108: 725-727.
3. Nikolov A, Negentsov N, Maïnkhard K, Mekhandzhiev Ts (2007) Course of pregnancy and delivery in cases with cervical decidualosis. *Akush Ginekol (Sofia)* 46: 3-7.
4. Schinsky DC, Benson RC (1978) Rupture of the pregnant uterus: a review. *Obstet Gynecol Surv* 33: 217-232.
5. Oyelese Y, Ananth CV (2006) Placental abruption. *Obstet Gynecol* 108: 1005-1016.
6. Ananth CV, Getahun D, Peltier MR, Smulian JC (2006) Placental abruption in term and preterm gestations: evidence for heterogeneity in clinical pathways. *Obstet Gynecol* 107: 785-792.