

Small Bowel Injury after Penetrating Abdominal Trauma despite normal Pre-operative Computerised Tomography. A Case Report of a Successful Laparoscopic Repair

Ioannis Gerogiannis* and Giles Bond-Smith

Department of Emergency Surgery, John Radcliffe Hospital, Oxford University Hospitals NHS Foundation Trust, Oxford, UK

Abstract

Background: The surgical management of a patient with a penetrating injury can be challenging. We present a case of a patient with a small bowel injury after penetrating abdominal trauma and its successful management despite normal Computerised Tomography (CT).

Case and methods: A 39-year-old female, suffering from an anterior abdominal stab wound (AASW), was transferred to Accident and Emergency Department (A&E) after attempting to suicide with a knife.

During transfer and on arrival at A&E patient was haemodynamically stable. Primary survey (ABCDE) revealed no concerning findings and abdominal examination revealed a 3cm horizontal wound 4cm above umbilicus. Abdomen was soft, mildly tender. Resuscitation and basic investigations were performed according to ATLS principles. Decision was to proceed with CT scan of the abdomen and pelvis (CTAP). After CTAP, patient became hypotensive and was resuscitated with 1 unit of RBCs and tranexamic acid. CTAP showed no intraperitoneal injury with no free intraperitoneal gas or fluid. Patient was reviewed by surgeons and decision was to proceed with Diagnostic Laparoscopy.

Results: Laparoscopy revealed peritoneal penetration, abdominal muscle haematoma with haemorrhagic fluid in pelvis and sero-muscular tear of the proximal ileum. Sero-muscular tear was repaired laparoscopically with an uneventful post-operative period.

Conclusion: Detailed clinical examination and experienced surgeon with advanced laparoscopic skills can result to a successful management of stable patients with anterior abdominal stab wounds, faster recovery and avoidance of unnecessary CT scans and laparotomies.

Keywords: Bowel; Penetrating; Trauma; Injury; Tomography; Laparoscopy; Repair

Introduction

The management of a patient with a penetrating injury can always be challenging for every surgeon. Although imaging in Trauma Surgery has a significant role, there is always the possibility to miss an injury with a false negative result. Furthermore, the use of laparoscopy in trauma is always a hot topic in meetings with controversial opinions about why and when it can be used.

According to Advanced Trauma Life Support (ATLS) and Definitive Surgical Trauma Course (DSTC), a patient with trauma, should have a CT scan if he/she is haemodynamically stable based on the mechanism of injury [1,2]. A surgical exploration of the wound is a preferable option if there is doubt about the depth or peritoneal involvement post penetrating trauma [1,2].

We present a case report of a young lady who presented with a penetrating abdominal injury, after the primary survey and initial assessment, she had a CT scan abdomen pelvis who excluded peritoneal injury, but the laparoscopy revealed a traumatic small bowel injury. The injury was repaired laparoscopically.

Case and Methods

A 39-year-old female, suffering from an anterior abdominal stab wound, was transferred with an ambulance to A&E Department after attempting to suicide with a knife.

Patient reported having a fight with her boyfriend, after which she consumed 0.5 litres of vodka and stabbed herself in the abdomen. She said that it was a single stabbing with an antique knife.

Paramedics presented a photo of the knife and reported that,

according to the sign of fluid on its blade, it entered the abdomen 3-4 centimetres (Figure 1).

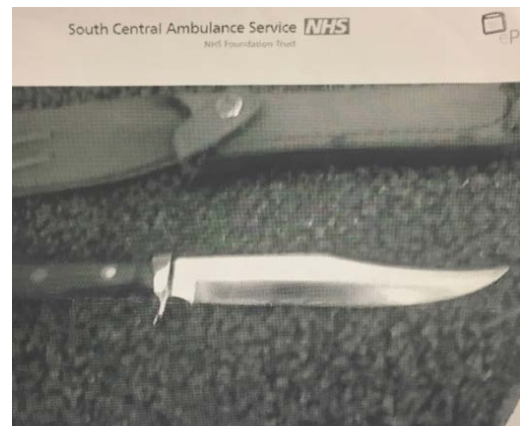


Figure 1: Photo of the knife that paramedics took from the scene.

*Corresponding author: Ioannis N Gerogiannis, Department of General Surgery, Kingston Hospital NHS Foundation Trust, Galsworthy Road, Kingston, KT2 7QB, UK, Tel: +44 7429 981412; E-mail: drgerogiannis@gmail.com

Received July 15, 2018; Accepted July 31, 2018; Published August 07, 2018

Citation: Gerogiannis I, Bond-Smith G (2018) Small Bowel Injury after Penetrating Abdominal Trauma despite normal Pre-operative Computerised Tomography. A Case Report of a Successful Laparoscopic Repair. *Emergency Med* 8: 375. doi:10.4172/2165-7548.1000375

Copyright: © 2018 Gerogiannis I, et al. This is an open-access article distributed under the terms of the Creative Commons Attribution License, which permits unrestricted use, distribution, and reproduction in any medium, provided the original author and source are credited.

During transfer and on arrival at A&E, patient was haemodynamically stable.

Primary survey according to the algorithm ABCDE of ATLS revealed:

A: Airway patent - patient was talking

B: Adequate Bilateral air entry, respiratory rate of 14/min, O₂ saturation in room air 97%

C: Blood Pressure: 110/72 mmHg Heart Rate (HR): 98 pulses per min (ppm) 2 litres of warm crystalloids were administered slowly through 2 large bore peripheral lines. Blood tests including Ethanol level and urine test including pregnancy test were sent just after arrival in A&E. Group and save and cross match of 6 units of Red Blood Cells (RBCs) were requested.

D: Glasgow Coma Scale of 15.

E: Core body Temperature was 36.2°C, Abdominal examination revealed a 3 cm horizontal wound on midline, 4 cm above umbilicus (Figure 2). Abdomen was soft with tenderness on palpation in lower abdomen. No other injuries.

After completing the primary survey and because patient was haemodynamically stable, A&E doctors decided to send her for Computerised Tomography scan of the abdomen and pelvis (CTAP).

Blood test results: Haemoglobin (Hgb): 132 g/L, White blood cell count: $3.82 \times 10^9/L$, Platelet count: $341 \times 10^9/L$, K⁺ 3.4 mmol/L, Albumin: 29 g/L, Ethanol: 66.1 mmol/L, rest of the results including coagulation were normal.

Patient was transferred to the CT scanner where CTAP was performed and then returned back to A&E waiting for the report. While patient was in A&E, she became haemodynamically unstable with BP: 86/43 mmHg and HR:100 ppm. Resuscitation was performed according to the ATLS principles; 1 unit of RBCs with immediate positive result to patient's haemodynamic status. Tranexamic acid was also administered as Hgb was found 126 g/L after the drop of blood pressure, indicating a possible haemorrhage. After resuscitation, patient's BP remained stable at 98/68 mmHg and HR was 95 ppm.

CTAP showed no intraperitoneal injury with no free intraperitoneal gas or fluid and no active contrast extravasation.

Patient was reviewed by Surgeons after the CT scan report and the resuscitation. Decision was made to proceed with Diagnostic Laparoscopy. The decision was based on the 3 reasons below: 1. The mechanism of injury. The report of the depth of the knife's penetration by the paramedics led to a high suspicion of an intrabdominal injury even if clinically patient was not peritonitic.

2. The incident of sudden drop of blood pressure and the drop of Hgb after transferring the patient to the CT scanner meant either that there was an intrabdominal bleeding or a rectus sheath haematoma from the penetrating injury.

3. Surgeons were trained in Trauma surgery and their judgement was also based on empirical knowledge on penetrating trauma cases.

Laparoscopy was performed in an emergency setting. It revealed peritoneal penetration, abdominal muscle haematoma with haemorrhagic fluid in peritoneal cavity and sero-muscular tear of the proximal ileum (Figures 3-6).

The small bowel injury was repaired laparoscopically (Figure 7).

Washout of the abdominal cavity with 3 litres of warm normal saline was performed. Careful observation of the whole small bowel and rest of intrabdominal organs was performed laparoscopically and other injury was excluded.

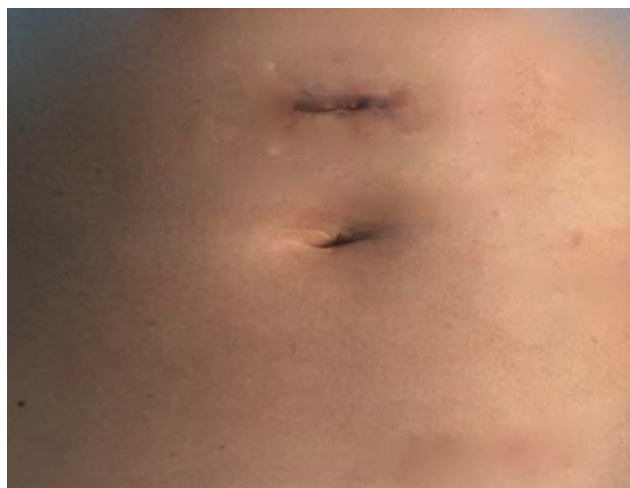

Figure 2: Stab wound.

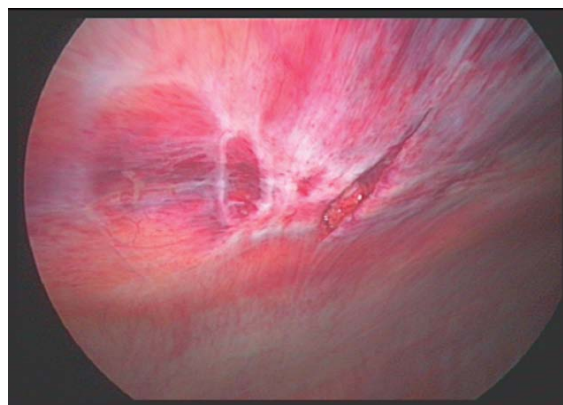


Figure 3: Laparoscopy: penetration of the peritoneal cavity and rectus abdominis muscle haematoma.

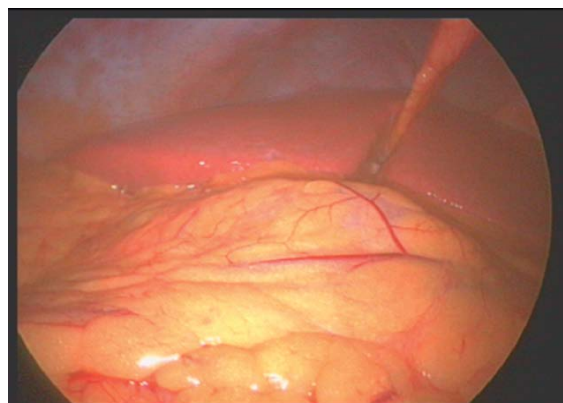


Figure 4: Laparoscopy: no obvious liver or solid organ damage.

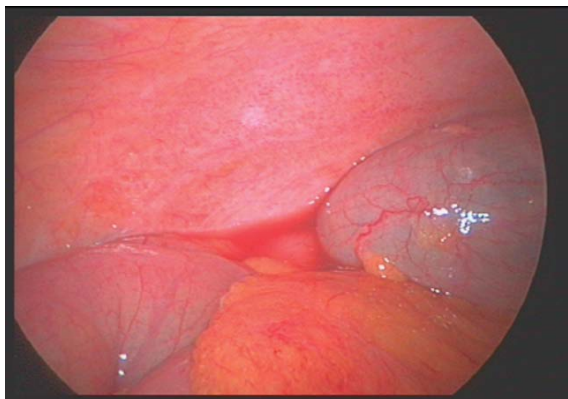


Figure 5: Laparoscopy: small amount of haemorrhagic fluid - Right paracolic area.

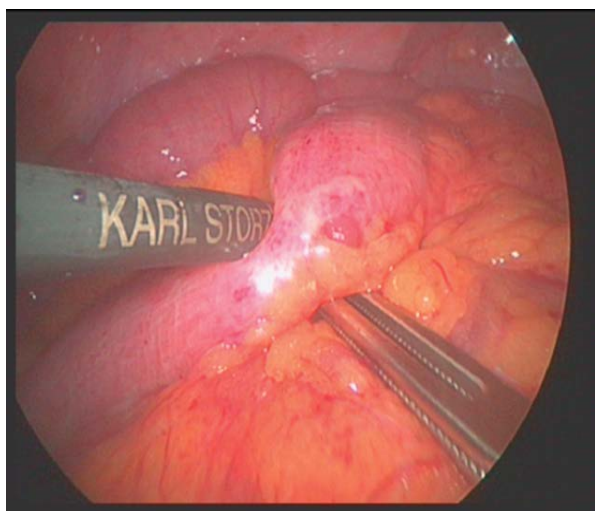


Figure 6: Laparoscopy: seromuscular tear of the proximal ileum

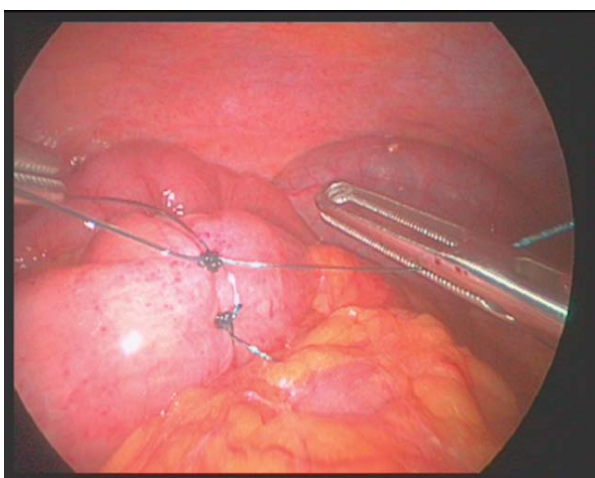


Figure 7: Laparoscopic repair of the serosal tear of the bowel in one layer with interrupted 3-0 prolene sutures.

Patient had an uneventful post-operative period and she was discharged the second post-operative day.

Discussion

CT scan is an adjunct of the secondary survey, if patient is stable [1,2]. Of course, there are some other adjuncts that could be used during the primary survey such as Focused Assessment with Sonography in Trauma (FAST) which replaced the Diagnostic Peritoneal Lavage (DPL) [1].

Local wound exploration is not universally accepted because it is an invasive, often mis-leading tool and not reliable especially in obese trauma patients [3].

Use of CT scan in AASW is controversial as studies present it as a tool for visceral injuries' identification but others as unreliable in detection of bowel injury [3,4].

Salim et al. in their prospective study characterize CT as a promising tool that may identify patients with anterior abdominal stab wounds who can be discharged after a shorter period of observation [3].

In the other hand, Inaba et al. in their study stated that CT did not improve the diagnostic yield or shorten the time to diagnosis and resulted in an increase in nontherapeutic laparotomies [4]. CT was not able to facilitate earlier discharge and did not improve overall clinical outcomes [4].

Diagnostic laparoscopy has also been proposed as a useful adjunct in penetrating trauma in hemodynamically stable patients or those responsive to initial resuscitation [5,6]. It can be used to identify peritoneal penetration, hemoperitoneum, and solid organ injury providing all benefits of minimal invasive surgery including nontherapeutic laparotomy [5,6].

We believe that laparoscopy is an accepted sensitive approach in stable patient with anterior abdominal stab wound. In our case it is shown that a negative CT abdomen pelvis cannot exclude intrabdominal injuries, leading to undiagnosed small bowel injury.

Finally, it is important to mention that all of the adjuncts cannot replace the clinical examination and of course the judgement and decision making of an experienced emergency surgeon.

Conclusion

Detailed clinical examination and experienced surgeon with advanced laparoscopic skills can result to a successful management of stable patients with anterior abdominal stab wounds, faster recovery and avoidance of unnecessary CT scans and laparotomies.

Authors' Contributions

All authors were involved in the writing of the manuscript.

Compliance with Ethical Standards

Conflict of interest

The authors declare that they have no conflict of interest.

Ethical Approval

All procedures performed in studies involving human participants were in accordance with the ethical standards of the institutional and/or national research committee and with the 1964 Helsinki Declaration and its later amendments or comparable ethical standards.

Informed Consent

Informed consent was obtained by all individual participants included in the study. Full verbal and written informed consent have been obtained from the patients for submission of this manuscript for publication.

Funding Sources or Institutional or Corporate Affiliations

None.

References

1. Advanced Trauma Life Support (ATLS) (2018) Student Course Manual. 10th Edition. American College of Surgeons.
2. Boffard KD (2015) Manual of Definitive Surgical Trauma Course (DSTC). Fourth Edition, CRC Press.
3. Salim A, Sangthong B, Martin M, Brown C, Plurad D, et al. (2006) Use of computed tomography in anterior abdominal stab wounds: results of a prospective study. *Arch Surg* 141: 745-750.
4. Inaba K, Okoye OT, Rosenheck R, Melo N, Branco BC, et al. (2013) Prospective evaluation of the role of computed tomography in the assessment of abdominal stab wounds. *JAMA Surg* 148: 810-816.
5. Matsevych OY, Koto MZ, Motilall SR, Kumar N (2016) The role of laparoscopy in management of stable patients with penetrating abdominal trauma and organ evisceration. *J Trauma Acute Care Surg* 81: 307-311.
6. Koto MZ, Matsevych OY, Motilall SR (2015) The Role of Laparoscopy in Penetrating Abdominal Trauma: Our Initial Experience. *J Laparoendosc Adv Surg Tech A* 25: 730-736.