

## Simultaneous Presentation of Three Ureteric Stones in Three Different Ureters in A Patient with Unilateral Ureteric Duplication, An Unlucky Rare Triad!

Elsawi Osman<sup>1\*</sup>, Ziauddin Khan<sup>2</sup> and Tanweer Bhatti<sup>2</sup>

<sup>1</sup>Urology Department, King Fahd Specialist Hospital, Dammam, Saudi Arabia

<sup>2</sup>Urology Department, King Hamad University Hospital, Dammam, Saudi Arabia

\*Corresponding author: Elsawi Osman, Urology Department, King Fahd Specialist Hospital, Dammam, Saudi Arabia, Tel: +0097335335909; E-mail: sawi11@hotmail.com

Rec date: April 22, 2016; Acc date: June 7, 2016; Pub date: June 15, 2016

Copyright: © 2016 Osman E. This is an open-access article distributed under the terms of the Creative Commons Attribution License, which permits unrestricted use, distribution, and reproduction in any medium, provided the original author and source are credited.

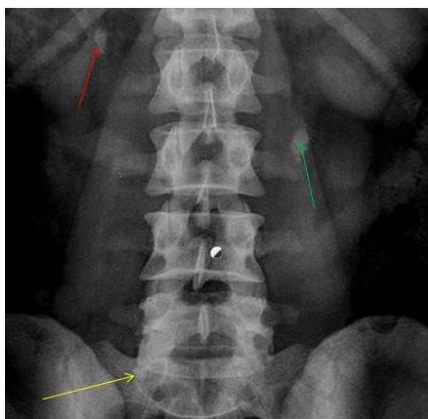
### Abstract

Urinary tract duplication anomalies have a variety of anatomical and clinical manifestations. In broad terms, duplication anomalies are divided into complete and incomplete (partial). We are hereby reporting a case of a 26 year- old man, who presented acutely with right sided loin pain. Subsequent investigations showed right sided complete duplication with a single left ureter, with all three ureters harboring obstructing stones. He underwent urgent bilateral semi-rigid ureteroscopy with LASER lithotripsy with satisfactory outcome. There are no similar case reports in the English literature to the best of our knowledge.

**Keywords** Lithotripsy; Urinary tract diverticula; Ureteric duplication

### Case

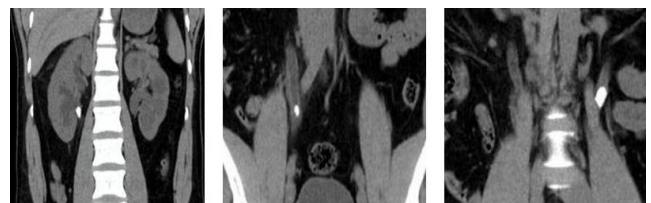A 26-year-old man with no co-morbidities, presented with severe right loin pain. There is no associated lower urinary tract symptoms, fever or decreased urine output. Physical examination was unremarkable. His laboratory investigations showed microscopic haematuria with sterile pyuria. His renal function test, serum calcium and uric acid were all within normal limits.



**Figure 1:** Plain X-Ray KUB, showing all three calculi. The red arrow pointing to the calculus in the upper third of the right inferior moiety ureter, the yellow arrow pointing to the calculus in the mid third of the right superior moiety ureter, while the green arrow is pointing to the calculus in the upper third of the left single ureter.

Plain spiral Computerized Tomography scan (CT scan) of the abdomen and pelvis, showed a duplex system of the right kidney with 1.5 × 0.8 cm calculus in the upper third of the inferior moiety ureter.

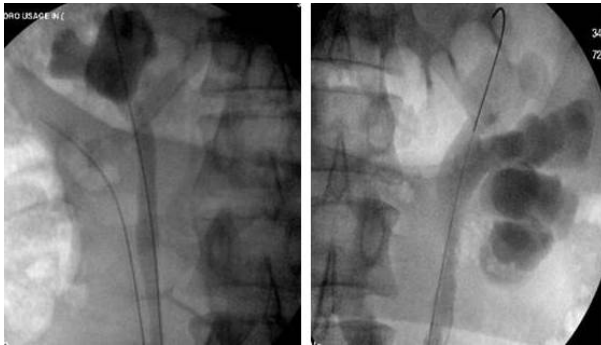Another calculus measuring 1 × 0.6 cm was seen in the mid third of the upper moiety ureter. On the left side there was a single ureter with a 1.7 × 0.9 cm calculus in its upper third along with a 5 mm × 3 mm lower calyceal stone. All ureteric calculi (Figures 1 and 2) were obstructing with at least grade III proximal hydro-ureteronephrosis and mild to moderate perinephric fat stranding.



**Figure 2:** Plain Spiral CT scan images. Left: A calculus in the upper third of the right inferior moiety ureter. Middle: A calculus in the mid third of the right superior moiety ureter. Right: A calculus in the upper third of the left single ureter.

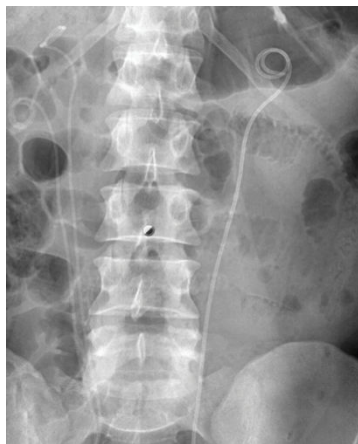He was admitted and adequately prepared for urgent intervention. Intra-operatively, the left ureter was intubated first and retrograde pyelogram was performed (Figure 3), followed by ureteroscopy using 4.5-6.5 F semi-rigid ureteroscope with one working 3F channel (Richard Wolf - Germany).

Lithotripsy using Holmium LASER 365 Micron fibre was done. The stone was partially fragmented and a double J stent was inserted. In the right side, retrograde pyelography showed a partial duplex with a very short distal confluence of both ureters measuring around two to three centimetres. Ureteroscopy was carried out in both limbs of the duplex right ureter.



**Figure 3:** Intra-operative retrograde pyelogram showing the patient's upper urinary tract anatomy bilaterally.

The stone in the mid third of the upper moiety ureter was completely disintegrated using LASER, however the stone in the upper third of the lower moiety was pushed back and both ureters were stented. Three weeks later, the patient underwent cystoscopy with removal of all three stents along with repeat bilateral ureteroscopy. This revealed some residual fragments on the left side requiring LASER lithotripsy and replacement of the stent, due to the severe impaction and oedema some minor mucosal abrasions. While on the right side both limbs did not have any significant residual fragments. To this effect, the patient was discharged after satisfactory post-operative recovery with a view of right lower moiety ESWL as well as full 24 hours' urine in six weeks time for metabolic work up. The stone in the lower calyx of the left kidney will be kept under observation (Figure 4).



**Figure 4:** Post operative plain X-ray KUB, showing no significant residual fragments bilaterally with satisfactory position of all three stents.

## Discussion

Postmortem studies have shown some degree of upper urinary tract duplication in around 0.8% [1]. The percentage was rather higher at around (2-3%) in patients undergoing intravenous urography (IVU) for various indications. In approximately 40% of cases the condition is

bilateral. The anomaly is transmitted as an autosomal dominant trait with incomplete penetrance, so that among members of affected families the incidence is in the order of 8% [2]. Complete duplication anomalies are far rarer than partial, affecting appreciably less than 0.1% of individuals, the majority being females. It is mandatory to be aware of Weigerts – Meyer's law when dealing with any duplication anomaly [3,4]. This states that the upper moiety ureter in a complete duplex opens inferio-medial to the lower moiety ureter. Currently, there is no evidence to suggest that duplication anomalies per se predispose to a higher risk of calculus formation. Nevertheless, it is a widely accepted principle that management of calculi in a Duplex system should have a special consideration Aikena et al. [5] who reported a case of bilateral duplex with ureteric calculi involving both ureters on the same side, highlighted the anatomical fact of the common adventitial sheath within which the outer musculature of both ureters intermingle. Moreover, they advised against performing active ureteral dilation with a balloon or fascial dilators. Alternatively, they were in favour of passive dilatation by ureteric stenting followed by a definitive Stone disintegration procedure. Compared to previously published reports [5-7], our case was even rarer, being three obstructed ureters simultaneously and involving both sides, making it the first report of its kind in the English literature to the best of our knowledge. Secondly immediate ureteroscopy with the successful removal of stones from one of the duplex limbs as well as the contra-lateral ureter was performed in one sitting using 4.5Fr ureteroscope without the need for any Ureteric opening dilatation.

A key point to highlight is keeping the possibility of ureteric duplication anomalies in mind especially in cases where no stones were found during ureteroscopy, despite the presence of stones in the immediate pre-op imaging. Retrograde contrast studies are advisable prior to ureteroscopy. If a partial or complete duplication is encountered; a guide wire should be placed in one orifice so that finding of the second ureteric orifice is easier.

## Conclusion

Ureteroscopy with lithotripsy can safely be performed in any of the ureters within a duplex system without prior stenting.

## References

1. Dinanath P, Ashwini A, Annarao G, Nagaraj S (2011) Bilateral complete duplex renal pelvis and ureters- a case report. *International Journal of Anatomical Variations* 4: 192-194.
2. Thomas D, Duffy PG, Rickwood AMK (2008) *Essentials of Paediatric Urology* pp: 93-105.
3. Weigert C (1877) About some malformations of the ureters *Virchow Archives for pathological anatomy and physiology and for clinical medicine*, Berlin 70: 490.
4. Meyer (1907) The anatomy and evolutionary history of Ureter *Virchow Archives for pathological anatomy and physiology and for clinical medicine*, Berlin 87: 40.
5. Aiken WD, Johnson PB, Mayhew RG (2015) Bilateral complete ureteral duplication with calculi obstructing both limbs of left double ureter. *Int J Surg Case Rep* 6C: 23-25.
6. Megremis S, Chatziioannou M, Tritou I (2010) Simultaneous obstruction of both limbs of a bifid ureter by calculi: sonographic evaluation. *J Ultrasound Med* 29: 145-147.
7. Karakose A, Aydogdu O, Atesci YZ (2013) Unilateral complete ureteral duplication with distal ureteral stone: A rare entity. *Can Urol Assoc J* 7: E511-512.