

Significant Therapeutic Effect of Acupuncture on Intractable Dermatophytosis

Shao-jun Wang*, Si-ting Li and Ye-hui Yin

Institute of Acupuncture and Moxibustion, China Academy of Chinese Medical Sciences, Beijing 100700, China

*Corresponding author Shao-jun Wang, Institute of Acupuncture and Moxibustion, China Academy of Chinese Medical Sciences, Beijing 100700, China, Tel: 0086-010-64089293; E-mail: ddwsj5@sina.com

Received date: February 15, 2017; Accepted date: February 22, 2017; Published date: February 27, 2017

Copyright: © 2017 Wang SJ, et al. This is an open-access article distributed under the terms of the Creative Commons Attribution License, which permits unrestricted use, distribution, and reproduction in any medium, provided the original author and source are credited.

Abstract

Objective: To observe the clinical efficacy of acupuncture on intractable dermatophytosis so as to provide the new approach to the treatment of dermatophytosis.

Method: The fire needling and body acupuncture were used in combination. The main points were selected from the local lesions and the fire needling technique with multiple stimulation and shallow puncture was used on the skin lesions.

Supplementary points: (1) Selection along the meridians: The He-sea points of the related meridians with the skin lesion involved were added. (2) Selection according to the syndrome differentiation.

The therapeutic efficacy was evaluated according to the scores of symptoms and physical signs as well as infrared thermogram and laser speckle blood flow imaging techniques.

Results: After 24-time treatments, the curative rate was 45.16% and the remarkably effective rate was 48.39% in intractable tinea corporis and cruris (TCC); the curative rate of tinea manus and pedis (TMP) was 38.89% and the remarkably effective rate was 50%. It deserves noticing that acupuncture achieved the apparent effect on dermatophytosis, which is irreplaceable by the other therapies.

Conclusion: Acupuncture is the considerably effective method in treatment of dermatophytosis.

Keywords: Acupuncture; Fire needle; Tinea manus and pedis (TMP); Tinea corporis and cruris (TCC)

Introduction

Dermatophytes is the main pathogenic bacteria of superficial fungal disease in the human and animal, generally invading skin, hair and nails, parasitically or saprophytically dwelled in epidermal cutin, hair and keratin and inducing tinea capitis, TCC, TMP, tinea unguium. Dermatophytosis is the skin infection by fungi feeding on keratin, including trichophyta, microsporum and epidermophyton [1,2]. It is common and frequent in occurrence, widely spread and infectious and mainly manifested as itching, red skin, scaly skin and thickening of horny layer. The fungal microscopic examination and cultivation indicate positive [3]. In addition, there are particular symptoms according to the affected areas involved. For example, the local blisters and oozing are commonly combined at the early stage of TMP. These symptoms usually happen or get worse in summer and early fall, alleviate or are stable in winter. The pigmentations present after healing.

For that at the early stage or with smaller skin lesion, the lesion may be self-healed after strict sterilization, good rest and improvements of working and living conditions. For the cases of long duration or repeated attacks, the western medicine has definite effect and is the common therapy in clinic practice [4,5]. But due to the toxic side effects and drug resistance, the western medicine may lead to apparent side effects or relapse tendency [6,7].

Although achieving certain efficacy on dermatophytosis, the therapeutic period of Chinese medicines is quite long. Up to now, there are few reports on acupuncture treatment for dermatophytosis. The authors had found by clinical observation that the therapeutic effect of acupuncture on dermatophytosis should not be ignored. The treatment of 67 cases of intractable dermatophytosis with acupuncture in terms of the affected meridians and syndrome differentiation is reported as follows.

Methods

Subjects

Outpatients from department of dermatology, diagnosed based on a structured clinical interview for diagnostic criteria of dermatophytosis were randomly recruited and visited regularly. In reference to the complete medical history and physical examination, the participants were otherwise healthy. All of the 132 patients were from Hospital of Acupuncture and Moxibustion, China Academy of Chinese Medical Science and enrolled from September 2014 to January 2016. Informed consent was obtained from all participants. Study was performed in accordance with the Declaration of Helsinki and was approved by the Medical Ethics Committee of Institute of Acupuncture and Moxibustion, China Academy of Chinese Medical Sciences.

Clinical measures

TMP, TCC were diagnosed according to clinical symptoms and fungi microscopic examination by the experienced dermatologists. There were 68 cases of TMP (treatment group: n=36, controlled group: n=32) and 64 cases of TCC (treatment group: n=31, controlled group: n=33). Of the subjects, there were 62 males and 70 females, aged from 10 to 75 years, averagely 39.14 ± 9.12 years. The duration of sickness was ranged from 0.5 years to 30 years, averagely 6.23 ± 7.61 years. All of the enrolled patients had not been treated with antifungal topical in the previous 2 weeks and had not taken systematically antifungal medicines. Based on the clinical symptoms and fungal microscopic examination, TMP and TCC were diagnosed and caused by dermatophytes. Exclusive criteria: Patients with any of the following conditions will be excluded: (1) having received fungal cultivation and having determined the causative fungi (no skin tinea bacteria involved), (2) receiving systematical treatment or using antifungal topical.

Therapeutic effect index

Scoring criteria: The clinical manifestations before and after treatment were scored in reference to visual analogue scale (VAS) [8-11] and the score of each symptom and total scores were calculated. According to the degree of each symptom, from the (1) Local itching: 0 for absence of itching, 1 for occasional itching, 2 for attack due to improper diet or overstrain, 3 for intermittent attack, 4 for frequent attack, 5 for severe itching and sleeping disturbance (2) Regarding red patches, blister, thickening of horny layer and scaly skin: 0 for absence of red patches/blister/thickening of horny layer/scaly skin; 1 for the lesion area of red patches/blister/thickening of horny layer/scaly skin less than or equal to 2 cm^2 , or reduced by $\geq 80\%$ as compared with that before treatment; 2 for the lesion area of red patches/blister/thickening of horny layer/scaly skin larger than 2 cm^2 but less than or equal to 4 cm^2 , or reduced by $\geq 60\%$ as compared with those before treatment; 3 for the lesion area of red patches/blister/thickening of horny layer/scaly skin larger than 4 cm^2 but less than or equal to 6 cm^2 or reduced by $\geq 40\%$ as compared with those before treatment; 4 for the lesion area of red patches/blister/thickening of horny layer/scaly skin larger than 6 cm^2 but less than or equal to 8 cm^2 or reduced by $\geq 20\%$ as compared with those before treatment; 5 for the lesion area of red patches/blister/thickening of horny layer/scaly skin larger than 8 cm^2 or reduced by $<10\%$ as compared with those before treatment. Every patient was treated for 24 times and was scored before treatment, after 6, 12 and 24 times of treatment as well as 1 month after treatment at different stages separately.

Infrared thermogram and laser speckle blood flow analysis

Infrared thermal imaging apparatus (Vario SCAN 3021-ST, made in Germany) and laser speckle blood flow apparatus (Devon EX135HU, made in England) were used for infrared thermal imaging and speckle blood flow determination at the lesions before and after treatment in the patients of dermatophytosis at the constant room temperature 24°C . Separately, the statistical analysis was done on the area with higher infrared thermal imaging value (red patches), the highest infrared thermal imaging value (the difference between the local lesion temperature and the normal skin surface temperature), the area with the high perfusion blood flow value (red patches) and the highest speckle blood flow value (the difference between the high perfusion value of local lesion and the perfusion value of normal skin) before and

after treatment. The changes were compared before and after treatment.

Acupuncture treatment

Fire needling therapy and body acupuncture were adopted in combination. The acupoint prescription was composed of the main points and the supplementary points. The main points were from the local skin lesions and stimulated with fire needling of shallow puncture (each skin lesion for 2~5 times). Fire-needle was applied by stainless steel needles (0.75mm in diameter) at a depth of 0.3 mm into the local skin lesions after the tip of the needle burned red then quickly removed. For the supplementary points: (1) On the affected meridians: the He-sea points of the affected meridians (electro-acupuncture); (2) Based on syndrome differentiation: Shuidao (ST28), Guilai (ST29), Yinlingquan (SP9) and Sanyinjiao (SP6) for spleen deficiency and damp excess; Xuehai (SP10), Sanyinjiao (SP6) and Geshu (BL17) for yin and blood deficiency; Jianyu (LI15), Quchi (LI11), Waiguan (TE5), Fengshi (BL31) and Xuehai (SP10) for blood deficiency and wind dryness; Ganshu (BL18), Xuehai (SP10), Hegu (LI4) and Taichong (LR3) for liver qi stagnation and blood insufficiency [12-15]. All of the points were selected bilaterally. The treatment was given twice a week. The electric stimulation with an EA apparatus#SDZ-II, Suzhou Medical Supplies Factory Co. Ltd. China) with a constant rectangular current of alternating trains of dense-sparse frequency (2/100Hz, pulse width, 0.2-0.6msec) was applied to the supplementary points, 2 to 4 pairs of points each time. The needling manipulating intensity was determined on the response of patients' tolerance (1.0-2.0mA). The even needling technique was adopted and the needles were retained for 30 min.

Clinical outcomes

Cured: basic disappearance of itching, skin lesion, blisters, thickening of horny layer and scaly skin (general symptoms), the scores reduced by $\geq 90\%$; remarkably effective: apparent improvements in the general symptoms, the scores reduced by $\geq 60\%$, but $<90\%$; effective: basic disappearance of general symptoms or improvements, but still unstable condition, the scores reduced by $\geq 20\%$, but $<60\%$; failed: no apparent improvements in the general symptoms, the scores reduced by $<20\%$.

Statistical analysis

All data are presented as mean \pm SEM. One-way analyses of variance (ANOVA) for repeated-measures as appropriate were performed using GraphPad Prism (Avenida de la Playa La Jolla California). $p < 0.05$ indicated significant difference. Least significant ranges (LSR0.05) were adopted after ANOVA.

Results

Apparent improvements in the symptoms in the patients of dermatophytosis after acupuncture treatment

The statistical analysis on the clinical symptoms scores at different stages in the treatment was described in Table 1, and the statistical analysis on the general scores in treatment and controlled group was described in Figure 1. The results showed that the symptoms were relieved apparently after 24 treatments, such as itching, red patches,

blisters, thickening of horny layer and scaly skin in TCC and TMP in treatment group.

Table 1 showed: in the patients of TCC, itching was apparently relieved after 3 weeks (6-time treatments) ($P < 0.01$), the score of itching was reduced stably after 6 weeks (12-time treatments), 12 weeks (24-time treatments) and 16 weeks (4 weeks after the end of treatment).

The differences were extremely significant in the symptom scores after 24-time treatments (12 weeks) and 4 week after the end of treatment (16 weeks) as compared with those in 0 week (before treatment) ($P < 0.001$). Red patches, thickening of horny layer and scaly skin were relieved or were not so apparent after 3 weeks (6-time treatments) and 6 weeks (12-time treatments).

	n	Symptom	0 week (before)	3 week (6-time)	6 week (12-time)	12 week (24-time)	16 week (follow-up visit)
Tinea corporis and cruris	31	Local Itching	3.97 ± 0.91	1.48 ± 0.68**	0.94 ± 0.36**	0.55 ± 0.62***	0.23 ± 0.50***
		Red Patches	4.29 ± 0.82	3.16 ± 0.90	1.77 ± 0.50**	0.61 ± 0.67***	0.45 ± 0.57***
		Blister	-	-	-	-	-
		Horny Layer Thickening	3.29 ± 0.69	3.26 ± 0.51	2.42 ± 0.62*	1.23 ± 0.50***	0.77 ± 0.72***
		Scaly Skin	3.13 ± 0.85	2.97 ± 0.80	2.10 ± 0.54	0.77 ± 0.85**	0.55 ± 0.77**
Tinea manus and pedis	36	Local Itching	3.92 ± 0.69	2.00 ± 1.01**	1.08 ± 1.05**	0.56 ± 0.74***	0.50 ± 0.61***
		Red Patches	2.92 ± 0.81	2.50 ± 0.70	2.44 ± 0.74	0.72 ± 0.78***	0.61 ± 0.65***
		Blister	1.53 ± 1.20	0.92 ± 1.05	0.72 ± 1.00	0.28 ± 0.52*	0.14 ± 0.35***
		Horny Layer Thickening	3.89 ± 0.98	3.78 ± 1.05	3.33 ± 0.93	1.31 ± 0.67***	0.86 ± 0.72***
		Scaly Skin	3.69 ± 0.79	3.31 ± 0.86	2.83 ± 1.21	0.86 ± 0.68**	0.58 ± 0.65***

Table 1: The scores of the symptoms and physical signs in the cases of tinea corporis, cruris and tinea manus and pedis in every stage. The symptoms and physical signs were relieved apparently, but the improvement extent and sequence were different. Itching was firstly relieved after 6-time treatments (3 weeks), and then the plateau phase appeared which was considered as the accumulative acupuncture effect. But after 24-time treatments (12 weeks), all the symptoms and physical signs were relieved obviously. * $p < 0.05$ ** $p < 0.01$ *** $p < 0.001$ (versus 0w).

Specially, the severity of thickening of horny layer was slightly increased in tendency. But, after 12 weeks (24-time treatments), red patches, thickening of horny layer and scaly skin were all relieved obviously ($P < 0.01$). The general tendency in TMP was similar to TCC, except that blister score was getting reduced slowly and the difference was significant after 12 weeks (24-time treatments) as compared with that in 0 week (before treatment) 15 ($P < 0.05$).

Figure 1 showed: the scores of general symptoms in TCC in treatment group were reduced significantly after 3 weeks (6-time treatments), indicating the significant difference as compared with those in 0 week (before treatment) ($P < 0.05$); and the differences in the score reducing were not significant in comparison between 6 weeks (12-time treatments) and 3 weeks (6-time treatments). It was considered that the treatment from 3 to 6 weeks achieved the accumulative acupuncture effect. As compared with the results of 6 weeks (12-time treatments), the results of 12 weeks (24-time treatments) were reduced significantly ($P < 0.05$). In follow-up visit in the 4th week after the treatment discontinuity, it was found the score of the general symptoms was still reduced in tendency as compared with that in 12 weeks (24-time treatments), but without significant difference ($P > 0.05$). As compared with the controlled group, the differences at the last four time points were all significant statistically. The change tendency in TMP was similar to that of TCC.

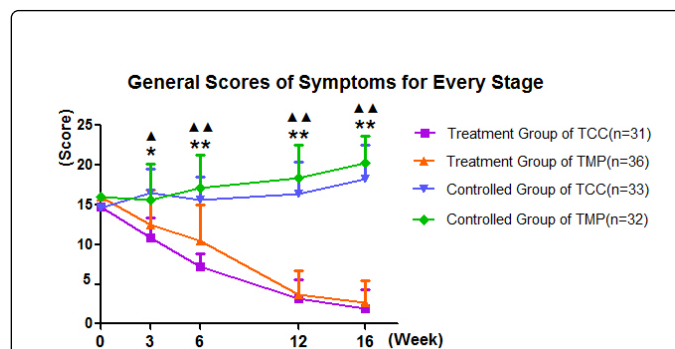


Figure 1: General scores of symptoms for every stage. The total scores of symptoms in TCC were reduced significantly after 3 weeks (6-time treatments), 6 weeks (12-time treatment) and 12 weeks (24-time treatment). In follow-up visit in the 4th week after the treatment discontinuity, it was found the score of symptoms was still reduced in tendency. The change tendency in TMP was similar to that of TCC. As compared with the controlled group, the differences at the last four time points were all significant statistically. * $p < 0.05$ ** $p < 0.01$ (treatment group versus controlled group of TCC at the same time), $p < 0.05$ $p < 0.01$ (treatment group versus controlled group of TMP in same time).

Analysis on infrared thermogram and laser speckle blood flow before and after treatment

Figure 2 and Figure 3 illustrated the representative cases of infrared thermogram and laser speckle blood flow before and after treatment of TCC and TMP. The patient in Figure 2 had the disease 3 years ago, without apparent inducing factor, manifested as sudden itching on the retroauricular areas, skin redness after scratching, followed by scaly skin and rough skin (Figure 2A1). The fungal cultivation showed that it was caused by dermatophytes. After subjective application of halometasone cream, itching was relieved temporarily, but the symptoms reoccurred and horny layer was thickening. Half a year later, itching and scaly skin presented in the external genitalia region and on the lateral side of the thigh. No effect was achieved after many treatments. In April 2015, the patient visited the Dermatology Department of the Hospital. The infrared thermogram showed that the area of high infrared thermogram was 8cm² (Figure 2A2). The highest temperature of the local lesion was different from the normal skin by 0.93°C; The speckle blood flow showed the maximal flow (FLUX) area was 7.4 cm² (Figure 2A3), and the value was different from the normal skin by 240PU. The western medicine diagnosed it as TCC and TCM as round tinea.

After 24-time treatments, skin color was close to be normal, the scores of clinical symptoms and physical signs were reduced apparently (Figure 2B1). The infrared thermogram showed that the infrared thermal imaging area in the retroauricular regions was shortened to be 3.2 cm² from 8 cm² (Figure 2B2). The temperature difference was 0.43°C between the local highest infrared thermogram and the normal skin. The speckle blood flow determination showed that the blood perfusion value in the retroauricular region was basically recovered to be normal (Figure 2B2), being different by 2.1PU as compared with the normal skin. The case was not recurred in follow-up visit 1 month later.

Figure 2C illustrated the statistical analysis on the area of high infrared thermogram, the highest infrared thermal imaging value (Figure 2C2), the higher speckle blood flow area (Figure 2C3) and the highest speckle blood flow value (Figure 2C4) in the skin lesions before and after treatment in the patients of TCC. The results indicated: after acupuncture treatment, the high infrared thermal imaging area in the skin lesions was reduced ($P < 0.01$), the highest infrared thermal imaging value was down-regulated ($P < 0.001$), the area of high speckle blood flow was shortened apparently ($P < 0.001$) and the highest speckle blood flow value was reduced ($P < 0.001$).

The patient in Figure 3 suffered from skin rashes on the dorsum of feet and hands 6 years ago without apparent inducing factors, manifested as itching, scattering blisters, skin redness after scratching, combined with oozing (Figure 3A1). The fungal cultivation showed that it was caused by dermatophytes. After subjective application of terbinafine hydrochloride cream, the rashes were relieved. But since then, skin rashes got worse in every spring and fall. The patient visited Dermatology Department of Hospital in May 2015. Physical examination: ovary skin lesions on the dorsal and palmar sides of feet and hands, 5 × 8 cm² in the biggest lesion, with white scaly skin and red patches presenting after the skin surface scraped. The area of the high infrared thermogram was 60 cm² (Figure 3A2). The highest temperature of the local lesion was different from the normal skin by 1.03°C. The speckle blood flow showed the maximal flow (FLUX) area was 56 cm² (Figure 3A3) and value was different from the normal skin by 221PU. The Western medicine diagnosed it TMP and TCM as foot dampness.

After 24 treatments, the scaly skin was getting thinner and desquamation basically disappeared (Figure 3B1).

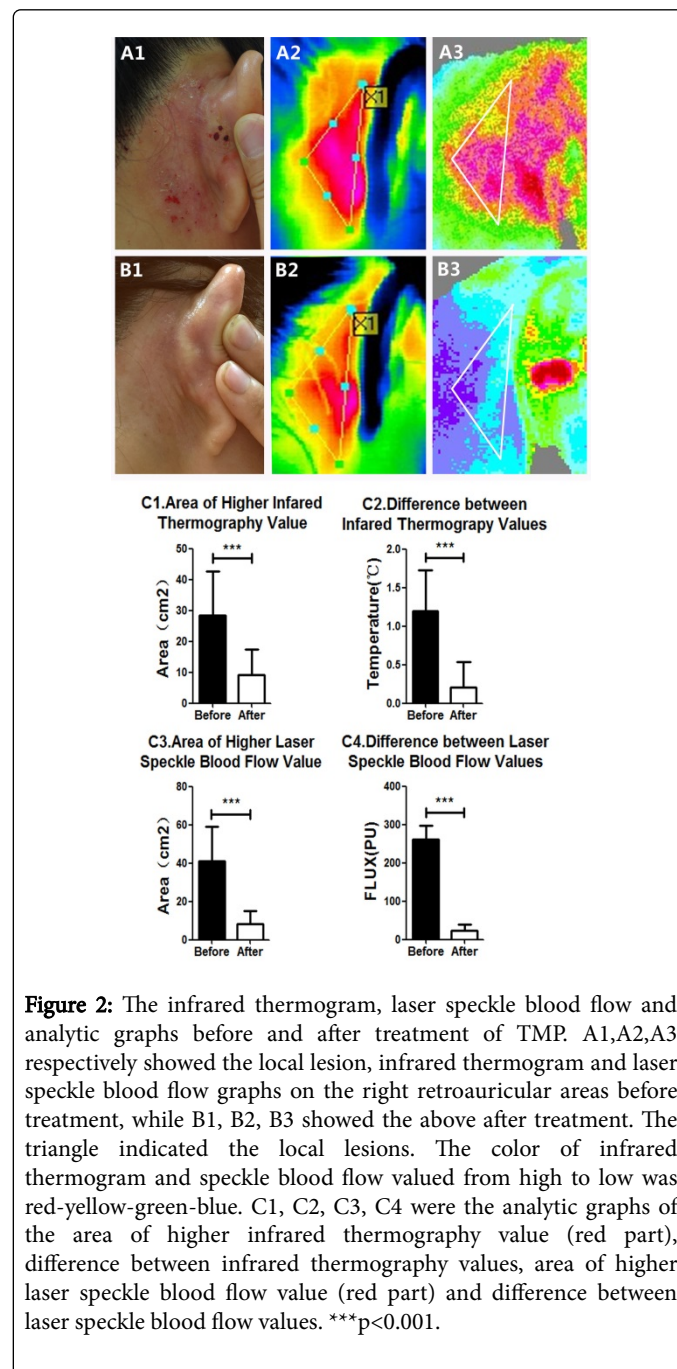


Figure 2: The infrared thermogram, laser speckle blood flow and analytic graphs before and after treatment of TMP. A1,A2,A3 respectively showed the local lesion, infrared thermogram and laser speckle blood flow graphs on the right retroauricular areas before treatment, while B1, B2, B3 showed the above after treatment. The triangle indicated the local lesions. The color of infrared thermogram and speckle blood flow valued from high to low was red-yellow-green-blue. C1, C2, C3, C4 were the analytic graphs of the area of higher infrared thermography value (red part), difference between infrared thermography values, area of higher laser speckle blood flow value (red part) and difference between laser speckle blood flow values. ***p<0.001.

The infrared thermogram showed that the infrared thermal imaging area in the retroauricular regions was shortened to be 6 cm² from 60 cm² (Figure 3B2). The temperature difference was 0.36 between the local highest infrared thermal imaging and the normal skin. The speckle blood flow imaging area was shortened to be 8 cm² from 56 cm² (Figure 3B3) and the value was different by 62PU as compared with the normal skin. The case was recovered to be normal basically in follow-up visit 1 month later.

Figure 3C illustrated the statistical analysis on the area of high infrared thermal image (Figure 3C1), the highest infrared thermal

imaging value (Figure 3C2), the high speckle blood flow area (Figure 3C3) and the highest speckle blood flow value (Figure 3C4) in the skin lesions before and after treatment in the patients of TMP. The results were similar to Figure 2C.

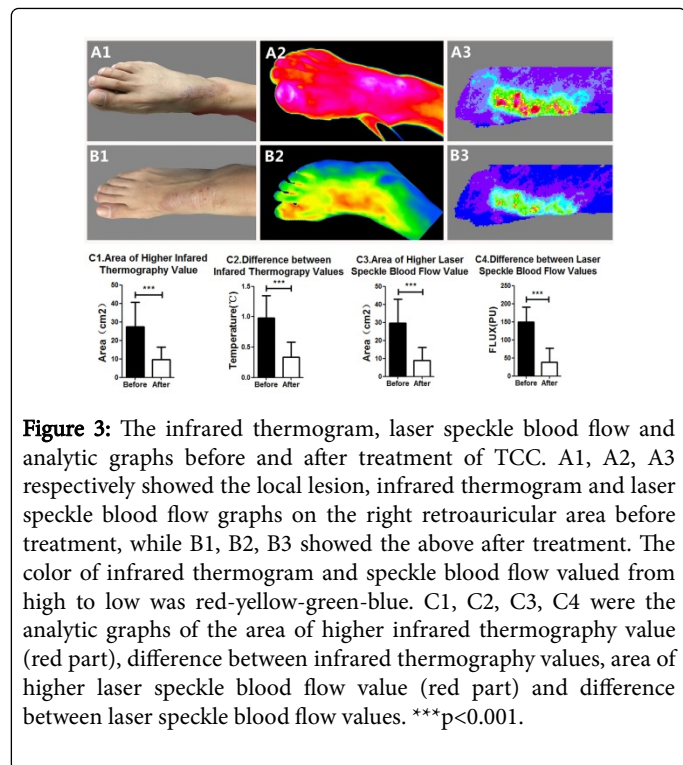


Figure 3: The infrared thermogram, laser speckle blood flow and analytic graphs before and after treatment of TCC. A1, A2, A3 respectively showed the local lesion, infrared thermogram and laser speckle blood flow graphs on the right retroauricular area before treatment, while B1, B2, B3 showed the above after treatment. The color of infrared thermogram and speckle blood flow valued from high to low was red-yellow-green-blue. C1, C2, C3, C4 were the analytic graphs of the area of higher infrared thermography value (red part), difference between infrared thermography values, area of higher laser speckle blood flow value (red part) and difference between laser speckle blood flow values. ***p<0.001.

Evaluation of clinical efficacy after acupuncture treatment

Table 2 indicated the evaluation of the clinical efficacy on TCC, and TMP after 24 acupuncture treatments. The results showed that the curative rate was 45.16% and the remarkably effective rate was 48.39% in the treatment of intractable TCC. The curative rate was 38.89% and the remarkably effective rate was 50% in the treatment of TMP after 24 acupuncture treatments. The total curative rate was 41.79% and the total remarkably effective rate was 49.25%.

	n	Curative (%)	Remarkably Effective (%)	Effective (%)
Tinea corporis and cruris	31	14(45.16)	15 (48.39)	2 (6.45)
Tinea manus and pedis	36	14 (38.89)	18 (50)	4 (11.11)
Total	67	28 (41.79)	33 (49.25)	6 (8.96)

Table 2: The evaluation of the clinical efficacy on tinea corporis and cruris, and tinea manus and pedis after 24 acupuncture treatments. The results showed that the curative rate was 45.16% and the remarkably effective rate was 48.39% in the treatment of intractable tinea corporis and cruris. The curative rate was 38.89% and the remarkably effective rate was 50% in the treatment of tinea pedis and manus after 24 acupuncture treatments. The total curative rate was 41.79% and the total remarkably effective rate was 49.25%.

Discussion

Dermatophytosis is the infection of the skin and subcutaneous keratin caused by filamentous fungi. TCM believes that the interaction of damp, heat, insect and toxin in the skin is the key pathogenesis of this disease [16]. The living condition and fungal infection are the external factors of dermatophytosis. The dysfunction of zangfu organs, accumulation of pathogens in the body and declining of body immunity and defending function are the internal causative factors of it [17-20].

It is recorded in Suwen (plain questions of huangdi's internal classic) that the strong antipathogenic qi prevents from the invasion of pathogens, and the pathogens must invade body when in the condition of weakness of antipathogenic qi. Antipathogenic qi refers to the normal functional activity of the human body, the adaptability of the body to the external environment, the disease resistance ability, rehabilitation ability and the self-capacity for physiological balance.

In the study, with acupuncture at the points along the affected meridians and on the basis of syndrome differentiation, the impacts on the symptoms and the persistent time of improvement of this disease were observed. The results showed that acupuncture relieved the symptoms and physical signs of intractable TCC, and TMP and the efficacy in follow-up visit was remarkable.

Lingshu Hailunpian recorded that the twelve meridians connect to zangfu organ internally and reach to skin, muscle, tendon and bone externally. In the treatment, the He-sea points and the local points were selected along the affected meridians on the basis of the distribution of skin lesions. The increase of infrared thermal imaging value and blood perfusion value in the local skin lesion were caused by the poor blood circulation and heat formation due to the long term blood stagnation. Fire needling in the local area contributed to blood circulation and accelerate metabolism in the skin lesions so as to promote the absorption of secretions or desquamation [21]. He-sea points are the sites where the meridian qi is deeply located, infusing to the places of Zangfu organs. Acupuncture at the corresponding meridians strengthens the qi of the affected meridians, which is as the bridge between the exterior to the interior, meaning the treatment of the interior for the disorder of the exterior. The supplementary points selected according to the syndrome differentiation act on the treatment of the primary and the secondary to improve the efficacy. Additionally, the local stimulation of acupuncture was particularly for the disorder caused by the skin and subcutaneous keratin infection and had achieved the unique efficacy on dermatophytosis.

The study indicated that the combination of fire needling and acupuncture along the affected meridians and based on the syndrome differentiation is a non-medicinal therapeutic scheme. It is not only treating local skin lesions, but also importantly improves the body internal conditions via meridians and differentiation. As a result, the intractable dermatophytosis is treated with definite efficacy and low recurrence rate. Additionally, this therapy avoids the adverse reactions and sequela induced by a large number of drugs. Hence, this therapeutic scheme deserves to be promoted in clinical application.

In the coming study, we are going to observe the changes in the body immune related factors, T-cells and the pathological structure on the skin lesion surface along with the improvements in the symptoms and physical signs of dermatophytosis treated with acupuncture. Finally, we try to further explain the biological mechanisms of acupuncture in the treatment of dermatophytosis.

Conclusions

Fire needling therapy and body acupuncture used in combination is considerably effective method in treatment of dermatophytosis.

Acknowledgement

Si-ting Li and Shao-jun Wang contributed equally to this study. Shao-jun Wang conceived the whole procedure of the study, clinical treatment, and prepared the manuscript. Si-ting Li assisted treatment and conducted the statistical analysis. Ye-hui Yin carried out the experiment. All authors discussed and approved the final paper.

This scientific work was supported by grant from National Natural Science Foundation of China (81373724) to Shao-jun Wang.

Competing Interests

The authors declared that they have no competing interests.

References

1. Panthagani AP, Tidman MJ (2015) Diagnosis directs treatment in fungal infections of the skin. *Practitioner* 259: 225-229.
2. van Zuuren EJ, Fedorowicz Z, El-Gohary M (2015) Evidence-based topical treatments for tinea cruris and tinea corporis: a summary of a Cochrane systematic review. *Br J Dermatol* 172: 616-641.
3. Zhang XJ (2014) *Pi Fu Xing Bing Xue Gao Ji Jiao Cheng*. People's Military Medical Press, Bei Jing.
4. Ely JW, Rosenfeld S, Seabury Stone M (2014) Diagnosis and management of tinea infections. *Am Fam Physician* 90: 702-710.
5. Li RY, Wang AP, Xu JH, Xi LY, Fu MH, et al. (2014) Efficacy and safety of 1% terbinafine film-forming solution in Chinese patients with tinea pedis: a randomized, double-blind, placebo-controlled, multicenter, parallel-group study. *Clin Drug Investig* 34: 223-230.
6. Yang LH (2015) Comparison of clinical efficacy of terbinafine hydrochloride cream and miconazole nitrate cream in treatment of dermatophyte infections. *Lab Med Clin* 12: 1416-1417.
7. Gupta AK, Lyons DC (2015) The rise and fall of oral Ketoconazole. *J Cutan Med Surg* 19: 352-357.
8. Hanley EN, Ode G, Jackson Iii BJ, Seymour R (2016) Coccygectomy for patients with chronic coccydynia: a prospective, observational study of 98 patients. *Bone Joint J* 98: 526-533.
9. Mehta N, Bucior I, Bujanover S, Shah R, Gulati A (2016) Relationship between pain relief, reduction in pain-associated sleep interference, and overall impression of improvement in patients with postherpetic neuralgia treated with extended-release gabapentin. *Health Qual Life Outcomes* 14: 54.
10. Zhang B, Qu TB, Pan J, Wang ZW, Zhang XD, et al. (2016) Open patellar tendon tenotomy and debridement combined with suture-bridging double-row technique for severe patellar tendinopathy. *Orthop Surg* 8: 51-59.
11. Sansone M, Ahldén M, Jonasson P, Thomeé C, Swärd L, et al. (2015) Outcome of hip arthroscopy in patients with mild to moderate osteoarthritis-A prospective study. *J Hip Preserv Surg* 3: 61-67.
12. Zheng HH, Fu TM (2016) A randomized parallel controlled study of acupuncture, moxibustion combined with Traditional Chinese Medicine internal and external use in the treatment of chronic eczema divided by syndrome differentiation. *J Prac Trad Chin Inter Med* 30: 92-95.
13. Wang YD, Liu ZC, Xu B (2014) Efficacy observation of acupuncture and tapping therapy in the treatment of type 2 diabetes of yin deficiency pattern combined with stasis in the patients. *Zhongguo Zhen Jiu* 34: 731-735.
14. Ding LW, Wang CH, Nie JD (2014) Clinical observation on treating Xuexu Fengzao type neurodermatitis by acupuncture therapy and TCM medicine. *Clin J Chin Med* 26: 43-44.
15. Xu L, Zhang Y (2015) Black Xiaoyao Poeder combined with acupuncture in treatment 35 patients suffering from menstrual headache of liver depression and blood vacuity. *China Heal Stand Manag* 23: 149-151.
16. Li WJ, Lin Y (2015) Treatment determination on tinea in orthodox manual of external diseases. *Guiding J Traditional Chinese Med Pharma* 21: 4-6.
17. Dahl MV (1993) Suppression of immunity and inflammation by products produced by dermatophytes. *J Am Acad Dermatol* 28: S19-S23.
18. Blake JSI, Dahl MV, Herron MJ, Nelson RD, et al. (1991) An immunoinhibitory cell wall glycoprotein (mannan) from *Trichophyton rubrum*. *J Invest Dermatol* 96: 657-661.
19. Cabrera RM, Blake JS, Dahl MV (1991) Inhibition of keratinocyte proliferation by a mannan glycoprotein isolated from *Trichophyton rubrum*. *J Invest Dermatol* 96: 616.
20. Grando SA, Hostager BS, Herron MJ, Dahl MV, Nelson RD (1992) Binding of *Trichophyton rubrum* mannan to human monocytes in vitro. *J Invest Dermatol* 98: 876-880.
21. Guo XL, Wang M, Hu Z (2016) Study on the mechanisms of fire needle therapy. *Guangming J Chinese Med* 31: 683-685.