

## Significance of Synthetic Typing for Hypospadias Intraoperative

Zhang shilin\*, Liu Guoqing, Wang Jianfeng, Tang Huajian, Li Jierong, Chen Yiping and Huang Zhenqiang

Foshan Maternal and Child Health Care Hospital, Southern Medical University, China

### Abstract

**Objective:** To introduce a kind of method of hypospadias comprehensive typing, approach correlation of the characteristic of urethra plate growth and the operation method choice for hypospadias repair,

**Methods:** 180 patients suffering of hypospadias were assessed in accordance with the classification of hypospadias orifice and urethral plate and chose their methods of operation accordingly, among which 89 patients accept Tubularized Incised Plate Plasty (TIP), 48 patients accept Mathieu plasty, 36 patients accept Onlay plasty and 7 patients accept Koyanagi plasty.

**Result:** In the 180 cases, the total occurrence rate of urethral fistula was 5.56% (10/180), the occurrence rate of urethral stricture was 3.89% (7/180), the cure rate of one stage operation was 90.56% (163/180), the reoccurrence rate of clubbed penis was 4.44% (8/180), the occurrence rate of poor development of penis was 2.22% (4/180), the occurrence rate of poor appearance of penis was 2.78% (5/180), with overall satisfaction rate was 90.56% (163/180). 12.78% (23/180) of the patients required two stage operation. There was no significant difference on the cure rate of one stage operation among different operation methods chosen ( $p > 0.01$ ). The cure rate in patients with one stage operation from the <6 months group was better than that from the >6 months group ( $p < 0.01$ ).

**Conclusion:** According to the characteristic of urethral plate and the classification of hypospadias orifice to make synthetic typing to hypospadias can elevate surgical operation success rate.

**Keywords:** Hypospadias; Urethral plate; Synthetic typing; Complication

### Introduction

Hypospadias is the most common congenital hypoplasia of the penis, with displacement of the urethral opening along the ventral surface, often associated with dorsal hooded foreskin and chordee. The incidence of hypospadias of newly-born male infants has been estimated to be 0.4/1000-8.2/1000 [1]. In some cases of proximal hypospadias, the severe forms of hypospadias may have a urethral meatus located at the scrotum or perineum with existing problems such as poor development of penis, combined with serious clubbed penis deformation [2]. However, due to the severity of these abnormalities and the great differences of development of tissue of urethral plate in hypospadias, proximal hypospadias often requires more extensive reconstruction in order to achieve an anatomically and functionally successful result. The mono-operation method could not satisfy the demands of operative treatments for all types of hypospadias. Therefore, we designed a kind of method of hypospadias comprehensive typing and reported the effects and complications of the operations in 180 males with congenital hypospadias who received the operations from January 2005 to December 2009.

### Materials and Methods

#### Case presentations

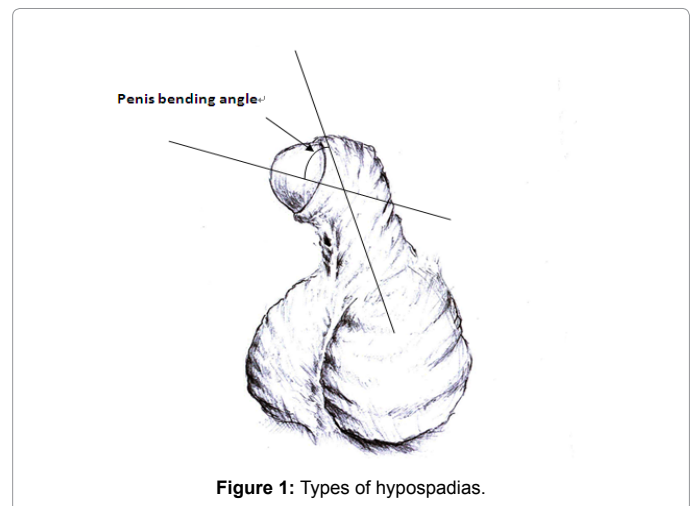
Written informed consent was obtained from all the individuals who participated in the study or their parents, and the protocol was approved by the ethics committee of Foshan Maternal and Child Health Care Hospital, Southern Medical University.

180 male Chinese patients with congenital hypospadias, recruited from the urology of the hospital of Foshan maternal and child health care hospital, southern medical university, were evaluated. Criteria for the diagnosis of congenital hypospadias included clinical signs and symptoms of hypospadias. There were no any others anomalies in these patients. Aged from 3 days to five years old, and the average operation ages were 6.4 months. The ranges of lengths of penis were 18-31 mm, and the average lengths of penis were 25.08 mm. The ranges of girths

about coronary sulcus of penis were 29-41 mm, and the average girths of coronary sulcus of penis were 36.44 mm.

### Classification of hypospadias

To classify hypospadias into six types in accordance with the hypospadias orifice before correction of clubbed penis as follows (Figure 1): type I (glans penis, coronary sulcus), type IIa (anterior 2/3 of corpus



\*Corresponding author: Zhang shilin, Foshan Maternal and Child Health Care Hospital Southern Medical University, Foshan, Guangdong, China, Tel: 86-0757-829699; E-mail: zhang\_40\_1@163.com

Received December 27, 2013; Accepted February 26, 2014; Published March 03, 2014

Citation: Shilin Z, Guoqing L, Jianfeng W, Huajian T, Jierong L, et al. (2014) Significance of Synthetic Typing for Hypospadias Intraoperative. Med Surg Urol 3: 129. doi:10.4172/2168-9857.1000129

Copyright: © 2014 Shilin Z, et al. This is an open-access article distributed under the terms of the Creative Commons Attribution License, which permits unrestricted use, distribution, and reproduction in any medium, provided the original author and source are credited.

penis), type IIb (posterior 1/3 of corpus penis), type III (penis and scrotum), type IV (scrotum) and type V (perineum).

The clubbed penis was classified into three grades on the basis of the included angle between the body of penis and the bending of penis [3]: low-grade for less than 15 degree, medium-grade for 15-30 degree, and high-grade for over 30 degree. In the practical work, we made an appropriate change for this classification and the bending of penis body was classified into three levels according to the penis bending angle: level 1: penis bending angle less than 30 degree; level 2: bending angle between 30-45 degree; level 3, bending angle over 45 degree.

The shapes of urethral plates were classified into three groups in accordance with the width of urethral plate as some researches [4]. Group A: width of urethral plate over 8 mm, with visible urethral groove. Group B: width of urethral plate over 8 mm, with flat urethral plate; Group C: width of urethral less than 8 mm. Among the 180 cases, there were 31 cases in group A, 97 cases in group B and 52 cases in group C.

### Operation method selection

All cases were classified, graded and grouped before operation, and to measure bending angle through the establishment of the artificial erection after the introduction of general anaesthesia. The method to estimate the bending angle or curvature was to draw a straight line on the cardboard and mark a dot in the line. The penis axis aligned with the straight line and the roots of the buckling penis head aligned with the dot, and to mark point on the board corresponding to the position of the centre of the penis head. Connecting two points on the board and measure the angles of intersecting lines as in Figure 2 and Supplementary Figure 1A and 1B. There were four operation methods for selecting: Tubularized Incised Plate Urethroplasty (TIP), Mathieu urethroplasty, Onlay urethroplasty and Koyanagi urethroplasty (Supplementary Figure 1C and 1D). All cases were classified, graded and grouped before operation. The proper operation method was chosen in accordance with the result of assessment as follows: 1) Chosen TIP method for cases of hypospadias under type I, IIa, IIb and III, with penis bending angle less than 45 degree and width of urethral plate over 8 mm, and hypospadias under type IV/V, with penis bending angle less than 30 degree and width of urethral plate over than 8 mm; 2) Chosen Mathieu method for cases of hypospadias under type I, with penis bending angle over 45 degree or width of urethral plate less than 8 mm, and hypospadias under type IIa, with penis bending angle less than 45 degree or width of urethral plate less than 8mm; 3) Chosen Onlay method for cases of hypospadias under type IIa, with penis bending angle over 45 degree, and hypospadias under type IIb, with

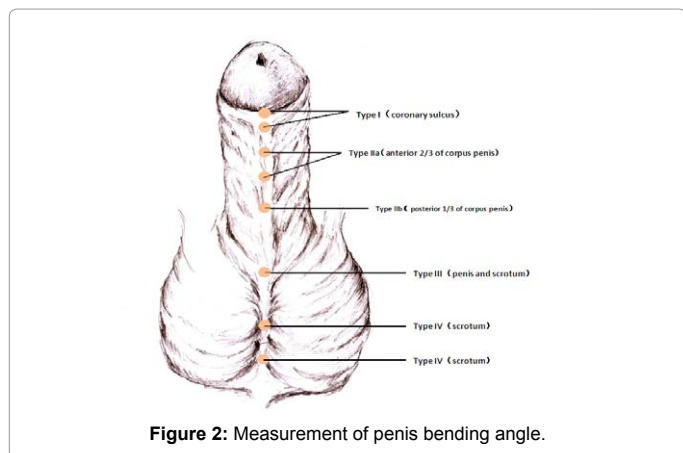


Figure 2: Measurement of penis bending angle.

OM	UF	US	OR (%)	SP	PD	PA	OS (%)
TIP (89)	5	3	91.01	4	2	2	89.89
MT(48)	2	2	91.66	2	1	1	91.67
OL (36)	2	2	88.89	2	0	1	89.12
KN (7)	1	0	85.71	0	1	1	71.43
Total(180)	10	7		8	4	5	
%	5.56	3.89	90.56	4.44	2.22	2.78	90.56

**Abbreviations:** OM: Operation Method; : MT: Mathieu; OL: Onlay; KN: Koyanagi; %: Percentage; UF: Urethral Fistula; US: Urethral Stricture; OR: One-Stage Cure Rate; SP: Secondary Clubbed Penis; PD: Poor Development; PA: Poor Appearance; OS: Overall Satisfaction

Table 1: Result of hypospadias operation (based on the analysis on operation method).

OA	UF	US	OR (%)	SP	PD	PA	OS (%)
<1 m (24)	1	1	91.67	1	0	1	91.67
1-6 m (60)	2	2	93.33	2	1	1	93.33
7-12 m (52)	4	2	88.46	3	2	1	88.46
>12 m(44)	3	2	88.64	2	1	2	88.64
Total (180)	10	7		8	4	5	
%	5.56	3.89	90.56	4.44	2.22	2.78	90.56

**Abbreviations:** OA: Operation Age; M : Month;% : Percentage; UF: Urethral Fistula; US: Urethral Stricture;OR: One-Stage Cure Rate; SCP: Secondary Clubbed Penis; PD: Poor Development; PA: Poor Appearance; OS: Overall Satisfaction

Table 2: Result of hypospadias operation (based on the analysis on operation age).

penis bending angle over 45 degree or width of urethral plate less than 8mm, and hypospadias under type III, with penis bending angle less than 45 degree and width of urethral plate less than 8 mm; 4) Chosen Koyanagi method for cases of hypospadias under type III, with penis bending angle over 45 degree, and hypospadias under type IV/V, with penis bending angle over 30 degree or width of urethral plate less than 8 mm.

### Results

All patients were used urethral catheter for a week and were followed up for 3-5 years after operation; with an average follow-up of 4.4 years. The results of hypospadias operation based on operation age or operation method were as follows (Tables 1 and 2):

These groups were homogenous. There were no any difference statistically in each other groups in terms of the same procedures, Statistics on the classification of hypospadias and clubbed penis in the these cases were shown in supplementary Tables 1 and 2. Among the 180 cases of hypospadias, there were 35 cases (19.44%) of distal hypospadias (type I), 84 cases (46.67%) of penis type (type IIa and IIb), 61 cases (33.89%) of proximal hypospadias (type III, IV and V); the number of patients with penis bending angle of 30-45 degree (level 2) made up 54.44% (98/180) of the total, the bending angle less than 30 degree (level 1) made up 30.00% (54/180) and the bending angle over 45 degree (level 3) makes up 15.56% (28/180); urethral plate with width over 8 mm (type A and B) made up 71.11% (128/180), including those with visible urethral groove (type A, 17.22%) (31/180). The urethral plate with width less than 8 mm (type C) makes up 28.89% (52/180). 89 cases were chosen Snodgrass (TIP) method, 48 cases were chosen Mathieu method, 36 cases were chosen Onlay method and 7 cases were chosen Koyanagi method. All cases were followed up for 3-5 years after operation, with an average follow-up of 4.4 years. In the 180 cases, the proportion of the total urethral fistula was 5.56% (10/180), the urethral structure was 3.89% (7/180); one-stage cure rate was 90.56% (163/180), and the two-stage operation was 12.78% (23/180). According to the analysis on different operation methods, there is no significant difference among the cure rate of one-stage operation. The cure rates

of one-stage operation of Snodgrass, Mathieu, Onlay and Koyanagi groups were 91.01% (81/89), 91.66% (44/48), 88.89% (32/36) and 85.71% (6/7) respectively. For the operation effect of age, the groups less than 6 months were better than that of groups over 6 months. The cure rates of one-stage operation of age groups among age groups less than 6 months and age groups over than 6 months were 92.86% and 88.14% respectively.

The satisfaction degree of distal hypospadias patients was higher than that of proximal hypospadias patients ( $p>0.01$ ). There was no significant difference on the cure rate of one stage operation among different operation methods chosen ( $p>0.01$ ). The cure rate in patients with one stage operation from the <6 months group was better than that from the >6 months group ( $p<0.01$ ). The SPSS16 software was used for statistical analysis.

## Discussion

The traditional classification of hypospadias was based on the displacement of the urethral opening along the ventral surface, cases have anterior hypospadias, with a small displacement of the meatus in the glandular region or patients have more substantial displacements, with middle (penile) or posterior (penoscrotal, scrotal and perineal) openings. Without considering the effect of surgical repair by the penis curve or the development of urethral plate of hypospadias, it has a fewer guidelines for the surgical choice [4-7]. According to the reports, the rate of success of operation for hypospadias is closely related to the repair length of urethra and the bending angle of penis [4]. We had found that the cognition of operations to the morphological and histological characteristics of urethral plate, the classification of hypospadias and the degree of clubbed penis were closely related to the selection of operation method, implied that the selection of a proper operation method was the key to increase the success rate of surgery. In the past, some operators were more concerned about the operation skills instead the overall analysis on hypospadias for the selection of operation method, which may become one of reasons for the low rate of success of operation for hypospadias, especially from those operators lacking of experience.

As the re-cognition of tissue of urethral plate, the urethroplasty with preservation of urethral plate has been become a popular operation method for hypospadias. The operation method has been developed a new direction for the operative treatment of hypospadias, making the therapy for hypospadias easier and more effective. Some researchers adopt TIP method to cure 496 cases of congenital hypospadias and follow up the cases for two years averagely after operation [5], finding out that the occurrence rate of urethral fistula and urethral stricture were 5% respectively, with a better operation result than others. It implied that TIP was applicable to operative treatment for most hypospadias cases, emphasizing that the experience of operator and proper technical improvement may effectively increase the cure rate of operation. The advantages of the method were to provide an excellent functional new urethra with beautiful appearance and rare complications. According to the studies of Mosharafa et al. [7], the width of urethral plate has close relationship with the cure rate of TIP Supplementary Figure 1C. If the rebuilt urethra is less than 8F, it means that the urethral groove of urethral plate will be superficial, narrow and lacking of elasticity and the occurrence rate of post-operation complication such as urethral fistula and urethral stricture will be higher than other with rebuilt urethra over 10F. According to the reports of Sarhan et al. [8], patients with urethral plate over 8mm who choose TIP can obviously increase the rate of success of operation, indicating that in the operative treatment for hypospadias, the cognition of operators to the morphological

and histological characteristics of urethral plate and the selection of operation method have significant meanings to the increase of rate of success of operation. Some researchers found that grafted the raw area of the urethral plate with inner preputial skin in children with primary hypospadias during TIP improved the results of the operation which resulted in a significantly smaller number of unsatisfactory results, and particularly fewer cases of neourethral stenosis [9]. However, urethrocutaneous fistula is one of the most common complications of hypospadias surgery. Management of persistent urethrocutaneous fistula is challenging because it is complicated by a lack of or poor quality of tissues at the site of repair [10]. Although the optimal period recommended for repair was about 6-15 months of age, we found for the operation effect of age, the groups less than 6 months were better than that of groups over 6 months. We know the repair of hypospadias as early as possible will help achieve a psychologically healthy body image. Some authors found that there was a clear association between age and production of pro-inflammatory cytokines by genitourinary fibroblasts, and may explain the greater risk of complications following repair in older boys [11]. In addition, our research found that on the premise of the anesthetic safety, hypospadias repairing operation is feasible in some selective cases in neonate [12]. As the major operation method for hypospadias with preservation of urethral plate, the TIP method is applicable to the therapy of most distal hypospadias and few proximal hypospadias [8]. We found that the correction effect of the Mathieu method for clubbed penis in coronary sulcus type hypospadias (type I/IIa) with clubbed penis was better than that of TIP method, and the Onlay method may be used as a supplement to TIP method in the operative repair for Hypospadias (type II/III) with clubbed penis over 45 degree or width of urethral plate less than 8 mm. The operation effect of Koyanagi method was similar to operation by stages, indicating that as severe clubbed penis was found in most proximal hypospadias cases, the major technique to correct clubbed penis was to completely release the lateral fibrous belt of penis body. For proximal hypospadias required one-stage operative repair, Koyanagi method is recommended. The selection of operation for hypospadias at a lower age may increase the cure rate of one-stage operation. It is shown in our research that the classification and grading and assessment method of the morphological and histological characteristics of urethral plate simplify the assessment procedures of hypospadias, reduces the cognition difficulties on the morphological and histological characteristics of urethral plate. It enhances the reasonability of selection of operation method and increases the cure rate of operation for hypospadias, and we proposed to widely introduce it in clinical application.

The operation for hypospadias is still under the explosion and development process [13]. The current cure standard for hypospadias is not only satisfactory sexual quality and urination at erect position but also satisfactory appearance. As TIP method could not solve the problem of most operative repair for distal hypospadias, Duckett, Koyanagi and other operations for hypospadias by stages still occupy an important position in operations for proximal hypospadias. Some research had shown that despite the numerous techniques used for hypospadias surgery, the incidence of complications is still high in patients who undergo hypospadias repair [14]. Either the application of the dorsal midline placcation or the penis ventral elongation to correct the deformation of clubbed penis, further observation and studies are required for their therapeutic effect (Supplementary Figure 1E, 1F). The morphological and histological characteristics of urethral plate have been close relationship with the selection of operation method for hypospadias. The selection of proper operation method based on the

assessment on the classification, grouping and grading concerning the morphological and histological characteristics of urethral plate, which could effectively overcome the insufficient knowledge of operators on the morphological and histological characteristics of urethral plate and the deficiency caused by improper selection of operation method, and increase the cure rate of operation for hypospadias.

#### Reference

1. Leung AK, Robson WL (2007) Hypospadias: an update. *Asian J Androl* 9: 16-22.
2. Stokowski LA (2004) Hypospadias in the neonate. *Adv Neonatal Care* 4: 206-215.
3. Wein AJ, Kavoussi LR, Novick AC, Partin AW, Peters CA (2012) *Campbell-Walsh Urology*. (10th edn), W.B. Saunders, Philadelphia P 3486-3452.
4. Sarhan O, Saad M, Helmy T, Hafez A (2009) Effect of Suturing Technique and Urethral Plate Characteristics on Complication Rate Following Hypospadias Repair: A Prospective Randomized Study. *J Urol* 182: 682-685; discussion 685-686.
5. Akbiyik F, Tiryaki T, Senel E, Mambet E, Livanelioglu Z, et al. (2009) Clinical experience in hypospadias: results of tubularized incised plate in 496 patients. *Urology* 73: 1255-1257.
6. Al-Ghorairy BA, Elashry OM, Al-Housain AE, Mattar AA (2009) Analysis of five-year experience with tubularized incised plate urethroplasty for anterior and mid penile hypospadias. *Eur J Pediatr Surg* 19: 90-95.
7. Mosharafa AA, Agbo-Panzo D, Priso R, Aubry E, Besson R (2009) [Repair of hypospadias: the effect of urethral plate configuration on the outcome of Duplay-Snodgrass repair]. *Prog Urol* 19: 507-510.
8. Wallis MC, Braga L, Khoury A (2008) The role of flaps and grafts in modern hypospadiology. *Indian J Urol* 24: 200-205.
9. Mouravas V, Filippopoulos A2, Sfoungaris D2 (2013) Urethral plate grafting improves the results of tubularized incised plate urethroplasty in primary hypospadias. *J Pediatr Urol*.
10. Springer A, Subramaniam R (2012) Preliminary experience with the use of acellular collagen matrix in redo surgery for urethrocutaneous fistula. *Urology* 80: 1156-1160.
11. Bermudez DM, Canning DA, Liechty KW (2011) Age and pro-inflammatory cytokine production: wound-healing implications for scar-formation and the timing of genital surgery in boys. *J Pediatr Urol* 7: 324-331.
12. Liu GQ, Tang HJ, Zhao YW, Wang JF, Li H, et al. (2006) [One stage repairing operation in neonatal hypospadias]. *Zhonghua Nan Ke Xue* 12: 66-67.
13. Hayashi Y, Kojima Y (2008) Current concepts in hypospadias surgery. *Int J Urol* 15: 651-664.
14. Prat D, Natasha A, Polak A, Koulikov D, Prat O, et al. (2012) Surgical outcome of different types of primary hypospadias repair during three decades in a single center. *Urology* 79: 1350-1353.