

Case Report

Open Access

# Secondary Acute Myeloid Leukemia (sAML) Immediately after Intensive Chemotherapy of Acute Lymphoblastic Leukemia (ALL)

Sebastian Grosicki<sup>1\*</sup>, Agnieszka Barchnicka<sup>1</sup>, Ewa Bodzenta<sup>1</sup>, Olga Haus<sup>2,3</sup> and Anna Jaśkowiec<sup>2</sup>

<sup>1</sup>Department of Hematology, Branch Municipal Hospital in Chorzow, Poland

<sup>2</sup>Department of Hematology, Blood Cancer and Bone Marrow Transplantation in Wrocław, Poland

<sup>3</sup>Department of Clinical Genetics CM UMK in Bydgoszcz, Poland

## Abstract

A 20-year-old woman was admitted to our unit, because of pre-B acute lymphoblastic leukemia (ALL). Classical cytogenetics revealed a normal karyotype. In FISH analysis no TEL-AML1 fusion, rearranged MLL gene, or BCR-ABL were found.

The induction and consolidation chemotherapy was conducted according to protocol PALG 5-2007. In the assessment of minimal residual disease using flow cytometry after consolidation 0.02% of the baseline phenotype of lymphoblasts were found. After two weeks of the completion of intensive chemotherapy, the patient was admitted in emergency to hematology inpatient unit, because of secondary acute myeloid leukemia (sAML). The conventional cytogenetic karyotype was complex: 46, XX, der (7) t (5;7;10;?)del(7)(q22), t(11;17)(p11;q21),del(14)(q24q32).

After the diagnosis of sAML, induction chemotherapy was given according to the program PALG DAC: cytarabine 329 mg/d 1-7, daunorubicin 90 mg iv/d 1-3, cladribine 8 mg/d 1-5. The patient died due to progression of refractory leukemia in 45 days.

The risk of developing of the sAML after treatment of ALL in adults is about 0.5-1% after few years. Our case was unique, because sAML developed rapidly, just after five months of ALL diagnosis, three months after CR1 and two weeks after completion of consolidation chemotherapy.

**Keywords:** Acute Lymphoblastic Leukemia (ALL); Secondary Acute Myeloid Leukemia (sAML); Chemotherapy

## Case Presentation

A 20-year-old Caucasian woman, previously healthy, was admitted to our department because of the growing weakness within four weeks that had begun with a viral infection of the upper respiratory tract. On admission, no signs of infection were stated. In physical examination, splenomegaly (3 cm from the left costal arch) was found. There were no hepatomegaly, lymphadenopathy, gingival hypertrophy, or mucocutaneous petechiae found in the physical examination. The complete blood count on admission was: WBC  $44.87 \times 10^9/L$  (91% lymphoblasts in smear), Hgb 8.6 g/L, platelets  $49 \times 10^9/L$ , 95% small homogeneous lymphoblasts infiltration of bone marrow. Flow cytometry performed on the bone marrow revealed pre-B acute lymphoblastic leukemia (ALL) with expression of CD19, CD10, CD34, TdT and cytoplasmatic IgM without co-expression of myeloid antigens (table 1). Conventional cytogenetics of bone marrow revealed a normal karyotype, 46, XX (Figure 1). Twenty one metaphases were explored. In FISH analysis of bone marrow cells no TEL-AML1 fusion, rearranged MLL gene, or BCR-ABL was found (Figure 2). The RT-PCR also did not confirm the presence of BCR-ABL and MLL/AF4.

After the diagnosis, induction chemotherapy was conducted according to the Polish Adult Leukemia Group protocol PALG 5-2007. The patient received prednisone 90 mg a day as pretreatment on days 1-7, then a total of 3 doses vincristine 2 mg/d iv on days 8, 15, 22, epirubicin 80 iv/d days 8, 15, 22, 4 times native L-asparaginase 10,000 IU/d, prednisone 90 mg p.o daily on days 1-28. During the induction chemotherapy period, intrathecal chemotherapy with pegylated cytarabine (DepoCyte) 50 mg was given only once due to thrombocytopenia. In the assessment of cerebrospinal fluid no deviations were found. Induction was reduced because of the profound neutropenia, febrile conditions, and coagulation disorders in the

form of low levels of fibrinogen. During neutropenia related to the chemotherapy, granulocyte colony stimulating factor (G-CSF) 300 ug/d for 9 days was given. ALL was sensitive to steroids with reduction of WBC from 16 G/l to WBC 0.79 G/l after 7 days of pretreatment. On recovery, a subsequent bone marrow examination showed no evidence of residual disease (CR1) in accordance with WHO criteria.




Figure 1: Bone marrow cytogenetic examination with normal karyotype, 46 XX.

**\*Corresponding author:** Sebastian Grosicki, MD, PhD, Oddzial Hematologiczny Zespól Szpitali Miejskich, 41-500 Chorzow, Karola Miarki 40, Poland, Tel: +48-32-3499723; Fax: +48-32-346147; E-mail: [sgrosicki@wp.pl](mailto:sgrosicki@wp.pl)

Received February 20, 2013; Accepted March 26, 2013; Published March 28, 2013

**Citation:** Grosicki S, Barchnicka A, Bodzenta E, Haus O, Jaśkowiec A (2013) Secondary Acute Myeloid Leukemia (sAML) Immediately after Intensive Chemotherapy of Acute Lymphoblastic Leukemia (ALL). J Leuk 1: 102. doi:10.4172/2329-6917.1000102

**Copyright:** © 2013 Grosicki S, et al. This is an open-access article distributed under the terms of the Creative Commons Attribution License, which permits unrestricted use, distribution, and reproduction in any medium, provided the original author and source are credited.

Consolidation chemotherapy was also given consistently with the protocol PALG 5-2007. The patient received methotrexate 2.4 g iv/d for 2 days, etoposide 2x160 mg iv/d for 2 days, then cyclophosphamide 1600 mg iv/d for 4 days, cytarabine 4.8g/d for 2 days, the native L-asparaginase 10,000 IU iv/d 2 times were given. Afterwards, she received 3 time's triple intrathecal chemotherapy cytarabine 50 mg + methotrexate 15 mg + dexamethasone 4 mg. There were no deviations in the assessment of cerebrospinal fluid. Agranulocytosis period after chemotherapy was complicated by febrile states of the ongoing three days with symptoms of gastritis. In the assessment of minimal residual disease (MRD) using flow cytometry after consolidation 0.02% of the baseline phenotype of lymphoblasts, and besides, neutrophils 67.7%, myeloblasts 0.07%, lymphocytes 4.3%, erythroblasts 22.3% and monocytes 4.9% were found.

After two weeks of the completion of intensive chemotherapy, the patient was admitted in emergency to hematology inpatient unit, due to severe vomiting and general deterioration of health. In the physical examination, splenomegaly of 20 cm from the costal arch was stated. In additional studies, there was WBC 56x10<sup>9</sup>/L with 61% of myeloblasts infiltration, platelets 19x10<sup>9</sup>/L, Hgb 10.9 g/dL. In bone marrow aspirate, 90% infiltration of myelomonoblasts according to FAB morphology, often in cases of sAML [1] was described. In flow cytometry, phenotype with expression of CD13, CD33, CD15, CD64 without co-expression of lymphoid antigens was found. The conventional cytogenetic of bone marrow karyotype was complex: 46, XX, der (7) t(5;7;10;?)del(7)(q22), t(11;17)(p11;q21), del(14)(q24q32) (Figure 3). Twenty four metaphases were explored. FISH examination of bone marrow cells with whole chromosome painting probes (wcp) for chromosomes 11 and 17 done at diagnosis of AML showed derivative chromosomes resulting from translocation t(11;17) (Figure 4).

Retrospective studies of bone marrow cytogenetic preparations from the time of diagnosis of ALL using FISH, did not reveal the presence of above described aberrations.

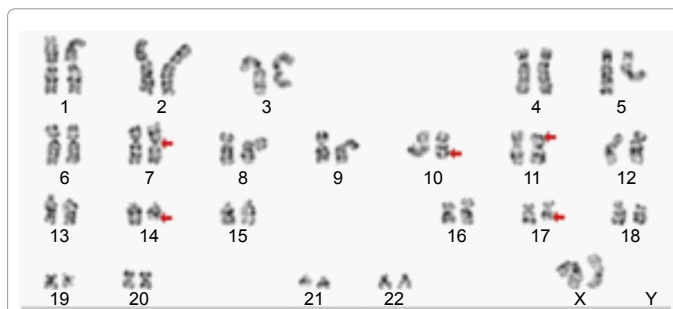


Figure 3: Bone marrow cytogenetics with complex karyotype – red arrows show abnormal chromosomes.

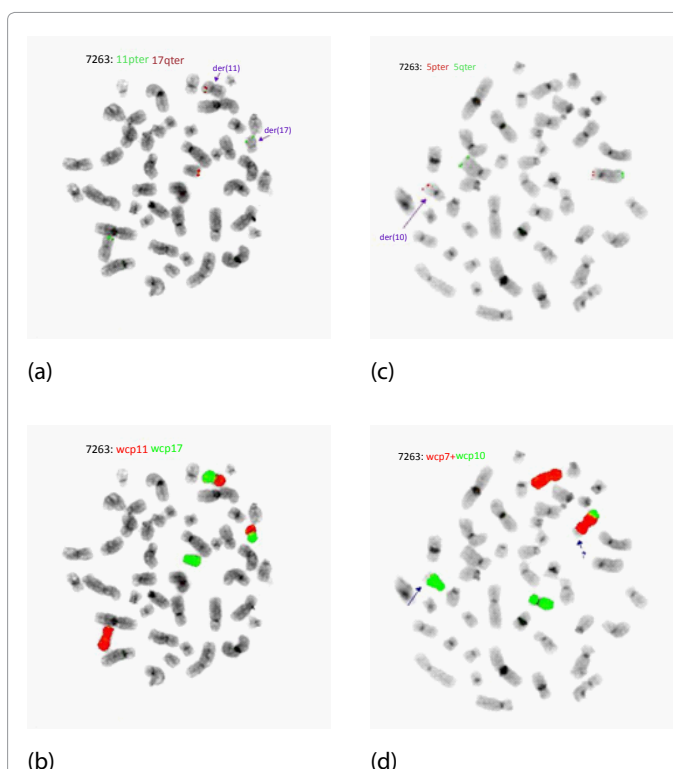


Figure 4: FISH examination of bone marrow with whole chromosome painting probes (wcp) for chromosomes 11 and 17 done at diagnosis of AML showed derivative chromosomes resulting from translocation t(11;17): (a): red signals = 17q telomeres. The arrow shows abnormal localization of one of them on der(17) (b): The same metaphase: FISH with wcp 11 and 17 probes, showing translocation t(11;17). FISH with wcp probes for chromosomes 5, 7, and 10 showed complex translocation t(5;7;10); (c): chromosome 5 telomere probes: 5pter - red, 5qter - green. On the right - normal chromosome 5 (red and green signals), on the left - chromosome 5 with deletion of its short arm (only red signal is visible, the green one was translocated to chromosome 10. The arrow shows derivative chromosome 10 comprising the fragment of 5p with the red signal of 5pter. (d): The same metaphase with wcp probes for chromosomes 7 and 10. The arrows show abnormal chromosomes: green = derivative chromosome 10 with unstained fragment from chromosome 5, and red = derivative 7 with green fragment from chromosome 10 and unstained fragment of unknown origin).




Figure 2: FISH examination of bone marrow no TEL-AML1 fusion (a): red signal TEL probe, green AML1 probe, rearranged MLL gene (b) MLL break apart, or BCR-ABL (c) red signal ABL (22q11) probe, green BCR (22q11) probe were found.

In none of the analyzed 100 interphasal cells MLL, CBFβ, RARA, IGH, gene rearrangements and deletion of TP53 gene locus were found. In the bone marrow studies by RT-PCR the presence of translocations AML1-ETO and CBFβ-MYH11, as well as NPM1 mutations were excluded. The whole picture of genetic changes of myeloblasts indicates

The phenotype for bone marrow on ALL diagnosis	CD45+, CD19+, CD34+, CD117+, cytCD79a+, CD33-, CD13-, cytMPO-, CD3-, cytCD3-, CD7-, CD10+, TdT+, CD22dim+, CD20-, cytIgM +, IgM -, kappa-, lambda-,
The phenotype for bone marrow on sAML diagnosis	CD45+, CD19-, CD34-, CD117-, cytCD79a-, HLA-DR+, CD33+, CD13+, cytMPO-, CD11b+, CD10-, CD15+, CD64+, CD14-, CD16-, CD56+, CD71-, CD41-, CD7-, CD3-, cytCD3-,

**Table 1:** The results of flow cytometric immunophenotyping for bone marrow on ALL and sAML diagnosis.

the likely origin of secondary acute myeloid leukemia (sAML), which qualifies the patient to the group of a worse prognosis. However, the disease appeared extremely rapidly. LDH level was high and amounted to 601 U/L.

After the diagnosis of sAML, induction chemotherapy was given according to the program PALG DAC: cytarabine 329 mg c/d on days 1-7, daunorubicin 90 mg iv/d days 1-3, cladribine 8 mg iv/d days 1-5 [2,3]. Tolerability of treatment was good. Nadir of WBC  $0.03 \times 10^9/L$  with neutrophils  $0 \times 10^9/L$  was noted in 15 induction day. The period was complicated with post therapeutic agranulocytosis febrile states, without explicit signs of infection. In addition, coagulation abnormalities in the form of chronic low-level of fibrinogen and elevated D-dimers were observed. Patient required intensive substitution treatment. She received 10 units of PRBC, 6 units of FFP, 1 g of Fibrinogen, 40 units of the platelets. In 28 day of induction, the resistance of the type of regrowth of leukemic cells in the peripheral blood smear was shown. Supportive treatment was then carried out. The patient died due to progression of refractory leukemia in 45 days from induction beginning with symptoms of multi-organ failure.

## Discussion

The risk of developing of the secondary cancer after treatment of acute lymphoblastic leukemia in children is estimated at 5-6% [4-10]. In adults, it is estimated at 9.4% after 15 years [11]. The risk of secondary hematological cancer is low and is estimated in adults at 2.36% after 30 years and 3.3% after 18 years of treatment.

Verma et al. [12] reports in the study of a total of 641 cases, the development of secondary acute myeloid leukemia in 6 patients (<1%) [12]. The disease evolved within a range of 13 to 74 (median 35.5) months since remission achievement after high dose chemotherapy hyper-CVAD. None of these patients had previous alloHSCT, one of them had radiotherapy. Only 1/16 patients (6%) achieved CR. OS was 6-16 months (median 8.25).

Tavernier, in the analysis of the ALL patients (treated within the studies of LALA group), found that the occurrence of secondary malignancies was 1.5% in patients after treatment of ALL, and AML accounted for 0.6%, that was the most common secondary neoplasm [11]. The development of secondary malignancies was estimated between 0.5 to 13.8 years (median 4.5 years) after diagnosis of ALL. Borgmann et al. [13] reports a similar incidence (0.5%) of the secondary AML in the group treated for ALL [13].

In our case, sAML developed rapidly, just after five months of ALL diagnosis, three months after CR1 and two weeks after completion of consolidation chemotherapy and after evaluation of MRD by flow cytometry at the amount of 0.02% and myeloblasts were calculated at 0.07%. The aberrations of the chromosome 5 and 7 long arms are quite typically found in sAML cases [1,12-15]. However, in our patient only the aberrations involving short arms of these chromosomes were found. Together with balanced t(11;17) and 14q deletion, they formed complex, unbalanced karyotype with a very poor prognosis, which was confirmed by the absence of effect of DAC induction chemotherapy and the survival time was 45 days. Development of the secondary leukemia may be caused by many factors like biological nature of the primary tumor, type of chemotherapy and genetic predisposition. Etoposide

and alkylating agents are indicated as possible causes of sAML, on account of leading to alterations within the chromosome 5 and 7 [1,11-14]. In the described case, etoposide and cyclophosphamide were used, but in standard doses, which should not increase the risk of sAML. We suppose, there must have been a very deep defect in repair mechanisms.

## References

- Pedersen-Bjergaard J, Philip P, Larsen SO, Andersson M, Daugaard G, et al. (1993) Therapy-related myelodysplasia and acute myeloid leukemia. Cytogenetic characteristics of 115 consecutive cases and risk in seven cohorts of patients treated intensively for malignant diseases in the Copenhagen series. *Leukemia* 7: 1975-1986.
- Holowiecki J, Grosicki S, Robak T, Kyrzc-Krzemien S, Giebel S, et al. (2004) Addition of cladribine to daunorubicin and cytarabine increases complete remission rate after a single course of induction treatment in acute myeloid leukemia. Multicenter, phase III study. *Leukemia* 18: 989-997.
- Holowiecki J, Grosicki S, Giebel S, Robak T, Kyrzc-Krzemien S, et al. (2012) Cladribine, but not fludarabine, added to daunorubicin and cytarabine during induction prolongs survival of patients with acute myeloid leukemia: a multicenter, randomized phase III study. *J Clin Oncol* 30: 2441-2448.
- Hijjiya N, Hudson MM, Lensing S, Zacher M, Onciu M, et al. (2007) Cumulative incidence of secondary neoplasms as a first event after childhood acute lymphoblastic leukemia. *JAMA* 297: 1207-1215.
- Bhatia S, Sather HN, Pabustan OB, Trigg ME, Gaynon PS, et al. (2002) Low incidence of second neoplasms among children diagnosed with acute lymphoblastic leukemia after 1983. *Blood* 99: 4257-4264.
- Löning L, Zimmermann M, Reiter A, Kaatsch P, Henze G, et al. (2000) Secondary neoplasms subsequent to Berlin-Frankfurt-Münster therapy of acute lymphoblastic leukemia in childhood: significantly lower risk without cranial radiotherapy. *Blood* 95: 2770-2775.
- Winick NJ, McKenna RW, Shuster JJ, Schneider NR, Borowitz MJ, et al. (1993) Secondary acute myeloid leukemia in children with acute lymphoblastic leukemia treated with etoposide. *J Clin Oncol* 11: 209-217.
- Neglia JP, Meadows AT, Robison LL, Kim TH, Newton WA, et al. (1991) Second neoplasms after acute lymphoblastic leukemia in childhood. *N Engl J Med* 325: 1330-1336.
- Pui CH, Ribeiro RC, Hancock ML, Rivera GK, Evans WE, et al. (1991) Acute myeloid leukemia in children treated with epipodophyllotoxins for acute lymphoblastic leukemia. *N Engl J Med* 325: 1682-1687.
- Pui CH, Behm FG, Raimondi SC, Dodge RK, George SL, et al. (1989) Secondary acute myeloid leukemia in children treated for acute lymphoid leukemia. *N Engl J Med* 321: 136-142.
- Tavernier E, Le QH, de Botton S, Dhédin N, Bulabois CE, et al. (2007) Secondary or concomitant neoplasms among adults diagnosed with acute lymphoblastic leukemia and treated according to the LALA-87 and LALA-94 trials. *Cancer* 110: 2747-2755.
- Verma D, O'Brien S, Thomas D, Faderl S, Koller C, et al. (2009) Therapy-related acute myelogenous leukemia and myelodysplastic syndrome in patients with acute lymphoblastic leukemia treated with the hyperfractionated cyclophosphamide, vincristine, doxorubicin, and dexamethasone regimens. *Cancer* 115: 101-106.
- Borgmann A, Zinn C, Hartmann R, Herold R, Kaatsch P, et al. (2008) Secondary malignant neoplasms after intensive treatment of relapsed acute lymphoblastic leukaemia in childhood. *Eur J Cancer* 44: 257-268.
- Zompi S, Viguié F (2002) Therapy-related acute myeloid leukemia and myelodysplasia after successful treatment of acute promyelocytic leukemia. *Leuk Lymphoma* 43: 275-280.
- Pedersen-Bjergaard J, Pedersen M, Roulston D, Philip P (1995) Different genetic pathways in leukemogenesis for patients presenting with therapy-related myelodysplasia and therapy-related acute myeloid leukemia. *Blood* 86: 3542-3552.