

## Revisit Rescula and Cystoid Macular Edema and Refractory Glaucoma

Tina Guanting Qiu\* (Review by E. Randy Craven MD, Martin Wand MD, Bruce Shields MD)

Biopharma Physician Consultant (independent), Peabody, MA, USA

\*Corresponding author: Tina Guanting Qiu, MD PhD, Biopharma Physician Consultant (independent), Peabody, MA United States, Tel: 001-978 998 0624; E-mail: tina70qiu@gmail.com

Received date: Aug 06, 2015; Accepted date: Sep 09, 2015; Published date: Sep 13, 2015

Copyright: © 2015 Qiu TG et al. This is an open-access article distributed under the terms of the Creative Commons Attribution License, which permits unrestricted use, distribution, and reproduction in any medium, provided the original author and source are credited.

### Abstract

Rescula (unoprostone isopropyl) has been in the market as ocular hypotensive drug since 1994. There are amounting scientific research and post-marketing clinical experiences reported in peer review journals. Yet there seems limited understanding about its unique clinical implication associated with newly discovered molecular mechanism (traits) of BK channel activation. Hence this review article is using a focal lens with an eye on B-K channel activation to further delineate possible roles of rescula in modulating chronic parainflammation in the eye, which may eventually set it apart from the rest lipid hypotensive drugs such as latanoprost that is pro-inflammatory in nature. Cystoid macular edema and refractory glaucoma will be the key historical clinical case highlights.

**Keywords:** Rescula (Unoprostone); B-K channel activation; Parainflammation; Cystoid macular edema; Refractory glaucoma; Retinitis pigmentosa; Integration

### Background

Rescula (unoprostone isopropyl) was the first docosanoid lipid hypotensive drug approved for the treatment of open-angle glaucoma (OAG) and ocular hypertension (OH) in Japan (R-Tech Ueno Ltd) in 1994, followed by the US approval (CIBA Vision/Novartis AG) in 2000, but it was shortly pulled off the USA market by Novartis AG in 2005. Since its first launch, there are about 6.4 million human subjects across 45 countries receiving rescula eye drops (0.12% or 0.15%, bid) for the treatment of glaucoma and OH, in which rescula has demonstrated excellent systemic safety and favorable ocular tolerability. Among these 6.4 million human subjects including the patients on the pivotal Phase III trials, there were three incidences of cystoid macular edema (CME) reported in 2002, which were seemingly related to the use of rescula [1,2]. As of such, rescula has been warned with caution of causing macular edema enlisted on the new product label (package insert) issued by the food and drug administration (FDA) in 2012 [3]. In late 2012 when Sucampo Pharma was about to re-launch rescula as a new B-K channel activator for glaucoma treatment in the USA, there was a debate over the question about whether or not rescula should be still marketed as a subset family of prostaglandin analogues (PGAs) like latanoprost. To answer this question, we have to first understand what B-K channel activation exactly means in clinical disease management and pathological process.

### Rescula (B-K Channel Activator) vs Prostaglandin

Rescula or Unoprostone isopropyl belongs to the "prostone" family of a naturally occurring unsaturated docosanoic fatty acid in the body, its activation of B-K channel and subsequent restoring of cellular membrane hemostasis has multiple pharmacological and clinical implications, such as regulating vascular smooth muscle tones and relaxing contractibility of trabecular meshwork complex, and modulating innate inflammatory responses [4]. Decades of amounting clinical evidences and experimental studies have led us to gain new

insight and appreciation of rescula molecular mechanism of action, further enriched our understanding about its biological and pharmacological behaviors, in particular of its role in the subset of glaucoma clinical phenotypes such as normal tension glaucoma (NTG) and refractory cases. One of the key milestone studies published in 2011 has changed our fundamental view on the difference between rescula and PGAs [5]. This study not only has suggested that rescula IOP lowering effect is through B-K channel activation to drive cell membrane hyperpolarization (not depolarization), which results in relaxation of trabecular meshwork thus an increase of conventional outflow, but also demonstrated that unoprostone Isopropyl and its metabolite M1 are not EP1 and EP4 receptor agonist, and has a weak binding affinity to prostaglandin receptor (PF) in vitro (1000 times lower than latanoprost or Xalatan), therefore, within the therapeutic dose window rescula does not activate prostaglandin receptors at all [5]. Apparently these evidences are pointing against the original belief that rescula is subset of prostaglandin analogues, though they both may share a similar downstream metabolite pathway. Of note, endogenous prostaglandins are proinflammatory in nature. They are the key risk factors responsible for CME in patients following cataract surgeries [6]. There are various clinical case reports about the side effect of synthetic prostaglandin analogues (such as latanoprost and travaprost) suggesting a causative link between PGAs and CME in patients, who have undergone both uneventful cataract surgeries and routine cataract extraction [6,7]. A recent 6-month head-to-head randomized clinical study comparing three different PGAs vs rescula in patients with POAG or OH has strengthened the argument that PGAs pose a potential risk of CME due to the breakdown of blood-ocular barrier in patients treated with travoprost, bimatoprost, and latanoprost (but not Rescula) [8]. Based on a simple definition of cell physiology in textbook, the activation of B-K channel accompanies by potassium intracellular influx, which further drives cell membrane to a resting stage, subsequently restores cell hemostasis, thus offers a nature repairing and healing effect. The worldwide clinical experience has clearly demonstrated that rescula by far perhaps is one of the safest ocular hypotensive drugs despite its moderate IOP lowering potency. Unlike beta-blocker or alpha-adrenergic agonist, there is no imbalance of cardiovascular and respiratory safety concerns in glaucoma patients

treated with rescula eye drops. Its ocular tolerability (hyperemia) is largely related to the formulation (e.g. pH and preservative). As we closely examined the details of FDA label (package insert), safety warning of rescula on CME and other inflammatory condition seems rootless, which is indeed contradicting with its anti-inflammatory nature. Therefore, one of the purposes for this review is to provide in-depth scientific analysis about the root causes of these three old CME cases in hopes of offering evidence-based suggestion for future consideration on FDA label amendment as appropriate, more importantly, it may clear up the barrier to reposition rescula as a new molecular entity (not prostaglandins) with unique therapeutic potential for glaucoma patient care.

### Revisit Rescula and CME (Adverse Event)

For the record, throughout the entire PubMed literature review and Google Scholar search (as of August 2015) along with the pool safety efficacy data from Phase I-IV clinical trials (US, EU, Canada, Israel, and Japan) [9,10], there are only three reported CME adverse events related to the use of rescula: two cases were reported by Dr. Martin Wand in 2002 [1] and the third case was separately reported by Watanabe K in Japan in 2003. The first patient was 82-year old male, had multiple intraocular surgical combinations: Phaco+IOL+trabeculectomy+mitomycin followed by vitrectomy (due to endophthalmitis) with complications of posterior capsular rupture and pupil distortion. His filtering surgery was not successful (the “bleb” was flat and inflamed) and IOP was 27 mmHg. He was given rescula and dorzolamide. Around 2-4 months following the latest filtering surgery, he developed CME in a delay fashion, which was resolved following a steroid treatment. Rescula was discontinued for a few weeks, and then put it back. Patient did not return. The second patient was 81-year old female, who had cataract removal and IOL implant with vitreous gel loss and displacement to the anterior chamber, and her pupil was distorted. She failed twice at prior trabeculectomy and was treated with a combination of three hypotensive drugs (rescula+timolol+dorzolamide). A few weeks later, rescula was switched to bimatoprost, subsequently she developed CME. Watanabe K in Japan reported the third case back to 2003. This was another refractory glaucoma case in 71-year old female, who had pseudophakic eyes. She was given rescula eye drops (0.12%, bid) for one month, then replaced by latanoprost for another month, shortly she developed clinically significant CME [2]. In this single case report, Watanabe K concluded that the macular edema was related to the use of latanoprost eye drops.

Before we dissect these cases, it is important to know that CME is a sign of breakdown of blood retinal barrier due to intricate ocular inflammation caused by mechanical vitreous-macula traction or biological toxins, such as endogenous or exogenous prostaglandins, bradykinins, and interleukins. The occurrence of CME is often associated with various vascular-inflammatory pathological conditions such as diabetic retinopathy, vein occlusion, uveitis, and commonly seen following cataract surgery in a delayed response occurring between 3-12 months. If there is a posterior capsular rupture and vitreous loss, the incidence can reach up to 20% with clinical significance [11]. While revisiting the above two refractory glaucoma cases, the root causes of CME could be one or more of the intraocular surgical complications, of which both patients had suffered, such as posterior capsule rupture, vitreous-macula traction, inflamed flat bleb, endophthalmitis, or mitomycin C. Given the nature course of such intractable or refractory disease process, patients usually do not

respond well to standard hypotensive medication for glaucoma. In ophthalmology clinic, this type of patient often has a quiet “inflammable” eye, which is at a high risk of bleb failure if opted for trabeculectomy; if they undergo vitrectomy, they tend to have a higher recurrence of post-Op. proliferative vitreous retinopathy and macular edema. Such refractory glaucoma can also be seen in the middle-aged or young healthy male with unknown immunological predisposition, possibly associated with mutations of optineurin (OPTN) gene, which is expressed in trabecular meshwork, retina and brain. OPTN has been implicated in tumor necrotic factor-alpha signaling pathway [12].

In retrospect, unlike PGAs, we believe rescula might have a therapeutic value to CME through a possible restoration of blood-retina barrier or blood aqueous barrier. At least we now may set off the alarm to patients who have chronic inflammation or pseudophakic eyes that require intraocular pressure medication. Of note, back to 2002-03, there was little understanding about mechanistic difference between rescula and the rest PGAs (latanoprost and bimatoprost). According to Dr. Martin Wand, in those early years, rescula along with all other prostaglandin analogues were simply categorized as lipid hypotensive drugs. Until the recent scientific discovery of rescula as B-K channel activator, we are able to truly differentiate rescula from the rest PGAs at molecular basis. Further this review will revisit rescula for refractory glaucoma management, in hopes of gaining additional evidence-based insight of its clinical implication associated with B-K channel activation and tissue repair.

### Rescula and Refractory Glaucoma (Parainflammation)

The compass of refractory glaucoma covers a broad spectrum of significantly challenging clinical cases, including secondary glaucoma caused by uveitis, neovascular glaucoma derived from diabetic or vein occlusions, traumatic glaucoma, congenital glaucoma or surgical complication (silicon oil tamponade) as well as primary open-angle glaucoma that was not able to be controlled by maximal tolerable ocular hypotensive medications or at high risks of incisional surgical failures. These visual devastating diseases often leave physicians and patients with little choice.

In echoing of refractory glaucoma on the above CME cases, we would like to bring two historical clinical studies about rescula in refractory or intractable glaucoma in Japan. There were 23 eyes (n=14 patients with POAG and n=1 with OH) reported by Azuma in 1993, and 115 eyes (64 patients with POAG) reported by Yoshida K et al. in 1998, respectively [13-14]. In both studies, rescula was used as an “add-on” to existing glaucoma medications, for which patients failed to respond favorably but rescula made a difference. Azuma [13] documented some striking features of a long-term IOP lowering curve related to rescula treatment in his report. Please see the exemplary figure (Figure 1) attached of two individual patients, who had been treated with two non-PGA hypotensive drugs, but their IOPs stayed as high as 26-30 mmHg. When rescula (0.12% eye drops, bid) was added, surprisingly their IOP lowering curve and pattern showed a very unusual pharmacokinetic trend, suggesting a slow and winded descending slope before reaching to its steady state at the maximal amplitude of IOP reduction (@mid-teens) [13]. The entire course took a prolonged period of 4-12 weeks. Whereas under a “normal” circumstance, most hypotensive drugs (timolol, or latanoprost) are through neuro-vascular modulation in a fast mode action, so their IOP reduction peaks at a few hours following the first instillation, and reaches to the steady state within a day or two and sustains for months with no change of amplitude. Another important note is that the

magnitude of IOP reduction in these “unusual” glaucoma patients was unusually high (up to 35%) compared to the average of IOP reduction (14-19% or 3-4 mmHg) found in rescula pivotal clinical trials. Obviously such reduction amplitude (potency) is beyond the normal performance of rescula seen in the majority of POAG or OH patients. In this report, Azuma had observed 14 patients (21 eyes) with POAG and one patient (2 eyes) with OH, who shared a similar pattern of IOP lowering curve but with great variance regarding the time reaching to

steady state [13]. For example, some patients may take one month, and others may take up to three months prior to reaching to their maximal IOP reduction respectively. All these 15 patients (23 eyes) began to respond to rescula within one month. Prior to rescula add-on, they were non-responsive to conventional ocular hypotensive drugs including beta-blockers (latanoprost was not available then), their IOP reduction sustained for 6-12 months during the study period, and further avoiding glaucoma surgical interventions.

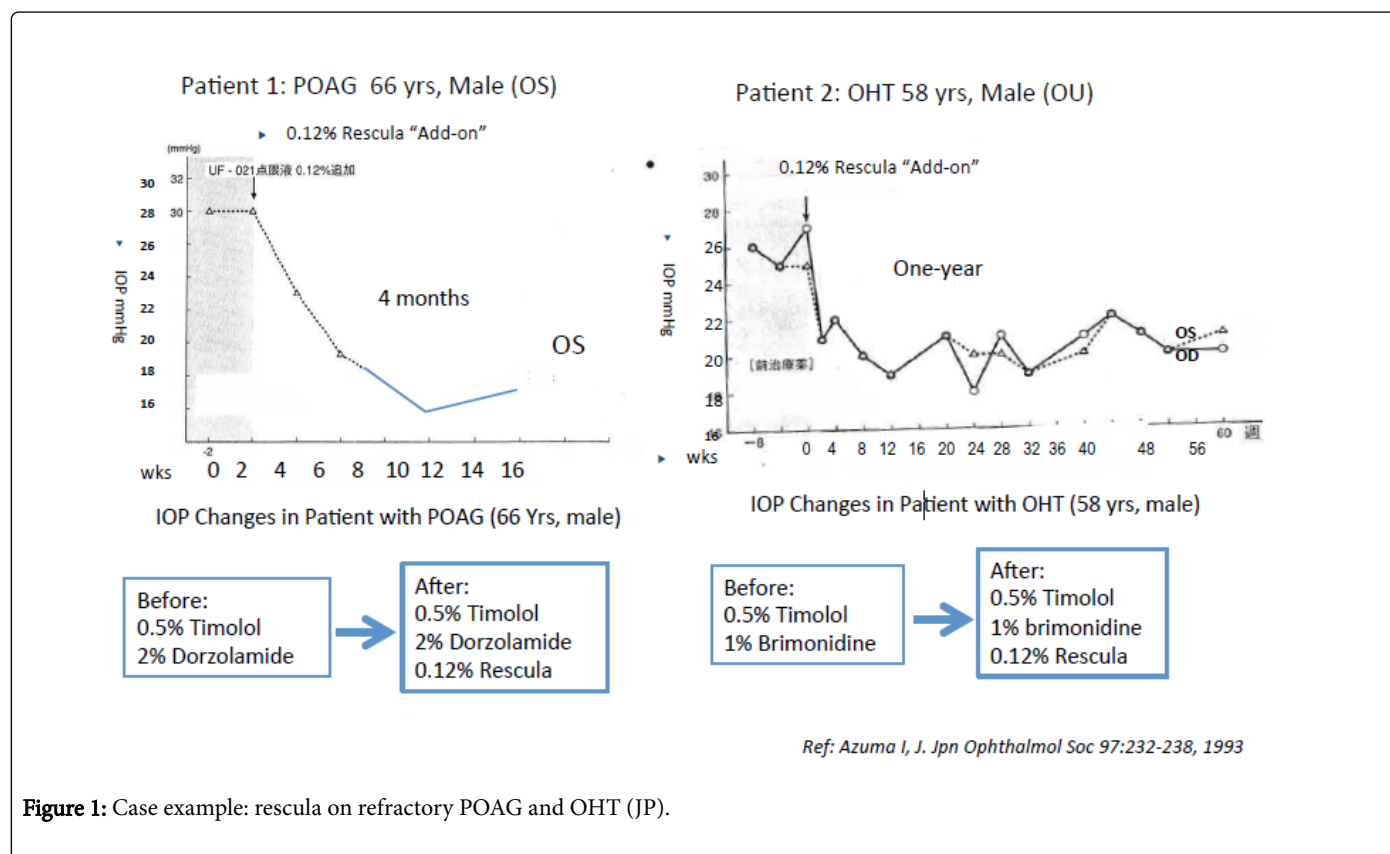


Figure 1: Case example: rescula on refractory POAG and OHT (JP).

Later in 1998, Yoshida K et al. reported [14] another retrospective study on 64 patients (115 eyes) with refractory POAG, who had already been treated with 2-4 different ocular hypotensive drugs, and some even had trabeculectomy and cataract removal, but their intraocular pressures were not under normal control (>21 mmHg). When rescula (0.12%, bid) was added to the existing regimen, all patients responded effectively to rescula treatment, evidenced by incremental IOP reduction over a period of 1-6 months. The mean intraocular pressure (standard deviation) before the addition of rescula to the existing regimens was 21.3 ± 4.4 mmHg. The values at 1 month, 3 months, and 6 months after treatment were 20.2 ± 3.9 mmHg, 19.4 ± 3.4 mmHg, and 18.4 ± 2.5 mmHg, respectively. Majority patients had avoided further incisional glaucoma surgeries. This is an important clinical outcome measure as this type of refractory patient often suffers great risks of filtering bleb failure due to chronic inflammation and fibrosis. In the USA, many years ago Dr. E Randy Craven (now in Johns Hopkins) had treated two glaucoma patients with uncontrolled IOP elevation after trying three different PGAs (latanoprost, bimatoprost, travoprost) separately, upon the switch to rescula, both patients had dropped their IOPs to the mid-teens. These preliminary clinical observations seem opening our eyes to see a different facet of rescula. First, its slowly incremental increase of IOP reduction over

time, which in some cases resulted in maximal 35% reduction upon reaching to the steady state is very different from what we know about rescula as a moderate IOP lowering drug with a fast-mode action (3-4 mmHg or 15-20% reduction). Introducing rescula’s new mechanistic on modulating chronic inflammation might help explain such unique pharmacological behaviors. As such intractable glaucoma patients often suffer intricate chronic para-inflammation due to oxidative stress or insult within trabecular meshwork, for which the homeostatic imbalance of cytokines and inflammatory molecules such as endothelium (ET)-1, NF-Kappa B, interleukins, and integrin might involve [4].

Of note, the above two long-term glaucoma clinical study reports were not post-marketing pivotal phase IV studies, thus suffered various historical inherited limitations, e.g. insufficient power of N, patient drop-off during long-term follow up, randomized controls and etc. As of such, this review does not intend to draw any affirmative conclusion or make solid recommendation to clinical practice or regulatory consideration but merely help enlighten a research direction or offer a new perspective on possibilities of repurposing rescula into a subset of glaucoma patients, who may suffer persistent chronic parainflammation.

In clinic, we often say “giving the right drug to the right patient at the right time (George Spaeth at Wills Eye Institute, PA)”. Rescula is a drug that has not been given to the right patient at the right time, because what we know about rescula is largely based on the pivotal clinical trials back to more than a decade ago (1997) [9], and we do not know that rescula has anti-inflammatory activities and acts on B-K channel within trabecular meshwork to increase the conventional outflow that is different from proinflammatory prostaglandin analogue [5]. As described in above refractory glaucoma study report in 1998, rescula was coined as a prostaglandin F2a-related compound, which was thought to act upon uveoscleral aqueous outflow [14]. To bridge the gaps towards clinical appreciation of its true value, it requires across-functional disciplinary knowledge and “integration” from cell physiology (B-K channel and hyperpolarization), pharmacology (IOP lowering) to glaucoma pathological process (parainflammation) and comprehensive surgical medical glaucoma/retina disease management experience. On another note, rescula has been in the market since 1994, there are numerous publications including the most recent two reviews [15,16]. However none of them has touched the point of its clinical benefit that is unique to rescula as B-K channel activator; its potential pharmacological and therapeutic implications in broad chronic parainflammatory pathological process such as refractory glaucoma, CME and retinitis pigmentosa (RP) is the novelty and essence of this review. To our best knowledge, rescula by far perhaps is the only ocular hypotensive drug that might have anti-inflammatory activities due to its potentials of restoring cell homeostasis via B-K channel activation.

### **Rescula and Neurovascular Effects**

In addition to anti-inflammatory activity, rescula may also have a role in neural protection directly or indirectly to the retinal ganglion cell or photoreceptor cell through B-K channel driven cell membrane hyperpolarization (resting mode). Emerging experimental studies have provided new evidences suggesting that unoprostone isopropyl has neuroprotective effects against endothelin-1 (ET-1) induced neuronal cell injury during the development of normal tension glaucoma and hypertensive glaucoma, and a possible anti-oxidative effect to trabecular meshwork through the inhibition of ET-1, a potent vascular constrictive peptide [5,17]. The recent Phase 2 randomized clinical trials of unoprostone Isopropyl eye drops (0.12% bid or qid) for retinitis pigmentosa (RP) have showed that unoprostone may have unique visual functional benefits to patient with RP through neurovascular modulation and ocular blood flow improvement [18]. Phase 3 randomized placebo control pivotal clinical trials for RP are currently undertaken by R-Tech Ueno in Japan. Additionally, several clinical studies in Japan have also suggested that rescula may have unique roles in managing NTG through pressure independent factors, which ultimately can help patient maintain long-term visual field stability [19,20]. In patients with NTG, vision loss is associated with multiple vascular imbalance and intricate inflammatory components (e.g. ET-1 and TNF-a) other than elevated intraocular pressure alone (M Bruce Shields, MD) [21], among which neurovascular imbalance and ocular blood flow dysregulation may play important roles in optic nerve neuropathy and RGC cell apoptosis. This is also a very active area in researching for new targets of neural protection across both academic and pharmaceutical R&D sectors [4].

### **Conclusion and Future Prospect**

That rescula unique function of restoring cell membrane hemostasis (to a resting stage) via increasing the potassium intracellular conductance has layout a sound biologic basis of tissue repair and rejuvenation, which further sets apart of rescula from the rest lipid hypotensive PGA drugs (such as latanoprost, travoprost and bimatoprost). Endogenous prostaglandins are known to modulate normal cell function and participate in broad intricate inflammatory processes such as CME and uveitis [5,6]. As a B-K channel activator, the potential benefits of anti-inflammatory and neuroprotective functions may open up a broad therapeutic niche window to those whose glaucoma pathological identities involve with a complex chronic ocular inflammatory process, such as refractory glaucoma, or a combination of glaucoma with other ocular inflammatory conditions (uveitis).

Through this retrospective analytical review and evidence integration, we have also come to appreciate the importance of how post-market real world experience may reshape a drug clinical therapeutic profile, which could be largely different from what we have seen in pivotal Phase 3 clinical trials. Of note, this is also the first time that we are able to bring all these important evidences together to help put the B-K channel activation into a clinically and pharmacologically meaningful context. At this point, there are many scientific questions yet to be answered in terms of rescula therapeutic application in a subset glaucoma patient population, but the most urgent and intriguing one would be to establish the molecular link (connection) between B-K channel activation and possible inflammatory signaling pathways or factors (such as NF-kappaB, TNF-a, NOS, ET-1) in a possibly small subset of refractory open angle glaucoma and NTG, for which the later has high prevalence (25% to 40%) in Japanese descendants according to population based studies [22]. At clinical front, to capture the right patient population and glaucoma disease staging that is responsive to rescula in above described pharmacological fashion will be the key to maximize its therapeutic potential. To this end, it is our anticipation that rescula may offer unique benefits through modulating vascular inflammatory process (such as ET-1 signaling inhibition) and neuroprotective signaling to broaden the choices of glaucoma disease management algorithm, especially when pro-inflammatory PGAs and other IOP lowering drugs fall short at medical conditions involved with preexisting parainflammation.

### **Acknowledgements**

Author would like to extend sincere thanks to Sucampo Pharma especially the entire commercial medical affairs and marketing and sales teams for sponsoring and organizing series of high quality national and regional medical advisory board meetings for Rescula product launch project. Very special thanks to Naoko Shima, Director, Office of the President at R-Tech Ueno Ltd for her logistic help and reference support on the manuscript publication, including her timely support of obtaining the copyright permission from Japanese Ophthalmological Society. Her valuable insight of the recent clinical study results of unoprostone Isopropyl for retinitis pigmentosa is also appreciated.

Author also wishes to give very sincere thanks to Randy Craven, MD for sharing his encouraging experience about the two refractory glaucoma cases mentioned in this manuscript. His tireless efforts spending on many logistic dealings about the manuscript publishing



matters are deeply appreciated. Dr. Craven is currently the Chief of Glaucoma at King Khaled Eye Specialist Hospital, and Associate Professor at Wilmer Eye Institute, Johns Hopkins University School of Medicine. Very special thanks to Dr. M. Bruce Shields, Chair Emeritus of Ophthalmology Dept. at Yale School of Medicine, and Dr. Martin Wand, Professor of Clinical Ophthalmology at University of Connecticut (retired), for their early keen observation and documentation of the two clinical CME cases, which has triggered my curiosity to further investigate the subject of matter. Their retrospective and critical reviews on the manuscript and encouragements for publishing this article are most appreciated.

### Financial Interest

Tina Guanting Qiu, MD PhD is an independent ophthalmic executive consultant for Inotek Pharmaceuticals, MA and LambdaVision Inc. CT, currently affiliated with Directional Healthcare Advisors LLC (Principal), Your Encore Inc. (Expert) and Gerson Lehrman Group (Biomedical Council Member). Previously Dr. Qiu was Field Medical Consultant for Sucampo Pharma Americas LLC through MDea Inc. NY. Drs. M Bruce Shields and E Randy Craven, Martin Wand were key members of advisory board for Sucampo Pharma on rescula project.

### References

1. Wand M, Shields BM (2002) Cystoid macular edema in the era of ocular hypotensive lipids. *Am J Ophthalmol* 133: 393-397.
2. Watanabe K, Hayasaka S, Hayasaka Y, Nagaki Y, Watanabe K (2003) Cystoid macular edema associated with latanoprost use in a pseudophakic eye with a history of surgical complications. *Jpn J Ophthalmol* 47: 110-112.
3. [http://www.accessdata.fda.gov/drugsatfda\\_docs/label/2012/021214s006s007lbl.pdf](http://www.accessdata.fda.gov/drugsatfda_docs/label/2012/021214s006s007lbl.pdf)
4. Qiu TG (2015) New Frontiers of Therapeutic Intervention for Retinal Diseases and Product Development Strategy (review). *EC-Ophthalmology* 2.2: 81-91.
5. Cuppoletti J, Malinowska DH, Tewari KP, Chakrabarti J, Ueno R (2012) Unoprostone isopropyl and metabolite M1 activate BK channels and prevent ET-1-induced  $[Ca^{2+}]$  increases in human trabecular meshwork and smooth muscle. *Invest Ophthalmol Vis Sci* 53: 5178-5189.
6. Agange N, Mosaed S (2010) Prostaglandin-induced cystoid macular edema following routine cataract extraction. *J Ophthalmol* 2010: 690707.
7. Warwar RE, Bullock JD, Ballal D (1998) Cystoid macular edema and anterior uveitis associated with latanoprost use. Experience and incidence in a retrospective review of 94 patients. *Ophthalmology* 105: 263-268.
8. Arcieri ES, Santana A, Rocha FN, et al. (2005) Blood-Aqueous Barrier Changes After the Use of Prostaglandin Analogues in Patients. *Arch Ophthalmol* 123: 186-192.
9. Yamamoto T, Kitazawa Y, Azuma I, Masuda K (1997) Clinical evaluation of UF-021 (Rescula; isopropyl unoprostone). *Surv Ophthalmol* 41 Suppl 2: S99-103.
10. Ohtake Y, Tanino T, Kimura I, Mashima Y, Oguchi Y (2004) [Long-term efficacy and safety of combined topical antiglaucoma therapy--timolol & unoprostone vs. betaxolol & unoprostone]. *Nihon Ganka Gakkai Zasshi* 108: 23-28.
11. Rotsos TG, Moschos MM (2008) Cystoid macular edema. *Clin Ophthalmol* 2: 919-930.
12. Rezaie, Child A, Hiching R, Brice G, Miller L et al. (2002) Adult-onset primary open-angle glaucoma caused by optineurin. *Science*. 295 (5557): 1077-1079.
13. Azuma I (1993) [Clinical evaluation of UF-021 ophthalmic solution in glaucoma patients refractory to maximum tolerable therapy]. *Nihon Ganka Gakkai Zasshi* 97: 232-238.
14. Yoshida K, Tanihara H, Hiroi K, Honda Y (1998) Prognostic factors for hypotensive effects of isopropyl unoprostone in eyes with primary open-angle glaucoma. *Jpn J Ophthalmol* 42: 417-423.
15. Fung DS, Whitson JT (2014) An evidence-based review of unoprostone isopropyl ophthalmic solution 0.15% for glaucoma: place in therapy. *Clin Ophthalmol* 8: 543-554.
16. Harms NV, Toris CB (2013) Current status of unoprostone for the management of glaucoma and the future of its use in the treatment of retinal disease. *Expert Opin Pharmacother* 14: 105-113.
17. Munemasa Y, Kitaoka Y, Hayashi Y, Takeda H, Fujino H, et al. (2008) Effects of unoprostone on phosphorylated extracellular signal-regulated kinase expression in endothelin-1-induced retinal and optic nerve damage. *Vis Neurosci* 25: 197-208.
18. Yamamoto S, Sugawara T, Murakami A, et al. (2012) Topical Isopropyl Unoprostone for Retinitis Pigmentosa: Microperimetric Results of the Phase 2 Clinical Study. *Ophthalmol Ther* 1:5.
19. Ogawa I, Imai K: (2003) Long-term effects on visual fields of unoprostone for normal-tension glaucoma. *Folia Ophthalmol Jpn* 54: 571-577.
20. Saito Y, Saeki T, Sugiyama K (2006) [Long-term effects of isopropyl unoprostone monotherapy on intraocular pressure and visual field for normal-tension glaucoma and primary open-angle glaucoma patients]. *Nihon Ganka Gakkai Zasshi* 110: 717-722.
21. Shields MB (2008) Normal-tension glaucoma: is it different from primary open-angle glaucoma? *Curr Opin Ophthalmol* 19: 85-88.
22. Tsai JC and Forbes M (2009) Medical management of glaucoma (3rdEdn), Professional Communications, Inc.