



Retinal Involvement in Systemic Lupus Erythematosus

Prabhat Vinay Nangia*, Viswanathan L, Kharel (Sitaula) R and Biswas J

Resident Doctor, Sankara Nethralaya College Road, Nungambakkam, Chennai, Tamil Nadu, India

*Corresponding author: Prabhat Vinay Nangia, Resident Doctor, Sankara Nethralaya College Road, Nungambakkam, Chennai, Tamil Nadu, India, Tel: +919884093001; E-mail: prabhatnangia@gmail.com

Received date: March 31, 2017; Accepted date: July 17, 2017; Published date: August 18, 2017

Copyright: © 2017 Nangia PV, et al. This is an open-access article distributed under the terms of the creative commons attribution license, which permits unrestricted use, distribution, and reproduction in any medium, provided the original author and source are credited.

Abstract

Aim: To report fundus findings in systemic lupus erythematosus (SLE), systemic associations and treatment outcome.

Methods: This was a retrospective case series study of 18 eyes of nine patients SLE patients who presented to the clinic from October 2002 to June 2016 at a tertiary eye care centre in south India.

Results: The mean age of presentation with ocular involvement in SLE patients was 25.56 years (16 to 36 years). The mean duration of patients' follow up was 28.08 months. The average duration of systemic disease at presentation was 46.71 ± 50.57 months. The systemic features present in all of our SLE patients, the commonest being arthritis (44.44%) and cytopenias (44.44%) followed by nephritis (22.22%) and dermal rashes (22.22%). In regards to auto antibodies, antinuclear antibody (ANA) was positive in four (44.4%) patients, anti dsDNA in two (22.2%) cases, anticardiolipin antibody (aCLAb) levels raised in one (11.1%) patient and borderline in two (18%) patients. Lupus anticoagulant was positive in one (11.1%) case and two (22.2%) cases were diagnosed to have antiphospholipid antibody syndrome (APLS). Visual impairment was present in 9/18 eyes (50%) at presentation. SLE retinopathy was seen in 14/18 eyes (77.78%) which was in the form of hard exudates, cotton wool spots, Roth spots, vascular sheathing, retinal, vitreous and subhyaloid hemorrhage, macular edema, neo-vascularisation, tractional retinal detachment, combined retinal artery and vein occlusion. One eye of one patient had SLE choroidopathy. Treatment instituted included systemic corticosteroid, immunosuppressive therapy, laser photocoagulations, and vitreo-retinal surgery. The mean final visual acuity was 0.92 ± 0.83 Log MAR units, which was slightly better than the mean visual acuity at presentation (0.96 ± 0.9 Log MAR units); however was not statistically significant ($p=0.82$).

Conclusion: Ocular fundus findings in SLE patients are not uncommon and should be examined cautiously.

Keywords: Lupus; Retinopathy; Choroidopathy; Antiphospholipid antibody syndrome; Vasculitis

Introduction

Systemic lupus erythematosus (SLE) is a multisystem disorder of autoimmune etiology, predominantly affecting women. The manifestations of SLE are vivid and the diagnosis is based on the Revised American College of Rheumatology criteria [1] and newer Systemic Lupus International Collaborating Clinic's (SLICC) criteria [2].

Though ocular manifestations does not fall among the diagnostic criteria of SLE, ocular manifestations are a marker for overall systemic disease activity and can occur in up 1/3rd of all SLE patients [3]. Ocular manifestations of lupus are due to the immune complex deposition in the blood vessels of the conjunctiva, retina, choroid, sclera, ciliary body, also in the basement membranes of the ciliary body and cornea, and in the peripheral nerves of the ciliary body and conjunctiva leading to vasculitis and thrombosis [4].

The incidence of retinal involvement in SLE is 7-26% [5] and is reported as the second most common ocular manifestation after keratoconjunctivitis sicca [6] Ushiyama et al. [7] had defined retinopathy as the presence of any of the following lesions:

hemorrhages, vasculitis (defined as sheathing of retinal arterioles and /or venules or vascular tortuosity), soft exudates, disc edema or retinal detachment. And Stafford – Brady et al. [8] added as the presence of hard exudates in a non diabetic patient without essential hypertension. Other posterior segment finding in SLE is lupus choroidopathy and lupus optic neuropathy. These fundus findings in SLE can serve as the marker of prognosis and mortality [6]. We present here a series of nine patients with SLE related retinopathy and choroidopathy.

Materials and Methods

This was a retrospective case series that reviewed the files of all consecutive SLE with posterior segment findings that was seen in uveitis clinic of a single ophthalmologist in a tertiary eye-care center from October 2002- June 2016. Approval from the ethical committee of the institution was obtained and the study adhered to the tenets of the Declaration of Helsinki.

Review of electronic database system was done identify cases of SLE. Then the SLE cases with posterior segment findings were identified and included for further analysis. Demographic profile, duration, clinical features, systemic manifestations, treatment history were documented. The diagnosis of SLE was based on the Revised

American College of Rheumatology criteria [1] and was usually established after the opinion of a rheumatologist. Complete ophthalmic evaluation including visual acuity testing, slit lamp examination, and a dilated posterior segment examination was done. Slit-lamp biomicroscopy, dilated fundus examination, and intraocular pressure (IOP) assessment was done in all cases. Ancillary investigations such as fundus fluorescein angiography, retinal optical coherence tomography and ocular ultrasonography were carried out in

selected patients Chi square test was used to measure the uniformity in visual acuity at presentation. SPSS V.18.0 was used to perform all statistical analysis and p value <0.05 was considered as statistically significant.

Results

| S No. | Age/ Sex | Skin Rash | Pleuritis | Cardiac lesions | Nephritis | Cytopenias | Arthralgias | APLS | BCVA OD | BCVA OS | Anterior segment Features |
|-------|----------|-----------|-----------|-----------------|-----------|------------|-------------|------|---------|---------|---------------------------|
| 1 | 29/F | Yes | Yes | Yes | No | Yes | Yes | Yes | 2.3 | 0.2 | Absent |
| 2 | 17/F | No | No | No | No | Yes | No | No | -0.1 | 1.7 | Absent |
| 3 | 33/F | Yes | No | No | No | Yes | Yes | No | 1.7 | 0.5 | Absent |
| 4 | 36/F | No | No | No | No | Yes | No | No | 0.3 | 2 | Absent |
| 5 | 24/M | No | No | No | Yes | No | No | Yes | 2.7 | 0.2 | OD NVI |
| | | | | | | | | | | | OS Absent |
| 6 | 18/F | No | No | No | Yes | No | No | No | 1.3 | 1.3 | Absent |
| 7 | 22/F | No | No | No | No | No | Yes | No | 1 | 1.7 | OU PEEs, |
| | | | | | | | | | | | AC cells1+ |
| | | | | | | | | | | | OS Absent |
| 8 | 16/F | No | No | No | No | No | Yes | No | 0.5 | 0 | OD AC cells1+ |
| | | | | | | | | | | | OS Absent |
| 9 | 35/F | No | No | No | No | No | No | No | 0 | 0 | Absent |

Table 1: Demographic profile, systemic and anterior segment features.

Out of 20 SLE cases seen during October 2002- June 2016, nine had posterior segment manifestations and were included for further analysis. Among these nine SLE cases, 88.89% (n=8) were female and 11.11% (n=1) were male making a female to male ratio of 8:1. Average age at presentation was 25.56 ± 7.92 years. The average duration of systemic disease at presentation was 46.71 ± 50.57 months. The systemic features present in all of our SLE patients, the commonest being arthritis and cytopenias (44.44%) each followed by nephritis and dermal rashes (22.22%) each and pleuritis and vasculitis in 11.11% each. In regards to auto antibodies, antinuclear antibody (ANA) was positive in four (44.4%) patients, Anti dsDNA in two (22.2%) cases. An Anticardiolipin antibody (aCLAb) level was raised in one (11.1%) patient and borderline in two (18%) patients. Lupus anticoagulant was positive in one (11.1%) case and a total of 2 out of 9 patients were diagnosed to have antiphospholipid antibody syndrome (APLS).

The most common presenting ocular symptoms was diminution of vision (DOV) in eight of the nine patients (88.89%), which was sudden in 27.78% and insidious in 44.44%. Best Corrected Visual Acuity (BCVA) of Log MAR 1.0 or less was seen in 9/18 eyes (50%), with the mean BCVA at presentation being 0.96 ± 0.9 Log MAR units. Diminution of vision was bilaterally asymmetrical in 7 out of 9 patients (77.7%). Anterior segment findings were present in 4 eyes (22.2%) in the form of dry eyes with bilateral punctate epithelial erosions (11.11%), and neovascular glaucoma with corneal edema along with

rubeosis iridis (5.5%). Three eyes (16.6%) had relative afferent pupillary defect Table 1.

| Retinal features | Affected eyes (n=18) |
|---|----------------------|
| No (Percentage) | |
| Retinal haemorrhage | 5 (27.78%) |
| Vitreous haemorrhage | 7 (38.89%) |
| Sub hyaloids haemorrhage | 1 (5.56%) |
| Sclerosed vessels | 4 (22.22%) |
| Sheathed vessels (Active vasculitis) | 5 (27.78%) |
| Soft exudates | 4 (22.22%) |
| Hard exudates | 2 (11.11%) |
| Optic disc pallor | 6 (33.33%) |
| Glaucomatous optic atrophy | 1 (5.56%) |
| Central retinal artery and vein occlusion | 1 (5.56%) |
| Macular edema | 4 (22.22%) |

| | |
|-------------------------------|------------|
| Tractional Retinal Detachment | 2 (11.11%) |
|-------------------------------|------------|

Table 2: Posterior segment findings in SLE cases.

The posterior segment manifestations were present in 15 of the 18 eyes (83.3%). Vitreous hemorrhage Figure 1 was present in seven eyes (38.9%), intraretinal hemorrhages in five eyes (27.8%) and sub hyaloid hemorrhage was seen in one eye (5.5%). Features of retinal vasculitis both active and healed Figure 2, were seen in eight out of 18 eyes (44.45%), five of them had sheathed vessels. Soft exudates were seen in four eyes of three patients, and hard exudates were seen in two eyes. The details of fundus findings in our SLE cases are shown in Table 2.

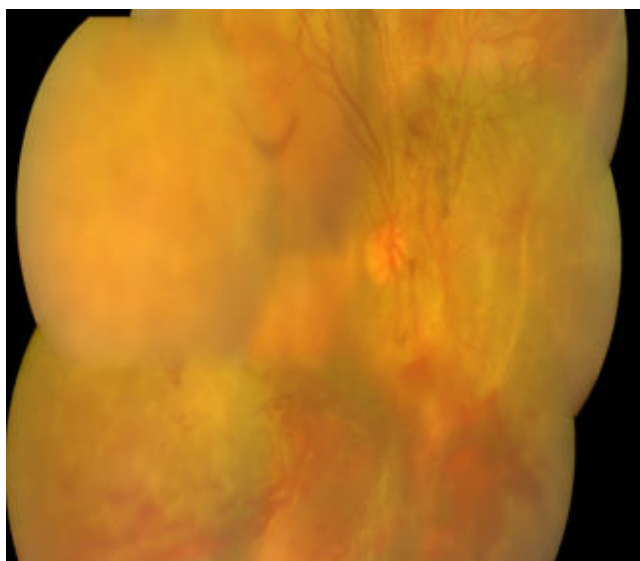


Figure 1: Retinal and vitreous haemorrhage in an SLE patient.

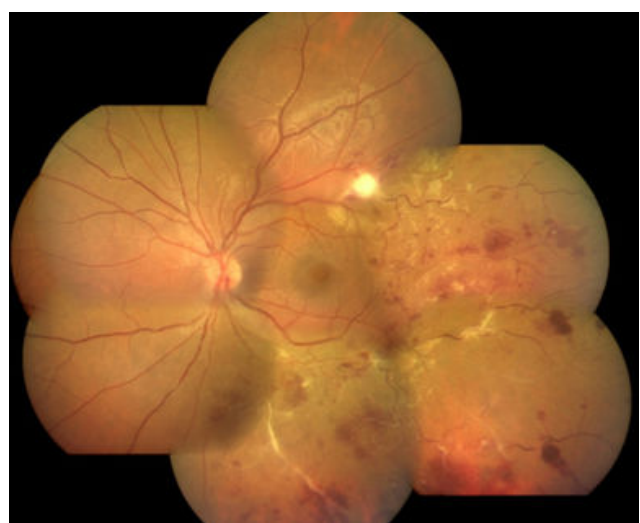

Figure 2: Retinal haemorrhages, soft exudates, sheathing, in an SLE patient.

Optic disc pallor was documented in six of 18 eyes. Additionally, one eye had glaucomatous optic atrophy secondary to iris neovascularization and neovascular glaucoma. Combined central retinal artery and vein occlusion was seen in one eye of one patient, who was a diagnosed case of antiphospholipid antibody syndrome (APLS). SLE choroidopathy was present in only one eye Figure 3.

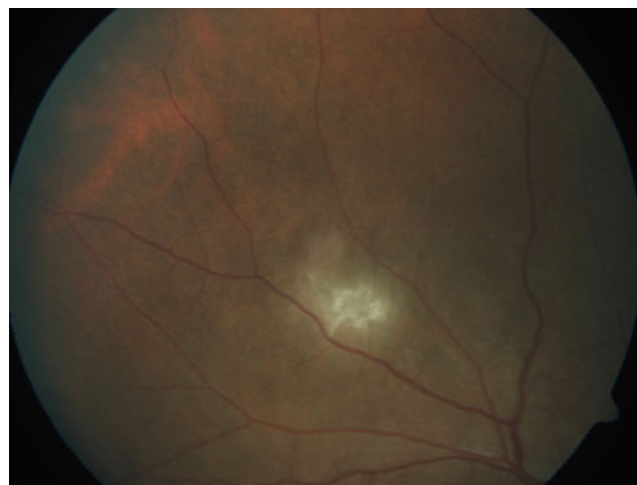


Figure 3: SLE choroidopathy in right eye with active choroiditis.

All patients were treated with systemic corticosteroids. Six out of 9 patients (66.67%) were already started on oral corticosteroid elsewhere and the remaining three cases received their first course at our institute. In addition, eight out of nine patients (88.89%) received immunosuppressant which included azathioprine (5/9 patients; 55.56%), mycophenolatemofetil (3/9 patients; 33.33%) and intravenous cyclophosphamide (1/9 patient; 11.11%).

Four eyes (22.2%) had already received prior laser photocoagulation, and at our institute laser treatment was given in four more eyes which had retinal neovascularization with recurrent vitreous hemorrhage. Hence this modality was used in 8 eyes (44.44%).

Vitreo-retinal surgery was required in four eyes of three patients during the course of follow up, of which three eyes had tractional retinal detachment and one eye had non resolving vitreous hemorrhage.

The mean duration of patients' follow up was 28.08 months. The mean final visual acuity was 0.92 ± 0.83 Log MAR units, which was slightly better than the mean visual acuity at presentation (0.96 ± 0.9 Log MAR units); however this improvement could not reach any level of statistical significance ($p=0.82$). BCVA of Log MAR 1.0 or less was seen in 9/18 eyes at final follow up.

Discussion

Ocular manifestations of systemic lupus Erythematosus are protean. Neither American College of Rheumatology Criteria [1] nor a recent diagnostic criteria formulated by the Systemic Lupus International Collaborating Clinics (SLICC) [2] have included ophthalmic manifestations as part of the diagnostic criteria. But lupus retinopathy may even be the harbinger of a potentially severe systemic flare-up [9]. Its presence is considered important, both visually and prognostically, because retinal findings in SLE parallel with the severity of systemic

inflammation and may indicate inadequate control of the systemic disease [10,11] thus a more vigorous systemic therapy is warranted in such conditions. Literatures have shown higher incidence of lupus retinopathy among hospitalized patients and is usually associated with active SLE [8].

Lupus retinopathy was first described by Bergmeister in 1929. The incidence of lupus retinopathy has been reported differently by various authors; from 10% [7] to 34.6% [12,13]. Microhaemorrhages are seen as the most common findings [8] which holds true in our case series too.

The association of Antiphospholipid syndrome (APLS) with SLE retinopathy has been described earlier). A higher incidence of antiphospholipid antibodies in SLE patients with retinal vascular disease, compared to those without [13-15], (18.1% vs. 4.4%) has been reported and in our series two patients (22.2%) had APLS of which one developed CRVO and CRAO and the second patient had neovascular glaucoma. Severe vaso-occlusive retinopathy in a female patient in the presence of antiphospholipid antibodies has been reported by Au et al. [14]. Montehermoso et al. [12] also reported statistically significant difference and higher prevalence of Antiphospholipid antibody (aPL) in patients with retinopathy compared to patients without retinopathy (77% vs. 29%; $p=0.005$). Besides, two of our patients with retinal vasculitis also had borderline anticardiolipin antibody (aCL) levels in our study.

Lupus choroidopathy is less common but usually serves as a sensitive indicator of lupus activity [16] but is frequently under-diagnosed [17] Sobrin et al. [6] have described lupus choroidopathy with multiple areas of subretinal fluid and pigment epithelial detachments and herein we had a single case of choroidopathy that presented with a choroiditis patch and localized collection of subretinal fluid, which resolved with oral steroids and azathioprine. Shimura et al. [18] reported a case of lupus choroidopathy which was treated with systemic steroids and laser photocoagulation.

Neuro-ophthalmic manifestations of SLE are seen in 3.6% in adult and 1.6% in childhood SLE patients [19] and can manifest as isolated optic neuritis, neuromyelitis optica or ischemic optic neuropathy. None of our patients were diagnosed to have any of these conditions, although disc pallor was seen in seven eyes (38.8%) in our study.

In the case series of lupus retinopathy described by Kharel et al. [13] all of the 11 (100%) patients with SLE retinopathy, all had lupus nephropathy. But the involvement of kidney in our study was only 22.22%, and arthritis and cytopenias were more common.

The control of systemic SLE is the mainstay of treatment for lupus retinopathy which can be achieved by systemic corticosteroids and immunosuppression [6] Ocular involvements may warrant topical/periocular steroid therapy, laser photocoagulation or even retinal surgeries. All of our patients received systemic corticosteroids and eight out of nine patients (88.89%) received immunosuppressant. Eight eyes (44.44%) laser photocoagulation and vitreo-retinal surgery was required in four eyes (22.22%). These modalities of treatment improved mean BCVA improved from 0.96 at baseline to 0.92 Log MAR acuity at final follow up but was not statistically significant.

Though our study is able to enlighten the vivid posterior segment manifestations in SLE patients, it has a major drawback of small sample size and the retrospective design. But life-table survival estimates have shown decreased survival in patients with SLE

retinopathy, compared to SLE patients without retinopathy [6] Hence, early identification of these fundus findings in SLE patients can aid as prognostic factor for survival. This also implies the importance of inclusion of ocular findings in the diagnostic criteria of SLE.

Conclusions

Posterior segment involvement is not an uncommon finding in SLE. Lupus retinopathy reflects systemic vascular damage so ocular fundus examination is mandatory in all SLE patients.

References

1. Hochberg MC (1997) Updating the American College of Rheumatology revised criteria for the classification of systemic lupus erythematosus. *Arthritis Rheum* 40: 1725.
2. Petri M (2009) Systemic Lupus International Collaborating Clinic (SLICC). SLICC revision of the ACR classification criteria for SLE. *Arthritis Rheum* 60: 895.
3. Read RW (2004) Clinical mini-review: systemic lupus erythematosus and the eye. *Ocul Immunol Inflamm* 12: 87-99.
4. Reddy CVFC (1994) Systemic lupus erythematosus In: Albert DM JFe, Principles and Practice of Ophthalmology. Philadelphia, WB Saunders.
5. Reddy CV, Jakobiec FA (1994) Principles and Practice of Ophthalmology. WB Saunders: Philadelphia.
6. Sobrin L, Foster CS (2000) Systemic Lupus Erythematosus Choroidopathy.
7. Ushiyama O, Ushiyama K, Koarada S, Tada Y, Suzuki N, et al. (2000) Retinal disease in patients with systemic lupus erythematosus. *Ann Rheum Dis* 59: 705-708.
8. Stafford Brady FJ, Urowitz MB, Gladman DD, Easterbrook M (1988) Lupus retinopathy. *Arthritis Rheumatology* 31: 1105-1110.
9. Sitaula R, Shah DN, Singh D (2011) The spectrum of ocular involvement in systemic lupus erythematosus in a tertiary eye care center in Nepal. *Ocul Immunol Inflamm* 19: 422-425.
10. Gold D, Morris D, Henkind P (1972) Ocular findings in systemic lupus erythematosus. *Brit J Ophthalmol* 56: 800.
11. Arevalo JF, Lowder CY, Muci-Mendoza R (2002) Ocular manifestations of systemic lupus erythematosus. *Curr Opin Ophthalmol* 13: 404-410.
12. Montehermoso A, Cervera R, Font J, Ramos-Casals M, Garcia-Carrasco M, et al. (1999) Association of antiphospholipid antibodies with retinalvascular disease in systemic lupus erythematosus. *Seminars in arthritis and rheumatism*.
13. Kharel R, Shah DN, Singh D (2016) Role of lupus retinopathy in systemic lupus erythematosus. *J Ophthalm Inflamm Infect* 6: 15.
14. Au A, O'Day J (2004) Review of severe vaso-occlusive retinopathy in systemic lupus erythematosus and the antiphospholipid syndrome: associations, visual outcomes, complications and treatment. *Clin Exp Ophthalmol* 32: 87-100.
15. Donders RC, Kappelle LJ, Derksen RH, Algra A, Horbach D, et al. (1998) Transient monocular blindness and antiphospholipid antibodies in systemic lupus erythematosus. *Neurology* 51: 535-540.
16. Nguyen Q, Uy H, Akpek E, Harper S, Zacks D, et al. (2000) Choroidopathy of systemic lupus erythematosus. *Lupus* 9: 288-298.
17. Sivaraj R, Durrani O, Denniston A, Murray P, Gordon C (2007) Ocular manifestations of systemic lupus erythematosus. *Rheum* 46: 1757-1762.
18. Shimura M, Tatehana Y, Yasuda K, Saito Si, Sasaki T, et al. (2003) Choroiditis in systemic lupus erythematosus: systemic steroid therapy and focal laser treatment. *Jpn J Ophthalm* 47: 312-315.
19. Man BL, Mok CC, Fu YP (2014) Neuro ophthalmologic manifestations of systemic lupus erythematosus: a systematic review. *Int J Rheum Dis* 17: 494-501.