

## Renal Tuberculosis: The Enigma Continues

Ruhi Khan<sup>\*</sup>, Saif Quaiser and Arun Viswanath

Jawaharlal Nehru Medical College, Aligarh, Uttar Pradesh, India

<sup>\*</sup>Corresponding author: Ruhi Khan, Jawaharlal Nehru Medical College, Aligarh, Uttar Pradesh, India, Tel: 9267522882; E-mail: [drruhi5@gmail.com](mailto:drruhi5@gmail.com)

Received date: May 19, 2015; Accepted date: Jun 09, 2015; Published date: Jun 15, 2015

Copyright: ©2015 Khan R, et al. This is an open-access article distributed under the terms of the Creative Commons Attribution License, which permits unrestricted use, distribution, and reproduction in any medium, provided the original author and source are credited.

### Abstract

Even with the best of resources tuberculosis remains one of the leading causes of morbidity and mortality in the developing countries. With the 0 by 25 initiative taken up by the International Society of Nephrology, renal tuberculosis still remains an important, albeit ignored cause of acute kidney injury in low resource settings. With proper evaluation considerable morbidity can be minimised and the quality of life of patients can be improved upon.

**Keywords:** Renal; Tuberculosis; Hydronephrosis; Acute kidney injury

### Introduction

Tuberculosis caused by *Mycobacterium tuberculosis* complex is still a major health concern in developing countries. With the advent of HIV infection, increasing number of diabetics and frequent use of immuno suppressants following organ transplantation, it is increasing in incidence even in developed countries. Among the extra pulmonary involvement of TB, renal involvement is of great significance as it is a great masquerader requiring high degree of clinical suspicion for making diagnosis. Further it represents very few treatable and easily preventable causes of chronic kidney disease (CKD). Renal TB needs to be considered in any patient with unexplained urinary tract abnormalities and urinary symptoms.

The most common causative organism causing renal TB is human tubercle bacilli *M. tuberculosis* but occasionally the bovine tubercle bacilli *M. bovis* can be responsible. The vaccine strain, Bacille Calmette Guerin [BCG], has also been the cause of renal TB as a complication of intravesical instillation of BCG for the treatment of superficial bladder cancer [1].

### Epidemiology

According to WHO world TB report 2014, there were an annual incidence of 9 million cases of TB. 1.5 million people die of the disease annually [2]. In developed countries urogenital TB accounts for 27% of extrapulmonary TB. It is the third most frequent form of extrapulmonary TB after pleural and lymphatic TB [3]. However in developing countries like India urogenital TB incidence is low accounting only 1.2% of extrapulmonary TB [4]. This wide variation in incidence is probably due to the fact that even though most of the cases of urogenital TB are in developing countries, efficient case reporting, case registries and advanced diagnostic tools for diagnosing renal TB is in developed countries. In a multi-centric study from India it was reported that the incidence of TB to be 10 to 34% in patients with various urologic diseases [5].

### Pathology

Renal involvement in TB can be part of a disseminated infection or a localized genitourinary disease [6]. The intensity of infection depends upon the infecting dose, virulence of the organism and the resistance of the host.

The kidney is one of few sites to get involved in miliary TB where miliary tubercle is seen throughout the renal substance usually starting from the cortex [1]. The lesions measure up to 3 mm in diameter and are pale white in colour. Histologically they consist of epithelioid granulomatous lesion with or without caseation. Bacilli can usually be identified microscopically within the lesions [1]. Renal function is usually normal in these patients.

When the patient is immuno-compromised, the granulomatous lesions are not well formed. Caseation is not seen. Environmental mycobacteria such as *Mycobacterium avium* Complex (MAC) may be responsible for renal lesion [7]. The lesions are more diffuse and poorly formed than miliary lesions. It consists of histiocytic cells with abundant cytoplasm and loaded with bacilli called as multibacillary histiocytosis [1].

Isolated renal TB is most often caused due to hematogenous spread of bacilli from a distant focus of infection, mostly from lungs. In most cases there is no evidence of any active infection at the parent site at the time of presentation of renal TB. However there is clinical & radiological evidence of past infection, suggesting the renal involvement is due to reactivation of bacilli within dormant lesions [8,9]. Macroscopic progression of disease is usually unilateral [3-6]. However post-mortem studies suggest that the disease is frequently bilateral [10,11].

In some patients with pulmonary or disseminated TB there is evidence of renal failure without typical miliary or localized renal lesions. In these cases biopsy showed tubulo-interstitial disease [12]. In these cases renal dysfunction is due to a combination of infection and immune mediated damage. When immunological aggression is suspected, steroids should be started early along with anti TB drugs.

### Pathogenesis

Renal TB is invariably secondary to distant foci of infection, most notably from lungs. Primary infection of kidney is rare. *M.*

*tuberculosis* bacilli are inhaled through the lungs to alveoli, where they are phagocytosed by polymorphonuclear leukocytes and macrophages. Although most bacilli are contained initially, some are carried to the regional lymph node. Eventually they reach thoracic duct, from where they get access to venous blood [13,14]. Sometimes the tuberculous lesion in lung gains access to vascular system by erosion of the wall of a vessel, usually a vein. The venous blood carries the emboli containing bacilli throughout the body. However because of fastidious growth requirements only a few organs like the kidney, fallopian tube, epididymis, bone marrow and the hindbrain can support the growth of the bacilli. In the kidney, the site of preference is renal medulla because medullary hypertonic environment impairs the phagocytic function. However the lesion usually starts from cortex [15].

### Progression of Disease

Renal TB starts with multiple tubercles in the cortex of both kidneys. However as mentioned earlier, the macroscopic progression of disease is usually unilateral. The initial lesions tends to heal either spontaneously if the person is resistant to the organism or as a result of anti-TB chemotherapy given for treating primary foci usually in lungs. Nevertheless, one or more tubercles may persist for several years and become active after several years of inactivity. Following reactivation the lesions produced are confluent epitheloid granulomas with caseous necrosis, leading to local tissue destruction and eventually rupture into the nephrons producing bacilluria without radiographic lesions [16]. The bacilli subsequently migrate into cortico-medullary junction and forms granulomas. The granulomas may coalesce, undergo necrosis and sloughing of necrosed areas produce cavities within kidneys. This disease process may invade renal medulla directly producing papillitis or can cause vascular insufficiency in renal papillae, leading to papillary necrosis. The necrosed granuloma following rupture may communicate with renal pelvi calyceal system [PCS]. Once the renal pelvis is involved, it can result in tuberculous pyelonephritis, which can evolve into pyonephrosis if untreated, also known as a "cement" or "putty" kidneys [17]. Sometimes the renal tuberculoma may not communicate with the PCS but causes displacement of calyces. The bacilli once shed into the PCS infect the wall of the calyces resulting in fibrosis with stricture formation. Early scarring may be reversible with adequate steroid treatment, but end stage fibrotic strictures are irreversible.

Finally in renal TB, sometimes obstruction may predominate resulting in hydronephrosis or hydrocalycosis due to stricture of the infundibular or calyceal neck. If parenchymal caseation, necrosis and calcification predominate, the kidney will be destroyed. Usually both the disease process co exists resulting in autonephrectomy (Figure 1) [18].

### Sequale

Renal calcification is a major sequale of renal TB [19]. Its etiology remains obscure. These calcific shadows are ill defined and irregular in outline. They are not dense and well defined as renal calculi. They usually lie in the cortex and are strong indicator of presence of renal TB. It is an unfavourable prognostic sign when non-surgical treatment is concerned. It signifies greater chance of failure of anti TB drugs and progressive deterioration of renal function. Radiographs need to be repeated every six months to assess for any increase in size of calcification in which case surgery needs to be considered.

Keratinizing squamous metaplasia may develop as a late complication of chronic inflammation and infection of renal pelvis and may persists even after chemotherapy [20]. This is a potential risk factor for development of squamous cell carcinoma in chronic cases [1].

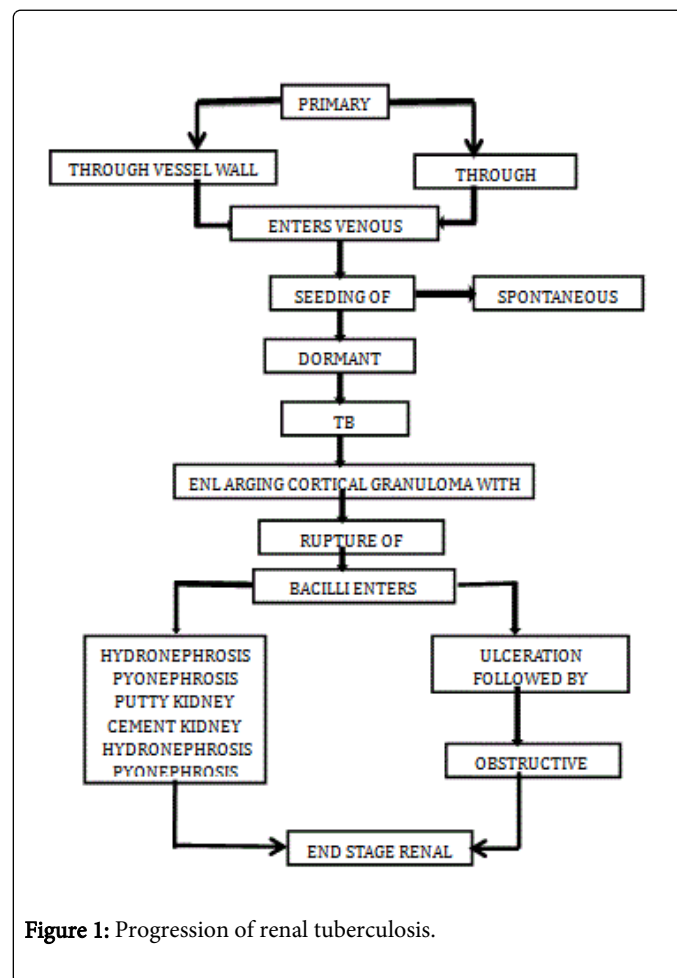


Figure 1: Progression of renal tuberculosis.

Peri renal nephritis/abscess may develop when disease process extends beyond renal capsule and involves peri-renal pad of fat [18]. Sometimes this may produce mass lesion extending outside kidney mimicking renal neoplasm [21].

Ureteral TB is an extension of the disease from the kidneys due to antegrade flow of urine, generally confined to the uretero-vesical junction. It is seen in about one half of patients with renal TB [22].

Middle one third of ureter is rarely involved. Ureteral TB produces mucosal and wall ulceration, fibrosis, stricture and calcification. The ragged saw tooth appearance of ureter in TB is because of multiple active ureteric ulcers and resultant spasm of ureter [4]. The most common site for tuberculous ureteric stricture is ureterovesical junction followed by pelviureteric junction [18]. Irregular stricture and segmental dilation results in obstruction and reflux of urine leading to hydronephrosis.

Bladder TB is secondary to renal TB in up to three quarters of cases of bladder TB. In rest of cases it is usually due to ascending infection from epididymis or secondary to instillation of BCG vaccine in to bladder for treating superficial bladder carcinoma [1]. It usually starts

from the ureteral orifice initially manifesting as superficial inflammation with bullous edema and granulation. Fibrosis of the ureteral orifice can lead to GOLF HOLE appearance of bladder with vesicoureteral reflux. In severe cases entire thickness of bladder wall is involved resulting in small contracted bladder known as THIMBLE bladder. Tubercles are rare in bladder TB; if present, they are usually seen close to ureteric orifice. Malignancy should be considered if any isolated tubercles are seen away from the ureteric orifice [23,24].

## Clinical Features

Renal TB is a great masquerador requiring high degree of clinical suspicion for making diagnosis. Usually a lengthy period *i.e.* five to twenty years separates primary TB infection from renal TB [18]. Hence renal TB is rare below 20 years of age. In a study from AIIMS, New Delhi where 241 patients with genitourinary TB were studied, the most commonly involved organ was the kidney in 130 (53.94%) cases [25]. Isolated renal TB is rarely symptomatic presenting with proteinuria, pyuria, hematuria and progressive unexplained derangement of renal function. Irritative voiding symptoms such as dysuria, nocturia, frequency and urgency of micturition predominate only when ureter and lower urinary tract is involved. Renal TB is often suspected in presence of symptoms typical of conventional bacterial UTI but repeated bacteriological cultures are either negative or patient fails to respond to usual antibacterial agents. The hallmark of renal TB is sterile pyuria followed by microscopic painless hematuria which is seen in 50% of cases. Renal colic is uncommon, occurring in fewer than 10% of patients. Constitutional symptoms such as fever, weight loss and night sweats are also unusual in renal TB. Only one third of patients with renal TB have an abnormal chest X-ray [1].

## Diagnosis

Diagnosis of renal TB is based on 1) clinical suspicion 2) microbiological confirmation of diagnosis and 3) radiological localization [26]. A full blood count, ESR, and renal function tests should be obtained in every suspected case of renal TB. In addition, if renal calcification is noted, a complete biochemical assessment of calcium metabolism needs to be performed. Monthly measurement of ESR may provide some clue regarding response to treatment (4). Tuberculin skin tests are positive in 80% of patients with renal TB [27].

Urine should be examined for pus cells, RBC's, pH and concentration. Secondary bacterial infection is noted in about 20% of patients with renal TB. The usual organism is *Escherichia coli*. Persistent sterile pyuria and hematuria in the absence of recent antibiotic treatment should prompt further evaluation for renal TB. Serial early morning urine cultures for acid fast bacilli should be obtained. Since the excretion of bacilli is intermittent atleast three, but preferably five specimen should be obtained. Each specimen should be cultured on two slopes. 1) Lowenstein-Jensen medium, 2) a pyruvate egg medium containing penicillin to identify *Mycobacterium bovis*. If cultures are positive sensitivity tests needs to be conducted. 18 Urine culture has a sensitivity of 65% and a specificity of 100%. A false-positive result on culture could be caused by the presence of *M. smegmatis* (a non-pathogenic *Mycobacterium*) in the urine [28].

Every attempt should be made to process the sample immediately after collection. Solid media mentioned earlier will yield result in 4 to 8 weeks. While newer radiometric media like BACTEC 460 will provide

results within 6 hours. Technical details of culture methods are given by Collins et al [29].

Polymerase chain reaction (PCR) technique has been applied for early diagnosis of renal TB. It has a sensitivity ranging from 87% to 100% and a specificity ranging from 92 to 99.8%. This technique yields result within 6 hours. The following PCR tests [30-32] are currently available:

- Genus specific 16s rRNA PCR test
- Species specific IS6110 PCR test
- Roche Amplicor MTB PCR test
- Amplified Mycobacterium tuberculosis Direct Detection Test (AMDT).

Imaging studies mainly include plain radiographs, USG abdomen, Intra Venous Pyelography (IVP) and CECT abdomen. Other imaging modalities like voiding cystography, retrograde/antegrade pyelography, MR urography, and arteriography may not be routinely required for making diagnosis of renal TB.

Plain X-ray KUB may show calcification in the kidneys and ureter in 50% of patients with renal TB. Ureteric calcification in renal TB is intraluminal and appears as a cast of ureter which is thickened but not dilated. This must be differentiated from ureteric calcification in schistosomiasis which are intramural and the ureter is dilated and tortuous [18].

USG abdomen has limited value as an initial investigation for detecting renal TB. However it plays a valuable role in serial monitoring of lesions detected by IVP while the patient is receiving treatment. It helps in avoiding repeated radiographic examination.

IVP is still the mainstay investigation for detection of early renal tract pathology [33]. It helps in localization of the disease besides anatomic and functional delineation. The earliest radiographically detectable lesion are changes in the minor renal calyces with loss of sharpness and blunting. Progression of the disease will cause "moth eaten" appearance of the calyces and lost calyx due to infundibular stenosis cavitating lesions that progress to the papilla and invade the collecting system, causing calyceal disruption. Findings of infundibular stenosis and multiple ureteral strictures are highly suggestive of renal TB. At later stages IVP may reveal a hydroureteronephrosis, a poorly functioning or a non-functioning kidney [34]. CT abdomen as an early investigation for renal TB is of limited value. However in patients with advanced disease CT provides better delineation of renal architecture than IVP. It also indirectly helps in comparing functional status of affected kidney when compared to the normal opposite kidney. It is highly useful in cases where there is a possibility of co-existing renal carcinoma [35].

## Cystoscopy and biopsy

Cystoscopy is rarely indicated for diagnostic purpose. Biopsy is needed if there is suspicion of malignancy. It should be done only after 4-6 weeks of medical therapy to prevent dissemination of the disease (*i.e.*, tubercular meningitis). The cystoscopic findings are reduced bladder capacity and patulous ureteral orifice. The positive bladder biopsy diagnostic of genitourinary TB can be found in up to 46% of the patients [36].

### Retrograde and antegrade pyelography

There are two indications for it. One is for ureteral catheterization to obtain urine sample for culture for localization of the disease. The other indication being to delineate the stricture of the lower ureter. Percutaneous antegrade access is required if retrograde access is unachievable or insufficient for drainage of the kidney. It also provides a route for obtaining urine samples from the renal pelvis or tuberculous cavities for culture and to assess therapeutic drug concentration at the target sites [37].

### Magnetic resonance imaging (MRI)

Useful in patients with compromised renal function, pregnancy, or allergy to contrast media. It gives good morphological details for the kidneys as well as excellent delineation of the ureters [38].

### Treatment

The primary aim of treatment is to preserve renal function and parenchyma, to make the patient non-infectious and to manage the complications. Genitourinary TB generally responds better to medical treatment than pulmonary TB because of lower mycobacterial load and better penetration of anti-TB drugs into cavity lesions of kidney and maintenance of high concentration of drugs in the urine.

**Medical Treatment:** To prevent the emergence of resistance, a multidrug regimen is preferred. Because of lengthy duration of treatment and side effects of drugs, maintaining patient compliance is difficult. Therefore, directly observed treatment is often recommended. The treatment protocol followed in India includes use of four drugs-isoniazid, rifampicin, pyrazinamide and ethambutol for 2 months (intensive phase) followed by 2 drugs-isoniazid and rifampicin for 4 months (maintenance phase). The intensive phase destroys all bacilli while persistent few near dormant bacilli are killed during maintenance phase. Details of therapy are given in detail by WHO.

In patient with multi drug resistant TB, which by definition is resistant to rifampicin and isoniazid with or without resistance to other anti TB drugs [39]. Ideally the treatment regimen should consist of four 2nd line ATT drugs, which should include at least pyrazinamide, a later generation fluoroquinolones, a parenteral agent, ethionamide (or prothionamide) and either cycloserine or PAS (p-aminosalicylic acid) if cycloserine cannot be used for some reasons [40]. Duration of therapy should be based on bacteriological response but an intensive phase of 8 months and total treatment duration of 20 months is suggested for most patients [40].

Special considerations apply to the treatment of renal TB in patients with impaired renal function. Rifampicin, isoniazid, pyrazinamide, ethionamide and prothionamide can be given safely in normal doses to these patients because they are either eliminated by bile or broken down to metabolites that are not excreted by the kidney [1]. Ethambutol and streptomycin needs to be used with caution in patients with renal impairment because they are excreted wholly via kidney. Ethambutol causes irreversible optic neuritis and reduced doses should be given according to eGFR:25 mg three times weekly if the GFR is between 50 and 100 ml/min and twice weekly if the GFR is between 30 and 50 ml/min. Streptomycin and other aminoglycosides are ototoxic and nephrotoxic and should be avoided if possible in patients with renal impairment [1].

In HIV positive patients who are receiving HAART there is a high risk of adverse drug reaction with rifampicin hence it is recommended that rifabutin be given instead of rifampicin and the duration of therapy be extended to 9 months [1]. There is an increased risk of Multi drug resistant-TB in HIV patients. In such patients ART should be started as early as possible ideally within 8 weeks of starting ATT irrespective of CD4 count [40].

### Role of steroids

Adjuvant drug treatments, such as corticosteroids have been studied in several forms of TB. In some studies, corticosteroids have been used as an adjunct to stents in ureteral stenosis, but the evidence is insufficient to justify their use in treatment of renal TB [12].

### Surgical treatment

Although chemotherapy is the mainstay of treatment in renal TB, still a significant proportion of patients require surgical intervention in the form of ablation or reconstruction especially in developing countries. No matter how normal the urinary tract may look at the first instance, a second look IV urography needs to be obtained within three to four weeks after starting ATT as tubercular lesion contracts with chemotherapy and may result in obstructive uropathy in the form of hydroureter and hydronephrosis. Indications for surgery include hydronephrosis, unresolving perirenal abscess, progressive renal insufficiency secondary to obstruction, U/L non-functional kidney complicated by pain and haemorrhage [1].

Surgical options include ablative procedures like partial or total nephrectomy or reconstructive procedures like ureteral stricture dilatation, stent placement, ureteral replacement or reimplantation, urinary diversion procedures and augmentation cystoplasty.

Indication for total nephrectomy include: 1) non-functional kidney with or without calcification complicated by pain 2) advanced disease with hypertension and ureteropelvic junction [UPJ] obstruction 3) co-existing renal carcinoma [41]. Partial nephrectomy is rarely carried out these days because of availability of effective chemotherapy however it is carried out in the following situations: 1) localized polar lesion containing calcification that has failed to respond after six weeks of intensive chemotherapy 2) an area of calcification that is slowly increasing in size and is threatening to gradually destroy the whole kidney [18].

Among conservative surgery the most commonly employed procedure is relief of ureteric obstruction by stenting or percutaneous nephrostomy. These procedures yield good results especially in patients with good cortical thickness, limited renal involvement and a GFR more than 15 ml/min [42].

### Conclusion

Renal TB is becoming common worldwide due to emergence of HIV, increasing incidence of diabetes and increasing use of iatrogenic immune suppression. But there is a worrisome under diagnosis of renal TB leading to renal insufficiency, obstructive uropathy and ESRD, all preventable complication with early diagnosis and treatment. Physicians should keep low threshold for suspecting renal TB especially in HIV and immune suppressed patients. More studies are needed to identify the main form of clinical presentation of renal TB and investigations for early confirmation of suspected cases. Most of the patients require only chemotherapy however judicious use of

surgical modalities should also be considered for optimal results. Further these patients require regular and rigorous follow up for early identification of complications.

## References

1. Eastwood JB, Corbishley CM, Grange JM (2001) Tuberculosis and the kidney. *J Am Soc Nephrol* 12: 1307-1314.
2. World Health Organisation global tuberculosis report 2014
3. Kennedy DH (1989) Extrapulmonary tuberculosis. In: Ratledge C, Stanford JL, Grange JM (eds.) *The Biology of Mycobacteria*. Academic Press, New York, pp. 245-284.
4. CTD (1998) Managing the Revised National TB Control Programme in your area. A training course (Modules 5-10). CTD, New Delhi.
5. Colabawalla BN (1978) Diagnostic evaluation in renal tuberculosis. *Indian J Surg* 40: 109-112.
6. Muttarak M, ChiangMai WN, Lojanapiwat B (2005) Tuberculosis of the genitourinary tract: imaging features with pathological correlation. *Singapore Med J* 46: 568-574.
7. Horsburgh CR Jr (1991) *Mycobacterium avium* complex infection in the acquired immunodeficiency syndrome. *N Engl J Med* 324: 1332-1338.
8. Christensen WI (1974) Genitourinary tuberculosis: review of 102 cases. *Medicine (Baltimore)* 53: 377-390.
9. Narayana A (1982) Overview of renal tuberculosis. *Urology* 19: 231-237.
10. Kretschmer HL (1930) Tuberculosis of the kidney, a critical review based on a series of 221 cases. *N Engl J Med* 202: 660-671.
11. Greenberger ME, Wershub LP, Auerbach O (1935) The incidence of renal tuberculosis in five hundred autopsies for pulmonary and extrapulmonary tuberculosis. *JAMA* 104: 726-730.
12. Mallinson WJ, Fuller RW, Levison DA, Baker LR, Cattell WR (1981) Diffuse interstitial renal tuberculosis--an unusual cause of renal failure. *Q J Med* 50: 137-148.
13. Muttarak M, ChiangMai WN, Lojanapiwat B (2005) Tuberculosis of the genitourinary tract: imaging features with pathological correlation. *Singapore Med J* 46: 568-574.
14. Eastwood JB, Corbishley CM, Grange JM (2001) Tuberculosis and the kidney. *J Am Soc Nephrol* 12: 1307-1314.
15. Yarger WE (1991) Urinary tract obstructive. In: Brenner BM, Rector FC (eds.) *The Kidney* (4th edn.) W.B. Saunders, Philadelphia/London, pp. 1768-1808.
16. Elkin M (1990) Urogenital tuberculosis. In: Pollack HM (ed.) *Clinical urography*. W.B. Saunders Company, Philadelphia, pp. 1020-1052.
17. Gibson MS, Puckett ML, Shelly ME (2004) Renal tuberculosis. *Radiographics* 24: 251-256.
18. Hemal AK (2009) Genitourinary tuberculosis. In: Sharma, Mohan editors. *Tuberculosis*. Jaypee publications 32: 463-478.
19. GOW JG (1965) RENAL CALCIFICATION IN GENITO-URINARY TUBERCULOSIS. *Br J Surg* 52: 283-288.
20. Byrd RB, Viner NA, Omell GH, Trunk G (1976) Leukoplakia associated with renal tuberculosis in the chemotherapeutic era. *Br J Urol* 48: 377-381.
21. Njeh M, Jemni M, Abid R, Karray MS, el Ouakdi M, et al. (1993) [Renal tuberculosis with pseudotumoral form: apropos of a case]. *J Urol (Paris)* 99: 150-152.
22. Harisinghani MG, McCloud TC, Shepard JA, Ko JP, Shroff MM, et al. (2000) Tuberculosis from head to toe. *Radiographics* 20: 449-470.
23. Nzerue C, Drayton J, Oster R, Hewan-Lowe K (2000) Genitourinary tuberculosis in patients with HIV infection: clinical features in an inner-city hospital population. *Am J Med Sci* 320: 299-303.
24. Pal DK (2006) Haemospermia: an Indian experience. *Trop Doct* 36: 61-62.
25. Gupta NP, Kumar R, Mundada OP, Aron M, Hemal AK, et al. (2006) Reconstructive surgery for the management of genitourinary tuberculosis: a single center experience. *J Urol* 175: 2150-2154.
26. Katoch VM (2004) Newer diagnostic techniques for tuberculosis. *Indian J Med Res* 120: 418-428.
27. Christensen W (1974) Genitourinary tuberculosis: review of 102 cases. *Medicine (Baltimore)* 53: 377-390.
28. Lenk S, Schroeder J (2001) Genitourinary tuberculosis. *Curr Opin Urol* 11: 93-98.
29. Collins CH, Grange JM, Yates MD (1997) *Tuberculosis Bacteriology, Organisation and Practice* (2nd edn.) Butterworth Heinemann, Oxford.
30. D'Amato RF, Hochstein LH, Colaninno PM, Scardamaglia M, Kim K, et al. (1996) Application of the Roche Amplicor *Mycobacterium tuberculosis* (PCR) test to specimens other than respiratory secretions. *Diagn Microbiol Infect Dis* 24: 15-17.
31. Hernandez A, Bergmann JS, Woods GL (1997) AMPLICOR MTB polymerase chain reaction test for identification of *Mycobacterium tuberculosis* in positive Difco ESP II broth cultures. *Diagn Microbiol Infect Dis* 27: 17-20.
32. Shah S, Miller A, Mastellone A, Kim K, Colaninno P, et al. (1998) Rapid diagnosis of tuberculosis in various biopsy and body fluid specimens by the AMPLICOR *Mycobacterium tuberculosis* polymerase chain reaction test. *Chest* 113: 1190-1194.
33. Valentini AL, Summaria V, Marano P (1998) Diagnostic imaging of genitourinary tuberculosis. *Rays* 23: 126-143.
34. Premkumar A, Lattimer J, Newhouse JH (1987) CT and sonography of advanced urinary tract tuberculosis. *AJR Am J Roentgenol* 148: 65-69.
35. Benckekroun A, Lachkar A, Soumana A, Farih MH, Belahnech Z, et al. (1998) Urogenital tuberculosis: 80 cases. *Ann Urol (Paris)* 32: 89-94.
36. Negi SS, Khan SF, Gupta S, Pasha ST, Khare S, et al. (2005) Comparison of the conventional diagnostic modalities, bactec culture and polymerase chain reaction test for diagnosis of tuberculosis. *Indian J Med Microbiol* 23: 29-33.
37. Mapukata A, Andronikou S, Fasulakis S, McCulloch M, Grobbelaar M, et al. (2007) Modern imaging of renal tuberculosis in children. *Australas Radiol* 51: 538-542.
38. Chaudhary H, Mandhani A, Dubey D, Srivastava A, Kapoor R, et al. (2004) Is contra-lateral renal involvement in genitourinary tuberculosis primary? *Indian J Urol* 20: 19.
39. Central TB Division (2012) Revised National Tuberculosis Control Programme. Guidelines on Programmatic Management of Drug Resistant TB (PMDT) in India. Central TB Division, Directorate General of Health Services, Ministry of Health and Family Welfare, New Delhi.
40. Guidelines for the programmatic management of drug resistant TB 2011 update: WHO. ISBN 978 92 4 150158 3.
41. Flechner SM, Gow JG (1980) Role of nephrectomy in the treatment of nonfunctioning or poorly functioning unilateral tuberculous kidney. *J Urol* 123: 822-825.
42. Ramanathan R, Kumar A, Kapoor R, Bhandari M (1998) Relief of urinary tract obstruction in tuberculosis to improve renal function. Analysis of predictive factors. *Br J Urol* 81: 199-205.