

Reharmonize: Aesthetic Modalities Founded on the Concepts of Restoring, Reshaping, and Resurfacing for the Comprehensive Treatment of Millennials

Vincent Wong¹, Dennis Malvin Hernandez Malgapo^{2*}

¹Vindoc Aesthetics Academy, London SW3 1NH, United Kingdom; ²Department of Family and Community Medicine, University of the Philippines, Manila, Philippine

ABSTRACT

Background: Non-surgical minimally invasive procedures, typically in combination, are now becoming the norm. The integrated use of these modalities can be offered to millennial patients, who have unique demands and aesthetic goals.

Objective: We aimed to demonstrate the effects of Definissee™ Fillers, Definissee™ Threads and Definissee™ Peel Program in combination to treat two millennials, one female and one male.

Case description: The male subject had noticeable change in his facial proportions with correction of hollows over the malar and suborbital areas and a more prominent chin with the help of both Definissee™ Fillers and Definissee™ Threads (double needle and free floating). There was also noticeable improvement in the pigmentation with a more even and clearer skin tone after Definissee™ Lightening Peel application. The patient verbalized a high level of satisfaction with the effects of the treatment overall.

The female subject had a noticeable correction of the prominence on her nasal bridge. There was a slightly pronounced lateral and upward lifting of the cheeks. Her uneven pigmentation was also seen to diminish following Definissee™ Peel Program. She was likewise very satisfied and happy with the result of her treatment.

Conclusion: The prejuvenation effect of a combination of minimal invasive procedures provides an optimal aesthetic option for millennials. The results obtained confirm the importance of the reharmonize approach to male and female aesthetics. And this is accomplished by working from deep to superficial facial, with satisfactory and long-lasting aesthetic outcomes.

Keywords: Combination aesthetic treatment; Millennials; Prejuvenation; Soft tissue fillers; Bioabsorbable suspension threads; Chemical peel; Male and female aesthetics

INTRODUCTION

Facial aging happens because of multiple changes occurring concurrently in the skin, the adipose tissue, muscles, ligaments, and the bone. Hence, targeting these layers with combined interventions has become the standard of care in medical aesthetics. Minimally invasive procedures (MIPs), such as using soft tissue fillers, bioabsorbable suspension threads and chemical peels for skin resurfacing, have become popular and now represent nearly 90% of aesthetic interventions [1]. MIPs can be done as day procedures with minimal downtime, are relatively affordable, and have remarkably noticeable results [2].

As millennials (individuals born between 1981 and 1996) have gradually joined the workforce, they have become the fastest growing market of patients seeking MIPs. Millennials are representative of that market of individuals who are invested in their image (ie, the most photographed generation) more so than previous generations. To them, keeping young is a part of self-care and overall wellbeing-recognizably, this generation defines aging gracefully as prevention of untimely signs of aging. Their goal is not to reverse aging, but to maintain a youthful appearance and delay its onset. A current trend referred to as 'prejuvenation' or the prevention of aging through the process of rejuvenation is now becoming prominent in multiple

Correspondence to: Malgapo DMH, Department of Family and Community Medicine, University of the Philippines, Manila, Philippine, E-mail: dmhmalgapo@hotmail.com

Received: April 23, 2021; **Accepted:** May 07, 2021; **Published:** May 14, 2021

Citation: Wong V, Malgapo DMH (2021) Reharmonize: Aesthetic Modalities Founded on the Concepts of Restoring, Reshaping, and Resurfacing for the Comprehensive Treatment of Millennials. J Clin Exp Dermatol Res. 12:562.

Copyright: © 2021 Wong V, et al. This is an open-access article distributed under the terms of the Creative Commons Attribution License, which permits unrestricted use, distribution, and reproduction in any medium, provided the original author and source are credited.

publications [3]. In this paper, we describe the restore, reshape, and resurface approach—the ‘reharmonize’ system—to achieve rejuvenation in two millennials.

Achieving reharmonization considers the young patient’s facial proportions without necessarily making everyone look the same, but rather meeting those ‘ideal’ proportions that are considered aesthetically pleasing. There should be complete understanding of their anatomy, physiology, and age-appropriate aesthetic needs (i.e., in a multi-layer, multi-modality approach) when treating them while maintaining the individuality of each face [4].

Restoring facial structures can be done by infiltrating soft tissue fillers in to enhance certain facial features. Certain ranges, such as Definissee™ Fillers, are composed of cross-linked hyaluronic acid developed through the proprietary XTR™ technology (eXcellent Three-dimensional Reticulation), which employs a controlled three-step process (pre-treatment, crosslinking and purification). Fillers manufactured with XTR™ technology have been shown to have characteristic rheological, crosslinking and biophysical factors that provide this range durable and predictable results [5]. Moreover, because it can achieve long-term and prominent tissue projection using only a small amount of product, it may appeal to the practical and budget conscious millennial [3-5]. Each variant possesses distinct properties. Definissee™ Touch is used to correct moderate-to-deep facial wrinkles and folds and increase lip volume [6]. Definissee™ Restore can correct deeper wrinkles and folds, increase or restore facial volume and remodel facial contours [6]. Lastly, Definissee™ Core is used for facial contour redefinition to correct mid face volume deficit, help make individual features more prominent, and shape the contours of the face [6].

Reshaping or lifting of facial tissues is a critical part of the rejuvenating process. Because of its straightforward use and versatility, suspension threads have been used by many aesthetic surgeons and dermatologists for the restoration of three-dimensional facial topography that appears youthful [7]. Through the process of mechanotransduction (Figure 1), or the altering of biological processes related to skin regeneration using mechanical forces, soft tissue threads have been documented to produce a multitude of molecules and initiate multiple signaling pathways that enhance cellular function and repair [8,9].

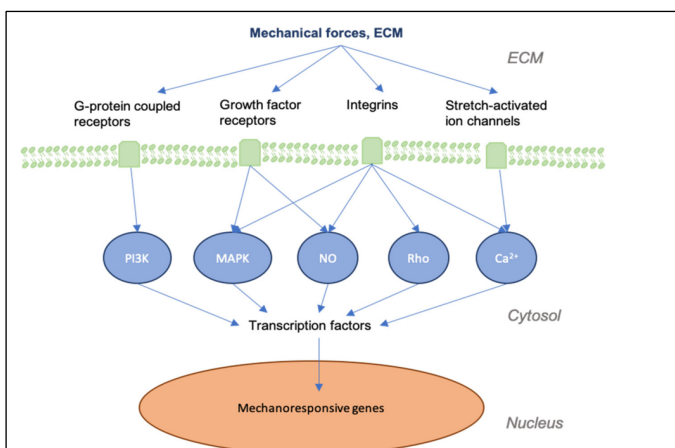


Figure 1: Stretching the skin leads to expansion of the dermal matrix, opening ion channels, receptors, and mechanotransducers; this process leads to a cascade of events leading to tissue regeneration [9].

Definissee™ Threads are bioabsorbable, monofilament, bar bed suspension threads comprising poly-L-lactic acid-co-ε-caprolactone or PLCL, which are similar to materials used in absorbable surgical sutures for wound closure [10-12]. The threads can be used to lift skin, enhance facial shape and the three-dimensional repositioning of superficial fat pads.

These can be considered as an alternative to or as an adjunct to highly invasive face lifting procedures. Their distinctive mechanical properties and anchoring structures provide immediate and long-lasting facial contouring [13].

Some Definissee™ Threads have bidirectional and convergent barbs that contain two needles seen from end to end while others have unidirectional barbs. Definissee™ double needle threads and free-floating threads come with convergent bidirectional spines.

These threads are typically used to reposition the inferior jaw fat compartment, redefine the mandibular angle and to help in the transverse repositioning of the soft tissue in the pre-auricular area. The Definissee™ free floating threads come without needles and, using a cannula for insertion, are used for soft tissue repositioning of the malar and cheekbones areas, and with an additional lifting action on the nasolabial folds.

The unidirectional barbed Definissee™ anchorage threads are used for sagittal repositioning of the malar area and for lifting of the nasolabial folds. The combination of technical features of Definissee™ Threads allows for a two step lifting mechanism: An immediate lifting effect, which is due to the mechanical action produced by the threads, and a delayed lifting effect, which is due to histological changes (ie, fibrosis that appears along the length of the thread) [10,14].

The bioabsorbability, biocompatibility and tissue integration and resorption of these threads in skin tissue has been documented to last up to 18 months after insertion in histological tissue samples [12].

When used together with fillers, threads can provide volumetric and mechanical lifting/repositioning as well as tightening effects that are more prominent than when used alone.

The volume-filling effect of fillers enhance tissue projection and myomodulation via the ‘fulcrum effect’ [15], while the threads prevent the pseudo-ptosis of the face due to changes in the distribution of adipose tissue in the fat pads.

Resurfacing to reveal clearer and finer skin can be accomplished with chemical peels such as the Definissee™ Peel Program. This three-step system acts on multiple layers of the skin and was developed to correct hyperpigmentation and uneven skin tone as a result of sun damage.

The product consists of the following exfoliating substances: salicylic acid and pyruvic acid. Salicylic acid as the main components of this system carries out an effective keratolytic action in the superficial layers (stratum corneum) of the

epidermis, allowing for greater penetration of the pyruvic acid which works by ablating the stratum corneum and separating the dermo-epidermal junction leading to reduction in epidermal thickness and by stimulating collagen, elastic fiber and glycoprotein deposition in the papillary dermis [16].

This important action synergy of its components has made it possible to reduce the use concentration of the components themselves and consequently to limit damage to the treated skin structures.

The Definisse™ Classic Peel is indicated superficial actinic-type wrinkles, photo-aging lesions (including actinic-type wrinkles, lentigo, keratosis), seborrheic skin, comedonal acne, post-acne skin lesions, such as post-inflammatory hyperpigmentation and acne-scar, and as an aid in the prevention of papular pustular acne [17].

The Definisse™ Lightening Peel has additional two ingredients to lighten the skin spots due to melanin hyperpigmentation: Diacetyl boldin (Lumiskin) whitening agent used for treatment of pigmentary disorders and undecylenoyl phenylalanine (Sepiwhite) alpha-melanocyte-stimulating hormone (MSH) receptor antagonist which may act in reducing melanin production [18-20] for reduction of hyperpigmentation by altering melanin production, is indicated for hypermelanosis, melasma, pigmentation and photo-aging spots [2,21].

We aimed to show the clinical effectiveness of using the combined aesthetic modalities of Definisse™ Fillers to restore, Definisse™ Threads to reshape and the Definisse™ Peel Program to resurface, each a crucial part of the reharmonize treatment strategy.

CASE SERIES

This paper includes one female and one male subject. After a pre-clinical evaluation and counselling session, and after signing their informed consent forms, each patient was treated with the following sequence of treatments:

- Definisse Filler for the purpose of restoring facial volume and reshape balance facial contour.
- Definisse Threads for reshaping the facial contour reshaping through three-dimensional soft tissue repositioning.
- Definisse Peel Program for a multi-layer skin resurfacing.

The first subject was a 24-year-old male who had a chief complaint of a 'gaunt appearance' and 'dark spots' on his malar areas. He was treated as follows: Definisse™ Core was injected over the zygoma (0.5 mL per side), midface (0.6 mL per side), chin (1 mL) and preauricular region (0.5 mL per side), Definisse™ double needle threads using the Oval Reshaping-Vertical technique (OR-V) (Figure 2) [12], were inserted, and Definisse™ Lightening Peel was used to correct hyperpigmentation (Figure 3A).

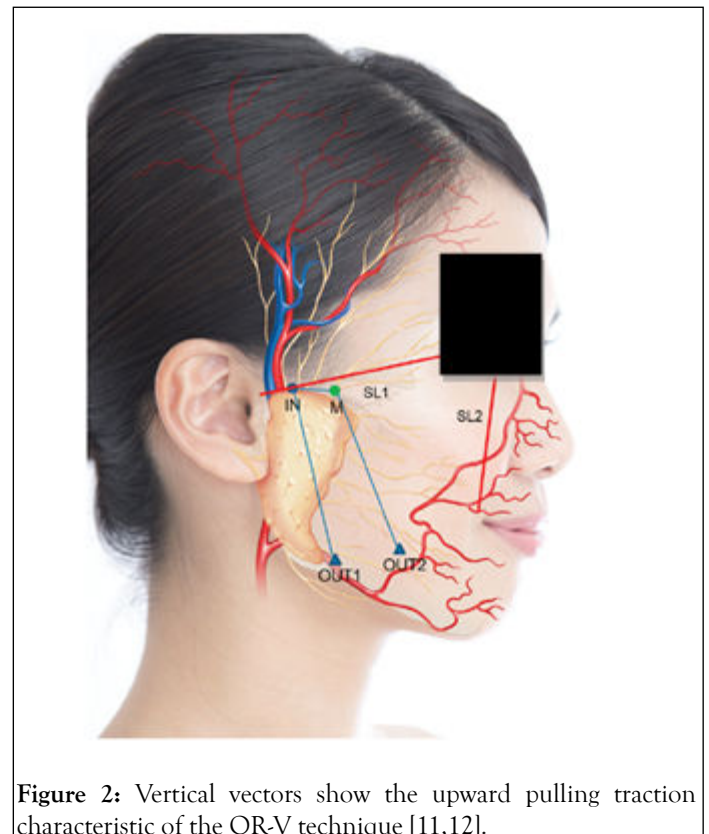


Figure 2: Vertical vectors show the upward pulling traction characteristic of the OR-V technique [11,12].

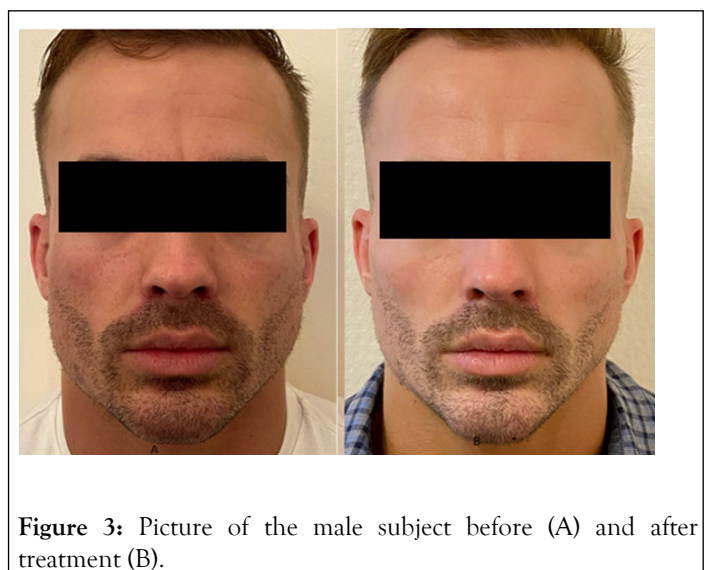


Figure 3: Picture of the male subject before (A) and after treatment (B).

The second subject was a 22-year-old female whose chief complaint was 'drooping cheeks' and 'dull' skin. The patient was treated as follows: Definisse™ Restore was applied onto the nose (0.9 mL), Definisse™ Core to the chin (1 mL), free floating threads to cheeks using the Soft Tissue Reshaping (STR) technique (Figure 4) [12] and Classic Peel were done to address premature photo-aging. Photos were taken before and after the treatment (Figure 5A).

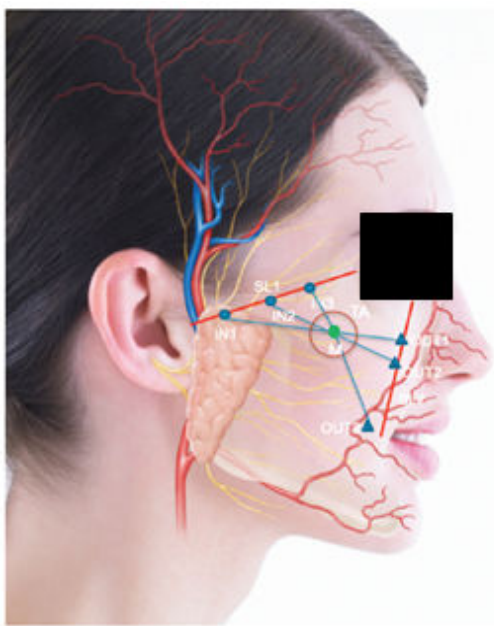


Figure 4: The STR technique improves zygomatic projection through placement in strategic areas around the zygomaticomalar area [10,12].



Figure 5: Picture of the female subject before (A) and after treatment (B).

RESULTS AND DISCUSSION

As can be seen in the after photos, the patients had noticeable enhancements in the shape and structure of the face achieving an improved version of themselves through prejuvenation. The male subject had visually apparent change in his facial proportions with correction of hollows over the malar and suborbital areas and a more prominent chin with the help of both Definissee™ Fillers and Threads. He appears to have a more chiseled appearance owing to the combined effects of the thread and fillers. There was also noticeable improvement in the pigmentation with a more even and clearer skin tone after Definissee™ Lightening Peel was applied. The patient expressed a high level of satisfaction with the effects of the treatment overall.

The female subject had a noticeable correction of the prominence on her nasal bridge. There was a slightly pronounced lateral and upward lifting of the cheeks, an enhancement that has been purely accomplished with threads. Her uneven pigmentation was also seen to diminish following

the chemical peel. She was likewise happy with the result of her treatment.

We observed, and this confirms findings from literature, that with a small amount of Definissee™ Fillers can be used to achieve prominent tissue projection [3,5]. It is worth noting that Definissee™ Fillers come in glass syringes allowing for better haptic grip, minimal risk for plastic contamination [22], better stability and preservation of the products [23] with the additional benefit of reducing plastic waste [24]. It also comes with Terumo™ needles (CE 01972 × 30G ½" thin wall) that are designed for ease of use for clinicians as well as optimal comfort for the patient.

The efficacy of PLCL threads for soft tissue repositioning has been well documented and its safety profile, well characterized [12]. Its effects are expected to last for over 18 months and has been shown to have good tissue integration in a number of studies [13,14,25]. It is fast-growing in popularity and is expected to be incorporated in many combinations in the future.

The Definissee™ Peel Program or its component Classic Peel and Lightening Peel were shown to provide satisfactory skin tone correction and can be used in combination with other deeper aesthetic modalities for various dermatological conditions. It can be used to promote exfoliation, renewal of the superficial layers of the skin, and to address more superficial skin concerns to improve skin surface quality.

CONCLUSION

The results obtained confirm the importance of combining aesthetic modalities-through the reharmonize approach (i.e., re. By working from deep to superficial facial layers, with focus on the needs of the patients, we can offer them more satisfactory aesthetic outcomes. We also confirmed that our multi-modalities approach is an exceptional means to achieve the aesthetic and economic demands of millennial patients.

CONFLICT OF INTEREST

There is no conflict of interest to be reported by any of the authors.

REFERENCES

1. De Melo F, Carrijo A, Hong K, Trumbic B, Vercesi F, Waldorf HA, et al. Minimally invasive aesthetic treatment of the face and neck using combinations of a PCL-based collagen stimulator, PLLA/PLGA suspension sutures, and cross-linked hyaluronic acid. *Clin Cosmet Investig Dermatol*. 2020;13:333-334.
2. Wong V. Resurface, retone and reboot: A multi-modality approach for prejuvenation of millennial patients. *J Clin Exp Dermatol Res*. 2021;8(1):1-3.
3. Mobayed N, Nguyen JK, Jagdeo J. Minimally invasive facial cosmetic procedures for the millennial aesthetic patient. *J Drugs Dermatol*. 2020;19(1):100-103.
4. Bonati LM, Fabi SG. Treating the young aesthetic patient: Evidence-based recommendations. *J Drugs Dermatol*. 2017;16(6):S81-S83.
5. Salti G, Fundarò SP. Evaluation of the rheologic and physicochemical properties of a novel hyaluronic acid filler range with excellent three-

- dimensional reticulation (XTR™) technology. *Polymers*. 2020;12(8):1644.
6. Wong V. Serving face. *PMFA*. 2021;2:3-4.
 7. Coleman SR, Grover R. The anatomy of the aging face: Volume loss and changes in 3-dimensional topography. *Aesthet Surg J*. 2006;26(1):S4-S9.
 8. Huang C, Ogawa R. Mechanotransduction in bone repair and regeneration. *The FASEB J*. 2010;24(10):3625-3632.
 9. Kuehlmann B, Bonham CA, Zucal I, Prantl L, Gurtner GC. Mechanotransduction in wound healing and fibrosis. *J Clin Med*. 2020;9(5):1423.
 10. Berardesca E, Cirillo P, Fundaro SP, Hau KC, Moon HJ, Salti G, et al. Reshaping with barbed threads. *Edizioni Minerva Medica*. 2020.
 11. Fundaro SP, Goh CL, Hau KC, Moon H, Lao PP, Salti G, et al. Expert consensus on soft-tissue repositioning using absorbable barbed suspension double-needle threads in Asian and Caucasian patients. *J Cutan Aesthet Surg*. 2021;14(1):1-13.
 12. Wong V. The Science of absorbable poly (L-Lactide-Co-ε-Caprolactone) threads for soft tissue repositioning of the face: An evidence-based evaluation of their physical properties and clinical application. *Clin Cosmet Investig Dermatol*. 2021;14:45-54.
 13. Kalyan R, Rafiq N, Wong V. The efficacy of polycaprolactone threads in zygomatic and mandibular lifting: Consecutive study from a single practitioner's experience. *Int J Clin Exp Dermatol*. 2015;1(1):1-3.
 14. Savoia A, Accardo C, Vannini F, Di Pasquale B, Baldi A. Outcomes in thread lift for facial rejuvenation: A study performed with happy lift™ revitalizing. *Dermatol Ther*. 2014 ;4(1):103-114.
 15. De Maio M. Myomodulation with injectable fillers: An innovative approach to addressing facial muscle movement. *Aesthetic Plast Surg*. 2018;42(3):798-814.
 16. O Connor AA, Lowe PM, Shumack S, Lim AC. Chemical peels: A review of current practice. *Australas J Dermatol*. 2018;59(3):171-181.
 17. Truchuelo M, Cerdá P, Fernández LF. Chemical peeling: A useful tool in the office. *Actas DermoSifiliogr*. 2017;108(4):315-322.
 18. Pratchyapurit WO. Combined use of two formulations containing diacetyl boldine, TGF-β1 biomimetic oligopeptide-68 with other hypopigmenting/exfoliating agents and sunscreen provides effective and convenient treatment for facial melasma. Either is equal to or is better than 4% hydroquinone on normal skin. *J Cosmet Dermatol*. 2016;15(2):131-144.
 19. Bissett DL, Robinson LR, Raleigh PS, Miyamoto K, Hakozaki T, Li J, et al. Reduction in the appearance of facial hyperpigmentation by topical N-undecyl-10-enoyl-L-phenylalanine and its combination with niacinamide. *J Cosmetic Dermatol*. 2009;8(4):260-266.
 20. Millikin C, Laughlin LT, Robinson M, Reichling T. Undecyl-10-enoyl-phenylalanine (Sepiwhite) provides additional benefits to the cosmetic ingredients N-acetyl glucosamine and niacinamide in the regulation of melanin production in vitro. *J Am Dermatol*. 2008;58(2):AB118.
 21. Smit N, Vicanova J, Pavel S. The hunt for natural skin whitening agents. *Int J Mol Sci*. 2009;10(12):5326-5349.
 22. Cheng YY, Yu JZ. Minimizing Contamination from Plastic Labware in the Quantification of C16 and C18 Fatty Acids in Filter Samples of Atmospheric Particulate Matter and Their Utility in Apportioning Cooking Source Contribution to Urban PM2.5. *Atmosphere*. 2020;11(10):1120.
 23. Wiwanitkit V. Glass syringes are better than plastic for preserving arterial blood gas for oxygen partial pressure determination: An explanation based on nanomaterial composition. *Int J Nanomedicine*. 2006;1(2):223.
 24. Ilyas M, Ahmad W, Khan H, Yousaf S, Khan K, Nazir S, et al. Plastic waste as a significant threat to environment—a systematic literature review. *Rev Environ Health*. 2018;33(4):383-406.
 25. Wong V. Efficacy of bidirectional barbed polycaprolactone threads in repositioning of soft tissue in the neck. *J Clin Exp Dermatol Res*. 2017;8(1):19.