

## Regional Pericarditis Mimicking Remyocardial Infarction after Primary Percutaneous Intervention

Asghar Mohamadi\*

Department of Cardiology, Lorestan University of Medical Sciences, Khorramabad, Iran

### ABSTRACT

Localized pericarditis due to ST elevation in local leads might be mimic myocardial infarction and this is a important scenario that need to early evaluation to rule out of myocardial infarction. we describe a patient who presented chest pain and ST elevation after primary PCI that after workup the localized pericarditis was confirmed.

**Keywords:** Regional pericarditis; Myocardial infarction; Primary percutaneous intervention

### INTRODUCTION

Pericarditis is the most common cause of chest pain following MI, but the frequency of post infarct pericarditis is unclear and ranges from 7 to 41% [1]. Regional pericarditis has been described in several settings, but occurs most frequently after transmural myocardial infarction [2]. While the diagnosis remains elusive, it must be considered in all patients with recurrent chest pain following acute MI. Pericarditis classically presents with positional chest pain, a pericardial friction rub, diffuse ST segment elevation and PR depression, but regional ECG changes associated with infarction-associated pericarditis sometimes exist. There are no ECG criteria to diagnose regional pericarditis and only a few publications have addressed this condition. While there are no ECG criteria to diagnose infarct is associated regional pericarditis, 2 a typical T wave patterns is the evolution have been described with a sensitivity and specificity of 100% and 77%, respectively [3,4]. In contrast to the normal pattern seen during AMI in which there are tall, peaked T wave during the hyperactive phase that become inverted within 48 hours and remain inverted for days, weeks, or even indefinitely, is post-infarct regional pericarditis is associated with the following 2 atypical T wave patterns: Persistently positive T waves for 48 hour after symptom onset, and 2. Premature and gradual reversal of inverted T waves to persistently upright T waves. In this paper we aimed to report a case with localized pericarditis that mimic inferior myocardial infarction.

### CASE DESCRIPTION

A 53 year old female with known hypertension and diabetes mellitus and diarrhoea from 1 month ago that became worse and with new epigastric pain referred to emergency department from a medical clinic with abnormalities in ECG as ST elevation in inferior leads. The patient had no chest pain complaint. Her ECG was suggestive of an inferior infarct. The patient was taken emergently to catheterization lab. Coronary angiography revealed a complete occlusion of the mid RCA. The patient underwent successful RCA percutaneous coronary intervention. The patient was also treated with antiplatelet therapy. Lab results of the patients are as following: troponin (qualitative rapid method)=positive, WBC=10200/micL, Hb=12.5 g/dL, those are platelet=150000/micL, hematocrit=36.2%, MCV=83.8 fL, fiction BUN=23 mg/dL, creatinine=1.1 mg/dL (Figure 1).

Within 24 hours of her admission, the patient began experiencing severe chest pain with persistent ST segment elevation in the inferior leads. Repeat coronary angiography was done and had no change from the previous study; and the RCA stent remained patent. But her chest pain remained with no response to treatment. Transthoracic Echocardiography (TTE) in revealed hypokinesis of the inferior and posterior walls, mild left ventricular dysfunction, no pericardial effusion and EF=40%. Its her cardiac enzymes had no reevaluation. According to these are to symptoms, ECG changes and TTE findings, angiography friction restudy, a diagnosis of regional pericarditis was made despite the absence of a pericardial rub, which is fleeting in nature and they frequently overlooked. So she received aspirin with anti-inflammatory doses and NSAID. In next day's her chest pain

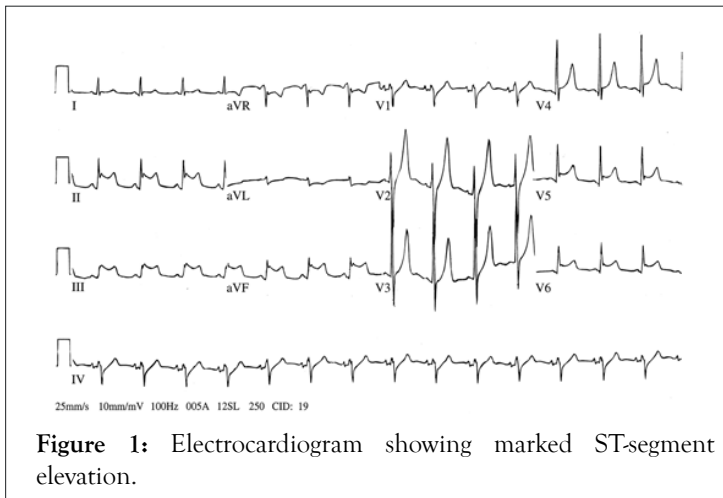
**Correspondence to:** Asghar Mohamadi, Department of Cardiology, Lorestan University of Medical Sciences, Khorramabad, Iran, E-mail : drmazhin@gmail.com

**Received date:** June 09, 2021; **Accepted date:** June 23, 2021; **Published date:** June 30, 2021

**Citation:** Mohamadi A (2021) Regional Pericarditis Mimicking Remyocardial Infarction after Primary Percutaneous Intervention. J Clin Exp Cardiol. 12: 689

**Copyright:** © 2021 Mohamadi A. This is an open-access article distributed under the terms of the Creative Commons Attribution License, which permits unrestricted use, distribution, and reproduction in any medium, provided the original author and source are credited.

relieved and she became asymptomatic and ECG changes had normalized.



**Figure 1:** Electrocardiogram showing marked ST-segment elevation.

## DISCUSSION

Early assessment of electrocardiographic findings remains the basic evaluation for diagnosis of patients suspected to myocardial infarction [5]. ST elevation has several differential they diagnosis including myocardial infarction and pericarditis that myocardial infarction presents with localized STElevation while pericarditis presents with diffuse STElevation [6] in contrast to classic pericarditis that documented with diffuse ST elevation, regional pericarditis appear with focal STElevation and this feature can be difficult to differentiate from myocardial infarction [7]. Post infarction regional pericarditis is the most common cause of regional pericarditis that occurred in our case while in some cases regional pericarditis occurred after cardiac ablation and abdominal surgery [8,9] in similar in our case the diagnosis of pericarditis was difficult because the ECG showed the reciprocal changes in high lateral leads and this finding is more in favor of myocardial infarction the second challenge of diagnosis is that two other criteria for diagnosis of pericarditis including pericardial effusion and friction rub was absent thus the diagnosis was made only based on chest pain and ECG findings of course these two presentation are often not present in acute pericarditis. This should not diminish our doubts about diagnosis of acute pericarditis. To date there is no specific ECG

criteria for diagnosis of regional pericarditis and some proposed criteria are not common in clinical setting thus the strong clinical suspicion can be helpful to diagnosis of this problem.

## CONCLUSION

The authors suggest that it is important to cardiologists to familiar with various pericardial presentations and considered in patients with recurrent or persistent chest pain in the setting of atypical T wave evolution and persistent ST segment elevation. It is also rational to do catheterization to rule out myocardial infarction in these patients.

## REFERENCES

1. Aydinalp A, Wishniak A, Roguin N. Pericarditis and pericardial effusion in acute ST-elevation myocardial infarction in the thrombolytic era. *Isr Med Assoc J.* 2002;3:181-183.
2. Dorfman TA, Aqel R. Regional pericarditis: A review of the pericardial manifestations of acute myocardial infarction. *Clin Cardiol.* 2009;32(3):115-120.
3. Oliva PB, Hammill SC, Edwards WD. Electrocardiographic diagnosis of postinfarction regional pericarditis. Ancillary observations regarding the effect of reperfusion on the rapidity and amplitude of T wave inversion after acute myocardial infarction. *Circulation* 1993;88(3):896-904.
4. Oliva PB, Hammill SC, Edwards WD. The electrocardiographic diagnosis of regional pericarditis in acute inferior myocardial infarction. *Eur Heart J.* 1993;14(12):1683-1691.
5. Alhammouri AT, Omar BA. Regional pericarditis mimicking inferior myocardial infarction following abdominal surgery. *J Med Case Rep.* 2014.
6. Youssef G, Khouzam S, Sprung J, Bourke DL. Regional pericarditis mimicking myocardial infarction. *Anesthesiology: J Am Soc Anes.* 2001;95(1):261-264.
7. Rechenmacher S, Jurewitz D, Southard J. Barking up the wrong tree: Regional pericarditis mimicking STE. *Am J Med.* 2013;126(8):679-681.
8. Doulaptsis C, Goetschalckx K, Masci PG. Assessment of early post-infarction pericardial injury by CMR. *JACC: Cardiovascular Imaging.* 2013;6(3):411-413.
9. Orme J, Eddin M, Loli A. Regional pericarditis status post cardiac ablation: A case report. *N Am J Med Sci.* 2014;6(9):481.