

Recurrent Complete Atrioventricular Block During Cisplatin Infusion: A Case Report

Turkay Ozcan^{1*}, Cirit A¹ and Kiykim A²

¹Mersin University, Faculty of Medicine, Department of Cardiology, Turkey

²Mersin University Faculty of Medicine, Department of Internal Medicine, Division of Nephrology, Turkey

Abstract

Cisplatin is one of the most effective chemotherapeutic agents used in the treatment of malignancies. The clinical use of cisplatin is limited by its severe adverse effects. Acute or long term cardiotoxicity is the most important dose-limiting toxicity of cisplatin. Cases of angina, myocardial infarction, and atrial arrhythmia have been reported during continuous infusion of cisplatin, but atrioventricular block (AV) has not been reported. Herein, we report a case with recurrent AV block that developed during cisplatin infusion, for the first time.

Keywords: Cisplatin; Complete atrioventricular block; Cardiotoxicity

Introduction

Atrioventricular (AV) block can be defined as a delay or interruption in the transmission of an impulse from the atria to the ventricles, and can be transient or permanent. It has been reported many causes for AV block including drugs, electrolyte disturbances, infiltrative malignancies, hyperthyroidism, and rheumatologic disorders. Various drugs such as digitalis, calcium channel blockers (especially verapamil and to a lesser extent diltiazem), amiodarone, adenosine, and β -blockers may cause AV block. Cisplatin, an alkylating agent, is a highly effective chemotherapeutic agent, and may cause cardiotoxicity. Cases of angina, myocardial infarction, and atrial arrhythmia have been reported during continuous infusion of cisplatin, but AV block has not been reported. Herein, we report a case with recurrent AV block that developed during cisplatin infusion, for the first time.

Case Report

A 50 year-old male had been admitted to public hospital Medical Oncology Department with complaint of a swelling on the face. An ulcerated mass in the mouth had been detected on physical examination. Histopathological examination of an incisional biopsy had been revealed squamous cell carcinoma. After the surgical excision, chemotherapeutic regimen including cisplatin (100 mg/m²) had been administered. All of fasting blood glucose, liver enzymes, serum creatinine, electrolytes (sodium, potassium, magnesium, calcium, phosphorus, i.e.), complete blood count, and electrocardiogram (ECG) (Figure 1) had been reported normal before the chemotherapy. The patient had developed syncope during the infusion of cisplatin on the 5th day of the 5-day continuous infusion schedule of cisplatin, and complete AV block had been diagnosed. Cisplatin infusion had been stopped immediately, and the patient had been referred to our hospital.

There was no history of rheumatic or cardiac disease or disorders. There was no history of medicine other than chemotherapeutic agents. On admission, the patient's blood pressure and other physical findings were normal. ECG revealed sinus rhythm (Figure 1), and there were no abnormal laboratory findings. Chest-X-ray revealed normal findings. Metastatic lesion was not found.

Chemotherapy schedule was continued in our inpatient Oncology clinic. Second syncope was observed during the cisplatin infusion on the 3rd day of the 5-day continuous infusion schedule of cisplatin, in our center. The patient was hypotensive (60/40 mmHg) and unconscious. Complete AV block was documented by ECG (Figure 2A,

2B). Acute renal failure was developed. Whereas serum creatinine was 4 mg/dl, serum electrolytes (sodium, potassium, magnesium, calcium, phosphorus) were all normal. Blood gas analysis revealed as follows; pH was 7.35, HCO₃ was 19.6 mEq/L, pO₂ was 89, pCO₂ was 32. Left ventricular structure and functions, and cardiac valves were normal in ecocardiography. After the temporary pacemaker implantation, successful permanent pacemaker implantation was performed due to persistent complete AV block. Serum creatinine level decreased to normal values within 3 days. Chemotherapy plan was changed. The patient was followed without cardiovascular symptoms for three months after the pacemaker implantation.

Discussion

In differential diagnosis of complete AV block (CAB) in our patient, congenital or structural heart disease, ischemic heart disease, myocarditis, electrolyte disturbances including hypomagnesemia or hypo-hyperkalemia, increased vagal tone, familial AV conduction blocks, infiltrative malignancies, thyroid pathologies, rheumatologic diseases were all excluded. The patient has no history of cardiac disease or disorders, and was not administered cardiovascular medication that changes AV conduction, nearly. Development of recurrent syncope and CAB during cisplatin infusion strongly supports the relation between cisplatin and CAB.

The pathophysiology of chemically induced arrhythmias by cytotoxic agents remains to be clarified. The hypotheses are multiple and include direct and indirect effects. The sinus node may be influenced by several stimuli, and a hyperstimulation of the parasympathic as well as of the sympathetic system may cause abnormal function of the sinus node and abnormal intraatrial or atrioventricular conduction. Cisplatin is cardiotoxic and may lead to left ventricular

***Corresponding author:** Dr. Türkay Özcan, Mersin Üniversitesi Tıp Fakültesi, Kardiyoloji A.D. 33079, MERSİN-TURKEY, Tel: +90 324 3374300; Fax: +90 324 3374305; E-mail: iozcan@mersin.edu.tr

Received July 15, 2011; **Accepted** September 10, 2011; **Published** September 15, 2011

Citation: Ozcan T, Cirit A, Kiykim A (2011) Recurrent Complete Atrioventricular Block During Cisplatin Infusion: A Case Report. J Clin Exp Cardiol 2:151. doi:10.4172/2155-9880.1000151

Copyright: © 2011 Ozcan T, et al. This is an open-access article distributed under the terms of the Creative Commons Attribution License, which permits unrestricted use, distribution, and reproduction in any medium, provided the original author and source are credited.

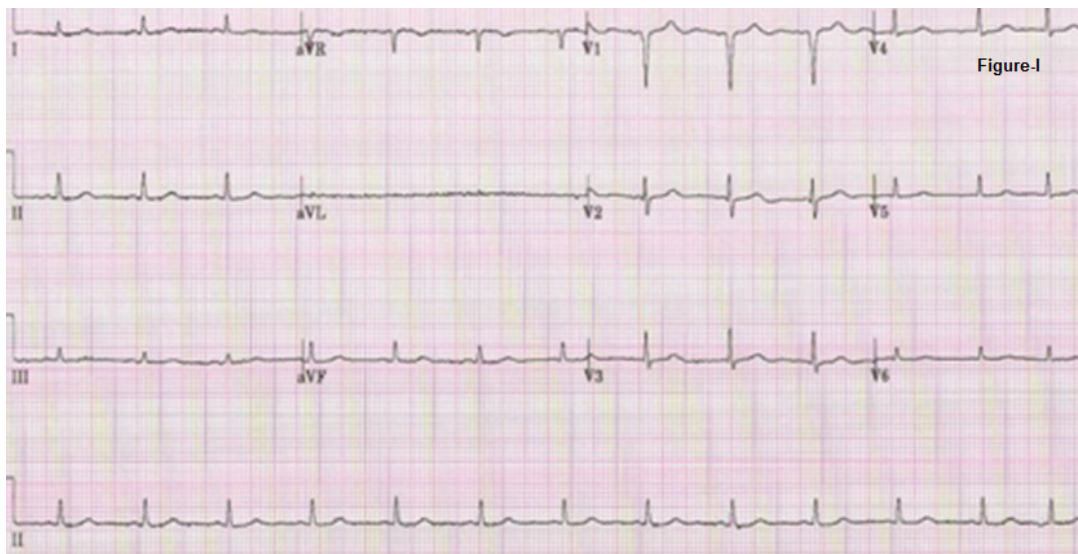


Figure 1: Normal ECG before the chemotherapy.

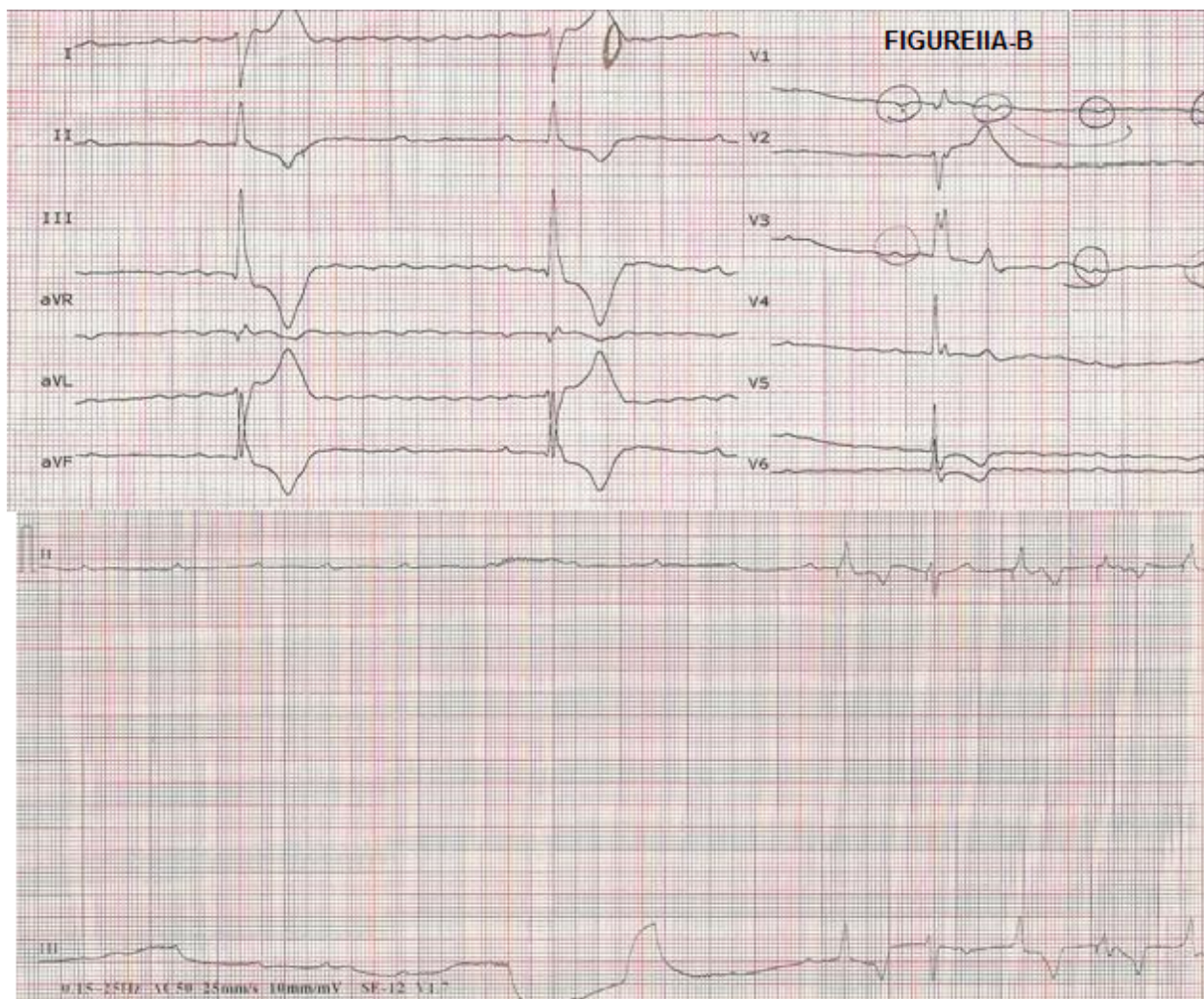


Figure 2A, 2B: High grade A-V block and complete block rhythms in ECG during the cisplatin infusion.

dysfunction and depressed cardiomyocyte contraction associated with mitochondrial abnormalities, enhanced endoplasmic reticulum stress and apoptosis [1,2].

Cisplatin has also been associated with vascular toxicities that include thrombotic microangiopathy, Raynaud's phenomenon, hypertension, and cerebral ischemic events [3]. Cases of atrial arrhythmia, supraventricular tachycardia, bradycardia, ST-T wave changes, left bundle branch block, acute ischemic events, myocardial infarction, myopathy have been reported during treatment with cisplatin [4,5]. Furthermore, cisplatin is one of the most frequently cytotoxic drugs associated with atrial fibrillation (AF) [6]. According to some authors, direct myocardial toxicity may have role in the development of cisplatin-related AF [7]. El-Awady et al demonstrated that cisplatin increased serum cardiotoxicity enzymatic indices (LDH, CK and CK-MB) as well as cardiac troponin I concentration in rats compared to controls [8]. The drug is able to generate reactive oxygen species, such as superoxide anion and hydroxyl radical. The authors suggested that cardiotoxicity could be a secondary event following increased lipid peroxidation of cardiac membranes that resulted in irreversible modification of membrane structures and functions with the consequent leakage of cardiac enzymes as well as troponins. On the other hand, in humans, Villani et al demonstrated that cisplatin chemotherapy has no significant ventricular arrhythmogenic or ischaemic potency in young people with no history of cardiac disease in a small sample size study [9]. Interestingly, the life-threatening CAB developed in our patient with no history of cardiac disease.

Electrolyte disturbances including hypomagnesaemia, hyperkalemia, hypokalemia, and hypocalcaemia may cause myocardial electrical instability. Our patient was not complicated hypokalemia, hyperkalemia or hypomagnesaemia. Acute kidney injury which was improved rapidly may have a role in the pathogenesis of cardiotoxicity in our patient.

In summary, cisplatin may cause life-threatening AV block, even in patients with no history of cardiac disease or disorders. It has been suggested that, the patients with concomitant disorders such as electrolyte disturbances or preexisting cardiovascular disorders may have an increased risk of arrhythmia, and these cases should be monitored closely for arrhythmias.

References

1. Ma H, Jones KR, Guo R, Xu P, Shen Y, Ren J (2010) Cisplatin compromises myocardial contractile function and mitochondrial ultrastructure: role of endoplasmic reticulum stress. *Clin Exp Pharmacol Physiol* 37: 460-465.
2. Wang J, He D, Zhang Q, Han Y, Jin S, et al. (2009) Resveratrol protects against Cisplatin-induced cardiotoxicity by alleviating oxidative damage. *Cancer Biother Radiopharm* 24: 675-680.
3. Jackson AM, Rose BD, Graff LG, Jacobs JB, Schwartz JH, et al. (1984) Thrombotic microangiopathy and renal failure associated with antineoplastic chemotherapy. *Ann Intern Med* 101: 41-44.
4. Hansen SW, Groth S, Daugaard G, Rossing N, Rørth M (1988) Long-term effects on renal function and blood pressure of treatment with cisplatin, vinblastine, and bleomycin in patients with germ cell cancer. *J Clin Oncol* 6: 1728-1731.
5. Brock, PR, Kolioukas, DE, Barratt, TM, Yeomans E, Pritchard J (1991) Partial reversibility of cisplatin nephrotoxicity in children. *J Pediatr* 118: 531-534.
6. Santini D, Tonini G, Abbate A, Di Cosimo S, Gravante G, et al. (2000) Gemcitabine-induced atrial fibrillation: a hitherto unreported manifestation of drug toxicity. *Ann Oncol* 11: 479-481.
7. Menard O, Martinet Y, Lamy P (1991) Cisplatin-induced atrial fibrillation. *J Clin Oncol* 9: 192-193.
8. El-Awady el-SE, Moustafa YM, Abo-Elmatty DM, Radwan A (2011) Cisplatin-induced cardiotoxicity: Mechanisms and cardioprotective strategies. *Eur J Pharmacol* 650: 335-341.
9. Villani F, Misrachi D, Galimberti M (1994) Cardiac arrhythmia and ischaemic events after combination chemotherapy for testicular cancer. *Eur Heart J* 15: 1533-1536.