

Pulmonary Embolism due to Heparin-Induced Thrombocytopenia (HIT): A Case Report of an 11-year-old Child Undergoing Scoliosis Surgery and Literature Review

Florence Müller, Guillaume Boudard and Pierre Journeau*

Department of Paediatric Orthopaedic Surgery, University Hospital Centre, Children's Hospital, Vandoeuvre le's Nancy, France

*Corresponding author: Dr. Pierre Journeau, Department of Paediatric Orthopaedic Surgery, University Hospital Centre, Children's Hospital, Vandoeuvre le's Nancy, France, Tel: +33383154707; E-mail: p.journeau@chru-nancy.fr

Received date: April 18, 2017; Accepted date: May 09, 2017; Published date: May 12, 2017

Copyright: © 2017 Müller F. This is an open-access article distributed under the terms of the Creative Commons Attribution License, which permits unrestricted use, distribution, and reproduction in any medium, provided the original author and source are credited.

Abstract

Background: Thromboembolic events are rare in children even during conditions at risk of thrombosis like surgeries. Unlike adults, thromboprophylaxis in prepubescent children is not well established and preventive anticoagulation is usually given on a case by case basis.

Methods: We report the case of an 11-year-old prepubescent boy suffering from a scoliosis refractory to braces, on which a spinal distraction without fusion was carried out. Prophylactic treatment with low molecular weight heparin (LMWH) was started on day 2 after surgery.

Results: LMWH treatment was stopped on day 10 due to a thrombocytopenia. On day 14, a distal pulmonary embolism was detected on chest angioscan. HemosIL HIT-Ab (IL) and ELISA (enzyme-linked immunosorbent assay) Asserachrom HPIA (Stago) showed positive results. After consultative discussion with the hematology and vascular surgery teams, the diagnosis of heparin-induced thrombocytopenia (HIT) was considered. A curative non-heparinic intra-venous (IV) anticoagulation treatment (Danaparoid sodium, Orgaran, Msd, France) was administrated for one month in addition to IV hydration and compression stockings. Eight day later, the pulmonary artery thrombosis completely resolved. No further complication occurred.

Conclusions: We emphasize the difficulty of deciding whether a prepubescent child has to be prophylactically covered with an anticoagulant in situations of increased thrombosis risks knowing that serious adverse reactions to anticoagulant can occur. HIT is a well-known complication of heparin therapy in adults but it is less documented in children. Potential risk of HIT should be kept in mind during heparin treatment and patients should be closely followed clinically and biologically.

Keywords: Venous thrombosis; Heparin-induced thrombocytopenia; Scoliosis surgery; Children

Introduction

Thromboembolic events (thrombosis, pulmonary embolism (PE)) are rare in the pediatric population accounting for 5.3 per 10, 000 hospital admission/year according to the Canadian thrombosis registry [1]. More recent studies reported similar prevalence [2]. Seventy percent of thromboembolic events occur in two age groups: neonates and adolescents [1-5]. Idiopathic deep venous thrombosis is rare in children and an underlying pathology (thrombophilia, congenital heart disease, renal disease, septic shock, malignancy) or insult (trauma, surgery, presence of central venous lines) is reported in more than 90% of cases [1,3,6]. Obesity, cigarette smoking, oral contraceptives and pregnancy represent risk factors in adolescents [3]. Thromboembolic events in children are important causes of morbidity (post-phlebotic syndrome in 12.4% to 20% of cases) and mortality (fatal pulmonary embolism in 2.2%) [1,7] Low-molecular-weight heparin (LMWH) both for treatment and prevention [2] is the anticoagulant frequently prescribed to children due to several advantages over unfractionated heparin (UFH) (minimal monitoring needed, ease of subcutaneous administration) while being equally effective and safe as

UFH [8,9]. Heparin-induced thrombocytopenia (HIT) is a serious known side effect of heparin utilization occurring in 0.5%-5% of heparin treated adults who already have been exposed to heparin in the past [10]. HIT is an adverse prothrombotic effect of heparin that can take two forms: HIT-I and HIT-II. HIT-I is characterized by a mild asymptomatic reduction in platelet count, occurring in the first 2 days of heparin treatment. HIT-I resolves spontaneously. HIT-II, much more severe, is an immune response occurring 5-14 days after initiation of heparin and presenting with thrombocytopenia (platelet count drop >50% compared with baseline pre-heparin level or a platelet count below 150 g/L) and a paradoxical hypercoagulable state due to platelet activation and thrombin generation [11-15]. HIT development necessitates prior exposure to heparin (flush, heparin-coated catheters, etc.). Therapeutic doses of heparin (versus prophylactic) and intravenous administration (versus subcutaneous) are additional risk factors [16]. The prevalence of HIT-II in adults is known to be much higher in patients receiving UFH (2.6%) compared to those receiving LMWH (0.2%) [17]. Mode of presentation of HIT-II in adults includes venous or arterial thrombosis (ratio 4:1) [18] in 30-60% of patients [19] and pulmonary embolism (PE) in 25% [18]. HIT-II has been associated with a high incidence of limb artery occlusion and life-threatening complications (myocardial infarction, PE, thrombotic

stroke) [15]. Patients showing the lowest platelet counts are at the highest risk of morbidity and mortality [20]. HIT-II should be treated with immediate discontinuation of all heparin products and initiation of an alternative non-heparin anticoagulant [11]. HIT morbidity and mortality rates of 61% and 22.5% have been respectively reported in adults [21]. HIT occurrence in children varies between 1.5% (neonatal intensive care unit) [22] and 2.3% (pediatric intensive care unit) [23]. The diagnosis of HIT-II is formulated on the basis of clinical assessment and on biological tests: demonstration of anti-PF4/heparin complex antibodies via enzymelinked immunosorbent assay (ELISA, sensibility 91-97%) [12,13,24,25], heparininduced platelet aggregation method (HIPA) [22] or C-serotonin release assay, more specific (usually not available in most hospitals: difficult to perform and time consuming), which evaluates platelets activation [12,13,25]. Our case report describing a HIT induced pulmonary embolism in an 11-year-old boy, operated for spinal surgery, underscores the difficulty in weighting the risk-benefit of heparin anticoagulation use in prepubescent children during a high thromboembolic risk surgery.

Clinical case report

Here we report the case of an 11-year-old prepubescent boy suffering from a juvenile scoliosis in association with an arthrogyposis. His past medical history reveals consanguinity and a chronic immune thrombocytopenic purpura. During the previous years, he experienced several episodes of cutaneo-mucous purpura associated with severe episodes of thrombocytopenia treated with corticosteroids and high doses of intravenous immunoglobulins (Clairyg®, Lfb-Biomedicaments, France). Due to the progression of the scoliosis despite bracing (80° right thoracic and 40° left lumbar curves), the patient was scheduled for growing rods spinal instrumentation (T2-T3 laminar hooks, L3-L4 pedicle screws) (Figure 1).

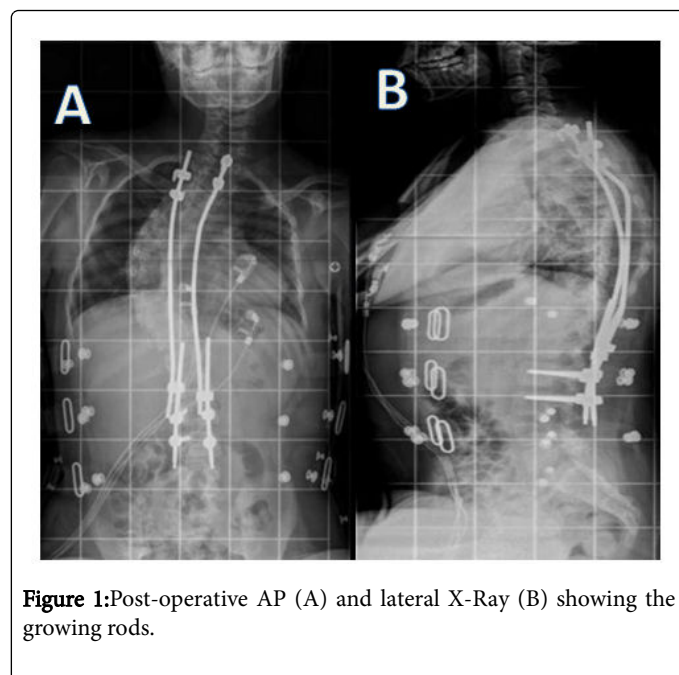


Figure 1: Post-operative AP (A) and lateral X-Ray (B) showing the growing rods.

The chronic thrombocytopenia related to the chronic immune thrombocytopenic purpura was corrected prior to surgery by the administration of polyvalent immunoglobulins (Clairyg®, Lfb-Biomedicaments, France) and corticosteroids (Solupred® 90 mg twice a day × 4 days, Sanofi-Aventis, France) (preoperative platelet count: 146

g/L). During surgery, massive bleeding occurred. The patient received six red blood cell units, three fresh frozen plasma units, one platelet unit and three polyvalent immunoglobulins (Clairyg®, Lfb-Biomedicaments, France). Immediate post-surgical evolution was positive. Preventive LMWH treatment with Lovenox® 40 mg subcutaneous (sc)/day (Sanofi- Aventis, France) (48 Kg) was started on day 2 followed by verticalisation with a brace on day 4. On postoperative day 10, due to the presence of a thrombocytopenia of 17 g/L (500 g/L on day 3), LMWH administration was stopped. On day 14, the patient was sub febrile (38.5°C) without any clinical or biological sign of infection and complained of a brief episode of retrosternal chest pain. Blood oxygen saturation value was 98%. The electrocardiogram showed sinus tachycardia of 125 beats per minute. Chest X Ray was normal. His blood chemistry panel revealed hemoglobin value of 8.9 g/dL, a negative thrombophilic status, a platelet count of 14 g/L and an increase in D-Dimers >10000 µg/L (ELISA, N<500 µg/L). Lower limbs Doppler ultrasonography did not reveal any thrombus but a distal pulmonary embolism was detected in a branch of the right inferior lobar artery on chest angioscan (Figure 2).

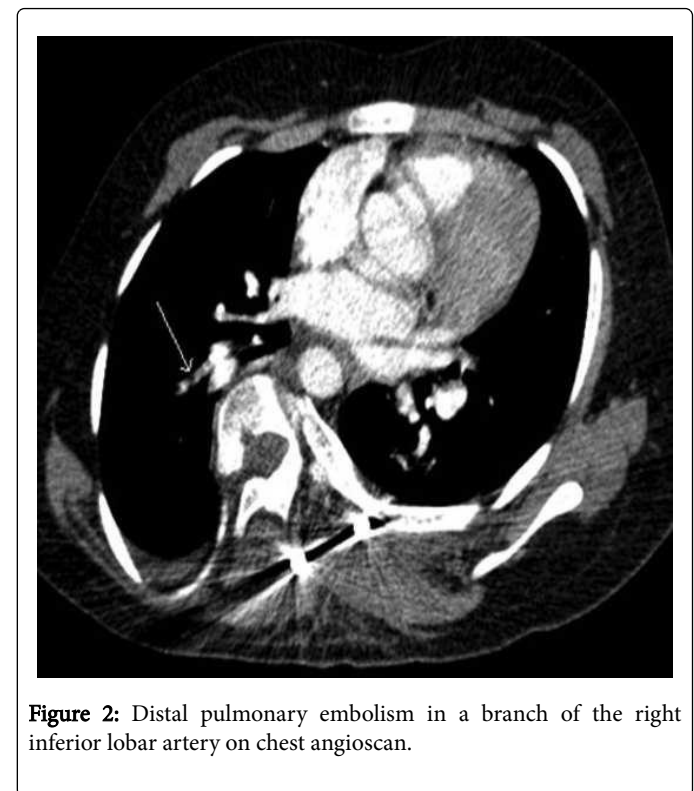


Figure 2: Distal pulmonary embolism in a branch of the right inferior lobar artery on chest angioscan.

Functional and immunological tests, such as heparin-induced platelet aggregation test (Hemosil® HIT-Ab (IL): 100% sensibility and 81.2% specificity) and the anti-PF4/heparin complex enzyme-linked immunosorbent assay test (ELISA Asserachrom® HPIA (Stago): 100% sensitivity and 47-88% specificity) were performed [26]. Based on the positive results obtained with both tests (HEMOSIL HIT-Ab (IL): 2.2 U/ml (N<1.0 U/ml) and ELISA Asserachrom® HPIA (Stago): 0.959 (positivity threshold: 0.676) and after consultative discussion with the hematology and vascular surgery teams, the diagnosis of HIT was considered. Intravenous immunoglobulins (Clairyg®, Lfb-Biomedicaments, France) and a curative non-heparin IV anticoagulation treatment (Danaparoid sodium, Orgaran®, Msd,

France) were administrated in addition to IV hydration and elastic compression stockings. The peripheral IV line had to be changed for a central IV line a few days later due to the appearance of a 2 cm long superficial thrombus in the basilic vein. On day 8 following Orgaran® (Msd, France) treatment, the pulmonary artery thrombosis completely resolved as observed on the control angioscan. Treatment with Orgaran® (Msd, France) alone was continued for a period of one month. The patient was discharged towards a rehabilitation centre after 4 weeks. No further complication occurred. The same patient was re-operated two years later in order to conduct a definitive posterior arthrodesis of his spine. The surgery went fine without complication. Due to his past history of HIT, no heparin was administrated, but the patient was placed on Orgaran® (Msd, France) 500 UI SC twice a day from day 1.

Discussion

Adolescents (after menarche in girls and after signs of secondary sexual development in boys) are considered, just like adults, at high risk of thrombosis during high thromboembolic risk situations and treated prophylactically with an anticoagulant. Concerning younger children, the situation is less clear. Information on the potential benefits and risks of preventive anticoagulation in children is scarce in medical literature. Recommendations regarding thromboprophylaxis in children have been given in some countries (England [2], United States [27,28]) but in France, no consensus exists, hence thromboprophylaxis in children is extrapolated from recommendations for adults [16] and currently mostly administered on an individual basis weighting between thrombotic risks and benefits of anticoagulation for each situation [3]. Eustratiades et al. [29] studied thromboprophylaxis for spinal surgery in children. They reported an occurrence of 15 deep vein thrombosis of the lower limb (0.16%) and one pulmonary embolism (0.001%) in 9870 children aged <16 years old undergoing spinal surgery. According to these results, use of preventive anticoagulation in spinal surgery in pediatric population could be questioned. More than half of deep vein thrombosis appeared during the first week following surgery. The authors reported that 73% (11/15) of patients suffering from a thrombosis or EP had not had any prophylactic anticoagulation. Pediatric patients receiving heparin may be at risk of complication linked to heparin therapy and heparin should be given with caution. HIT is a potential and serious complication of heparin use which real incidence in children remains unclear. It is most frequently observed in adults due to previous heparin exposure but HIT also occurs in children mostly in newborns due to use of heparin-induced catheters as well as during puberty in relation with hormonal change and contraceptive therapy [3]. Here, we report the case of an 11-year-old prepubescent boy who developed a pulmonary embolism on the basis of HIT after spinal surgery. Our patient received preventive LMWH on day 2 and its administration was discontinued on day 10 due to a thrombocytopenia of 17 g/L. On day 14, the patient developed PE and showed positive values to the heparin-induced platelet aggregation HemosIL® HIT-Ab (IL) and the anti-PF4/heparin complex ELISA test (ELISA Asserachrom® HPIA (Stago). Although, according to literature, HIT is often a complication to anticoagulation therapy with UFH and only in few cases is secondary to LMWH use [17,30], our patient developed HIT after LMWH treatment, showing that pediatric patients receiving LMWH are still at risk for HIT [31]. HIT occurred on day 10 in agreement with previous observations [32]. Our patient was suffering from a chronic thrombocytopenic purpura and showed reduced platelets count corrected preoperatively by a corticotherapy. Per operative major

bleeding was corrected by 3 fresh frozen plasma units, 6 red blood cell units, 1 platelet unit and intravenous immunoglobulins which elevated abruptly the platelets count to 500 g/L on day 3 and could have favoured the occurrence of thrombosis. This case shows that risk factors for HIT should be kept in mind and patients should be evaluated for any clinical and/or biological sign of HIT, particularly on day 5-14 after heparin administration. Early diagnosis and accurate management are crucial. Platelet count should be monitored before treatment and every 2-3 days between day 4 and day 10 of treatment [33]. A patient who develops thrombocytopenia or a thromboembolic event should be screened for heparin-associated antiplatelet antibodies (by a blood sample obtained during thrombocytopenia as HIT antibodies are transient (undetectable within weeks after HIT) [34]. Treatment with any form of heparin (e.g. heparin-coated catheters, flushing solution, plasma products, etc.) should be immediately stopped (before resolution of thrombocytopenia and without awaiting laboratory diagnosis) in children suspected to suffer from HIT according to clinical assessment or biological criteria [35]. A non-heparin anticoagulation (Danaparoid (Orgaran®, Msd, France) [12,33] or direct thrombin inhibitor (Hirudin) should be started [32-33,36]. There is no consensus concerning the length of anticoagulation treatment following a HIT but a minimum of 30 days is advised as the risk of thrombosis persists well after the platelet count returns to normal (usually within a week of heparin discontinuation) [4]. Platelet transfusions should not be used for prophylaxis of bleeding in HIT as they aggravate the hypercoagulable state [32]. Limb amputation or death was reported in 42.1% of children treated with withdrawal of heparin alone [4]. This rate dropped by half (18%) when HIT was treated with withdrawal of heparin and utilization of Danaparoid (a low molecular weight heparinoid), Lepirudin (a direct thrombin inhibitor) or Argatroban® (Lfb-biomedicaments, France) [4]. We administrated a curative non-heparin intra-venous (IV) anticoagulation treatment (Danaparoid sodium, Orgaran®, Msd, France) for one month and no additional complication occurred. It is important that the diagnosis of HIT remains clearly documented in the patient's medical record as a patient with a medical history of HIT should never be exposed to heparin again [5]. Our patient was re-operated since his HIT and no longer received any form of heparin.

Conclusion

Much about indications of anticoagulant in children remains to be known. Even in high-risk groups including patients with spinal surgery, anticoagulation should be weighted on an individual basis between benefits and potential adverse events, which can have serious consequences. Heparin-thromboprophylaxis in children should be restricted to high-risk groups due to possible severe adverse effects of heparin. Prior to administration of heparin, a methodical questionnaire should be conducted to point out at risk patients (prior exposition to heparin, medical history of thromboembolic event, family history of thromboembolic event) and the thrombotic risk of the current situation analysed (nature of surgery to be conducted). Preventive measures should be used like maintaining per operative adequate hydration, early mobilisation, removal of central venous line as soon as no longer useful and cessation of contraceptive pill 4 weeks prior to surgery [2,3]. In patients considered to be at high risk of venous thromboembolism and who should receive a thromboprophylaxis, substitution of UFH by LMWH may reduce the incidence of HIT. Close clinical and biological follow-up during and after treatment is required. The use of a mechanical compression method of thromboprophylaxis or an alternative anticoagulation

treatment with Danaparoid, Lepirudin or Argatroban® (Lfb-biomedicaments. France) should be considered. The diagnosis of HIT must be clearly documented in the patient's medical record to prevent further exposure to heparin.

References

1. Andrew M, David M, Adams M, Ali K, Anderson R, et al. (1994) Venous thromboembolic complications (VTE) in children: First analyses of the canadian registry of VTE. *Blood* 83: 1251-1257.
2. Chalmers E, Ganesen V, Liesner R, Maroo S, Nokes T, et al. (2011) Guideline on the investigation, management and prevention of venous thrombosis in children. *Br J Hematol* 154:196-207.
3. Morgan J (2007) Perioperative venous thrombosis in children: is it time for primary prophylaxis? *Pediatr Anesth* 17: 99-101.
4. Risch L, Fischer JE, Herklotz R (2004) Heparin-induced thrombocytopenia in paediatrics: Clinical Characteristics, therapy and outcomes. *Intensive Care Med* 30: 1615-1624.
5. Severin T, Sutor AH (2001) Heparin-induced thrombocytopenia in Pediatrics. *Semin Thromb Hemost* 27: 293-300.
6. Van Ommen CH, Heijboer H, Büller HR, Hirasing RA, Heijmans HS, et al. (2001) Venous thromboembolism in childhood: A prospective two-year registry in The Netherlands. *J Pediatr* 139: 676-681.
7. Monagle P, Adams M, Mahoney M, Ali K, Barnard D, et al. (2000) Outcome of pediatric thromboembolic disease: A report from the canadian childhood thrombophilia registry. *Pediatr Res* 47: 763-766.
8. Sutor AH, Massicotte P, Leaker M, Andrew M (1997) Heparin therapy in pediatric patients. *Semin Thromb Hemost* 23: 303-319.
9. Dix D, Andrew M, Marzinotto V, Charpentier K, Bridge S, et al. (2000) The use of low molecular weight heparin in pediatric patients: A prospective cohort study. *J Pediatr* 136: 439-445.
10. Warkentin TE, Roberts RS, Hirsch J, Kelton JG, et al. (2003) An improved definition of immune heparin-induced thrombocytopenia in postoperative orthopedic patients. *Arch Intern Med* 163: 2518-2524.
11. Cohen RA, Castellano M, Garcia CA (2012) Heparin induced thrombocytopenia: Case presentation and review. *J Clin Med Res* 4: 68-72.
12. Levy JH, Hursting MJ (2007) Heparin-induced thrombocytopenia, A prothrombotic disease. *Hematol Oncol Clin N Am* 21: 65-88.
13. Fradley MG, Drachman DE (2012) A rare case of acute myocardial infarction due to coronary artery dissection and heparin-induced thrombocytopenia. *Case Report Med* 19: 6020.
14. Giossi A, Del Zotto E, Volonghi I, Costa P, Bertuetti R, et al. (2012) Thromboembolic complications of heparin-induced thrombocytopenia. *Blood Coagul Fibrinolysis* 23: 559-562.
15. Potter C, Gill JC, Scott JP (1992) Heparin-induced thrombocytopenia in a child. *J Pediatr* 121: 135-138.
16. Takemoto CM, Streiff MB (2011) Heparin-induced thrombocytopenia screening and management in pediatric patients. *Hematology Am Soc Hematol Educ Program* 11 : 162-169.
17. Warkentin TE, Levine MN, Hirsh J, Jack H, Peter H, et al. (1995) Heparin-induced thrombocytopenia in patients treated with low-Molecular-weight heparin or unfractionated heparin. *N Engl J Med* 332: 1330-1335.
18. Warkentin TE, Kelton JG (1996) A 14-year study of heparin-induced thrombocytopenia. *Am J Med* 101: 502-507.
19. Greinacher A, Farner B, Kroll H (2005) Clinical features of heparin-induced thrombocytopenia including risk factors for thrombosis A retrospective analysis of 408 patients. *Thrombosis and Haemostasis* 94: 132-135.
20. Kelton JG, Hursting MJ, Heddle N, Lewis BE (2008) Predictors of clinical outcome in patients with heparin-induced thrombocytopenia treated with direct thrombin inhibition. *Blood Coagul Fibrinolysis* 19: 471-475.
21. Silver D, Kapsch D, Tsoi EKM (1983) Heparin-induced thrombocytopenia, thrombosis, and Hemorrhage. *Ann Surg* 198: 301-306.
22. Spadone D, Clark F, James E, Jerry Laster, John Hoch, et al. (1992) Heparin-induced thrombocytopenia in the newborn. *J Vasc Surg* 5: 306-312.
23. Schmutz M, Risch L, Huber A, Anne Benn, Joachim E, et al.(2002) Heparin-induced thrombocytopenia-associated thrombosis in pediatric intensive care patients. *Pediatrics* 109:110.
24. Zwicker JI, Uhl L, Huang WY, Shaz BH, Bauer KA, et al. (2004) Thrombosis and ELISA optical density values in hospitalized patients with heparin-Induced thrombocytopenia. *J Thromb Haemost* 2: 2133-2137.
25. Mullen MP, Wessel DL, Thomas KC, McGowan FX, Dinardo JA, et al. (2008) The Incidence and implications of antiheparin-platelet factor 4 antibody formation in a pediatric cardiac surgical population. *Anesth Analg* 107: 371-378.
26. Desprez D, Thiranos JC, Moille M (2011) Evaluation d'un test ELISA Asserachrom HPIA-IgG en post Circulation Extracorporelle: Expérience Strasbourgeoise. *Congrès SFH* 1256: 1-37.
27. Guyatt GH, Akl EA, Crowther M (2012) Executive Summary: Antithrombotic therapy and prevention of thrombosis, 9th edn: American College of chest physicians evidence- based clinical practice guidelines. *Chest* 141: 7-47.
28. Giglia TM, Massicotte P, Tweddell JS (2013) Prevention and treatment of thrombosis in pediatric and congenital heart disease. A scientific statement from the american heart association. *Circulation* 128: 2622-2703.
29. Eustratiades N, Barrelier MT, Derlon A (1994) Thromboembolic complications in surgery of the spine in children and adolescents. *Cah Anesthesiol* 42: 7-13.
30. Martel N, Lee J, Wells Ph (2005) Risk for heparin-induced thrombocytopenia with unfractionated and low-molecular-weight heparin thromboprophylaxis: A metaanalysis. *Blood* 106: 2710-2715.
31. Dager WE, White RH (2004) Low-molecular-weight heparin-induced thrombocytopenia in a child. *Ann Pharmacother* 38: 247-250.
32. Warkentin T, Greinacher A (2004) Heparin-induced thrombocytopenia: Recognition, treatment, and prevention: The Seventh ACCP. Conference on antithrombotic and thrombolytic Therapy. *Chest* 126: 311S-337S.
33. Risch L, Huber AR, Schmutz M (2006) Diagnosis and treatment of heparin-induced thrombocytopenia in neonates and children. *Thromb Res* 118: 123-35.
34. Warkentin TE, Kelton JG (2001) Temporal aspects of heparin-induced thrombocytopenia. *N Engl J Med* 344: 1286-1292.
35. Kamata M, Roby S, McConnell P (2017) Perioperative care in an adolescent patient with heparin-induced thrombocytopenia for placement of a cardiac assist device and Heart Transplantation: Case report and literature review. *Int Med Case Rep J* 10: 55-63.
36. Gupta S, Tiruvoipati R, Green C, Botha J, Tran H (2015) Heparin induced thrombocytopenia in critically ill: Diagnostic dilemmas and management conundrums. *World J Crit Care Med* 4: 202-212.