



Proton Therapy for Lumbar Chordoma in a Patient Affected by Myasthenia Gravis: A Case Report

Giacomelli I¹, Scartoni D¹, Vennarini S¹, Amichetti M¹, Righetto R¹, Lemoine S^{2*} and Cianchetti M¹

¹Centro di Protonterapia, Azienda Provinciale per i Servizi Sanitari, Trento, Italia

²Istituto de Oncologia Angel H. Roffo, Universidad de Buenos Aires, Buenos Aires, Argentina

Abstract

Chordoma is a slow-growing neoplasm arising from remnants of the embryonic notochord. Surgery is recognized as the gold standard approach, however gross total resection is rarely possible for this reason most patients undergo subtotal resection or biopsy followed by radiotherapy. Myasthenia gravis (MG) is neuromuscular autoimmune disorder. The feasibility and safety of radiotherapy and especially of proton therapy (PT) in patients affected by MG has never been adequately documented. We report the case of a patient with lumbar chordoma who was diagnosed of MG just at the beginning of PT.

Introduction

Chordoma is a slow-growing neoplasm arising from remnants of the embryonic notochord that are present in the vertebral body and axial skeleton. Tumors are most commonly sacrococcygeal, followed by lesions developed at skull base and mobile spine [1]. Surgery has traditionally been recognized as the gold standard approach, however gross total resection is rarely possible; for this reason most patients undergo subtotal resection or biopsy followed by radiotherapy.

Some reports suggested that local control rates improve with increasing radiation dose [2,3] and most experts advocate charged particle therapy, typically protons, as the modality of choice alone or in combination with photons [4].

Myasthenia gravis (MG) is an autoimmune neuromuscular disorder characterized by fluctuating muscle weakness and fatigue. It affects both young and old population with a female predominance in the second and third decade and both genders in later age groups; the incidence is around 30 cases per one million per year and the prevalence is estimated to be between 25 and 142 per million [5].

MG is considered a Para neoplastic phenomenon occurring in about 15% of patients with thymoma [6], but in some cases it has been reported to coincide with extrathymic malignancies [7]; however a clear correlation between MG and malignancies is not well established.

We report the case of a patient with lumbar chordoma who was diagnosed with MG after surgery and before the beginning of proton therapy.

Case Report

A 50 year old male presented with a 6 month history of pain arising from the right gluteus and radiating through the posterior side of the leg to the ipsilateral foot. He had past diagnosis of chronic renal failure, gout and hypertension.

In July 2016 he performed a lumbar-sacral MRI showing complete replacement of the 4th lumbar vertebra by a voluminous mass with a diameter of 16 cm with osteolysis and intracanalicular extension, dislocation and compression of the dura and extension through soft paravertebral tissues.

Surgical debulking of the lesion with lumbo-sacral stabilization was performed with histological result of Chordoma (immunohistochemistry: S100+, CK19+, Brachyury+, PDGFR beta+, CK AE1/AE3, CK CAM5.2+, PDGFR-alfa-, CD117-). After surgery the patient developed hyposthenia of the right leg with reduced mobility.

Postoperative MRI highlighted the presence of a huge residual mass and a post-operative treatment with definitive Proton Therapy (PT) was programmed.

Some days before the beginning of radiation, the patient presented general weakness, dizziness, vertigo in supine position, progressive masticatory and swallowing difficulty, ptosis and mimic muscles weakness mostly localized at the left side.

The brain MRI didn't demonstrate the presence of metastasis while the electromyography showed a myasthenic post synaptic disorder of the neuromuscular junction.

AChR antibodies dosage in the blood resulted positive (14.20 pmol/mL; normal value < 0.25 pmol/mL). Medical therapy with oral prednisone 25 mg/day was prescribed.

The patient regularly began proton therapy as it was planned.

Proton therapy was delivered with active beam scanning technique using 2 posterior-oblique fields with single field optimization technique (SFO). Gross Tumor Volume (GTV) was 522.92 cc; a low risk and high risk Clinical Target Volume (CTV) were created in order to cover the possible microscopic spread of the disease. Planning Target Volume (PTV) was generated by a 7 mm expansion to the CTV. High-risk (HR) PTV volume was 2551.95 cc; low-risk (LR) PTV volume was 4070.39 cc. The prescribed total dose was 74 GyRBE to HR PTV and 54 GyRBE for LR PTV (2 GyRBE/fraction, 5 days a week). The patient well tolerated the treatment and completed it without breaks. The only acute toxicity observed was G1 skin dermatitis reported according to Common Terminology Criteria for Adverse event (CTCAE) v4.0. Symptoms related to Myasthenia gravis didn't get worse during PT.

Discussion

MG is often associated with thymic malignancies but in some

***Corresponding author:** Lemoine S, Istituto de Oncologia Angel H. Roffo, Universidad de Buenos Aires, Buenos Aires, Argentina, Tel: +549112168-1017; E-mail: silvina-lemoine@hotmail.com

Received May 13, 2017; **Accepted** August 05, 2017; **Published** August 12, 2017

Citation: Giacomelli I, Scartoni D, Vennarini S, Amichetti M, Righetto R, et al. (2017) Proton Therapy for Lumbar Chordoma in a Patient Affected by Myasthenia Gravis: A Case Report. J Tumor Res 3: 125.

Copyright: © 2017 Giacomelli I, et al. This is an open-access article distributed under the terms of the Creative Commons Attribution License, which permits unrestricted use, distribution, and reproduction in any medium, provided the original author and source are credited.

cases it has been also reported to be related with extrathymic tumors. Given the heterogeneous nature of the study population and wide and different temporal intervals between MG and cancer, it is very difficult to determine whether in these cases their co-occurrence represents a true association [6].

In our case the patient underwent electromyography showing a reduction in area and amplitude of motor potential already at low frequencies that was consistent with pathology of the neuromuscular junction (MG). The diagnosis of MG can be confirmed by a decrease in the compound muscle action potential on repetitive nerve stimulation, by increased jitter on single-fibre electromyography and by a response to a short-acting cholinesterase inhibitor [8].

The detection of antibodies for the AChR in the serum revealed a value of 14.20 pmol/mL (normal value < 0.25 pmol/mL). The presence of antibodies to the acetylcholine receptor (AChR) is a key element for the diagnosis of MG, but around 15% patients with MG do not have detectable AChR antibodies on plasma, particularly in patients with purely ocular myasthenia [9]. In those cases, defined as “seronegative” MG, the detection of antibodies to a membrane-linked muscle specific kinase (MuSK), high level of plasmatic LDH and CPK can help the physician for a correct diagnosis.

The feasibility and safety of radiotherapy in patients with MG diagnosis has never been adequately documented. Some studies have reported that radiotherapy could exacerbate myasthenic symptoms and that these deteriorations can manifest with a varying range of severity, including progressive ptosis, diplopia, dysphagia, generalized muscle weakness, and fatigue or the occurrence of myasthenic crisis, which is characterized by acute respiratory failure requiring mechanical breathing support.

Li et al. [10] reported 15 cases of MG exacerbation in 51 patients undergoing postoperative irradiation for thymoma at the total dose of 50-70 Gy with conventional fractionation. They found that patients without MG exacerbation had higher pharmacologic remission and general remission rates ($p=0.017$ and $p=0.009$, respectively) and that patients with MG exacerbation had a worse prognosis compared with patients without MG exacerbation. They found also that MG exacerbation was significantly correlated with longer duration between MG onset and irradiation ($p=0.029$) and also with more severe MG symptoms before irradiation although it did not reach statistical significance. Our patient had MG mild symptoms developing just few days before the beginning of PT and the diagnosis was confirmed only during PT.

Lysandropoulos and Mavroudakos [11] reported a case clearly linked to postoperative radiotherapy for thymoma. The patient, a 47 years female, had in fact exacerbation of MG symptoms twice just after the end of two courses of radiotherapy of 56 Gy each one, delivered postoperatively and after recurrence. The authors concluded that exacerbation of MG may be an underestimated complication of radiotherapy and that further studies are needed to understand the mechanism of this phenomenon. Ishida [12] reported two cases with deterioration of MG after irradiation.

Interestingly, immunological subsets analysis of the of peripheral blood lymphocytes demonstrated a significant decrease of the proportion in CD4+CD45RA+T (naive) cells and a significant increase in CD4+CD45RA-(memory) T cells and in the percentage of activated (HLADR+) CD4T cell subsets. The study suggested that irradiation post-thymectomy may change the balance of the proportion in CD4+T cell subsets, thereby resulting in the deterioration of MG.

In comparison with conventional radiotherapy, PT has different physical and biological characteristics with better dose distribution. Protons deliver a lower entry dose, depositing the majority of their energy at the end of their path, yielding a typical narrow dose energy peak called “Bragg peak”. This steep fall-off allows for delivery of high doses and sparing of tissue beyond the tumor. In our case we were able to minimize the dose to some critical structures like bilateral kidneys and small bowel as illustrated in Figures 1 and 2. The patient reported only a minimal acute toxicity caused by irradiation, G1 radiation dermatitis, and no exacerbation of MG was detected, nor during neither after PT (two months of follow-up).

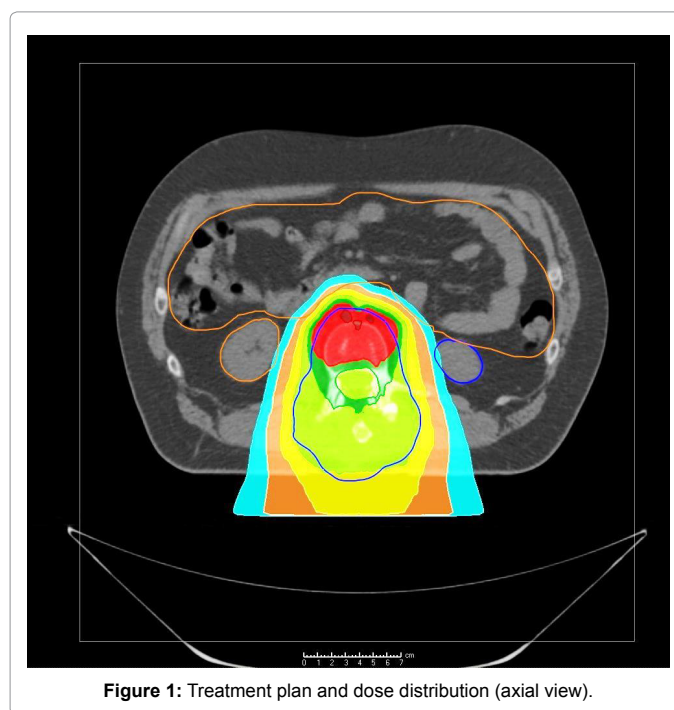


Figure 1: Treatment plan and dose distribution (axial view).

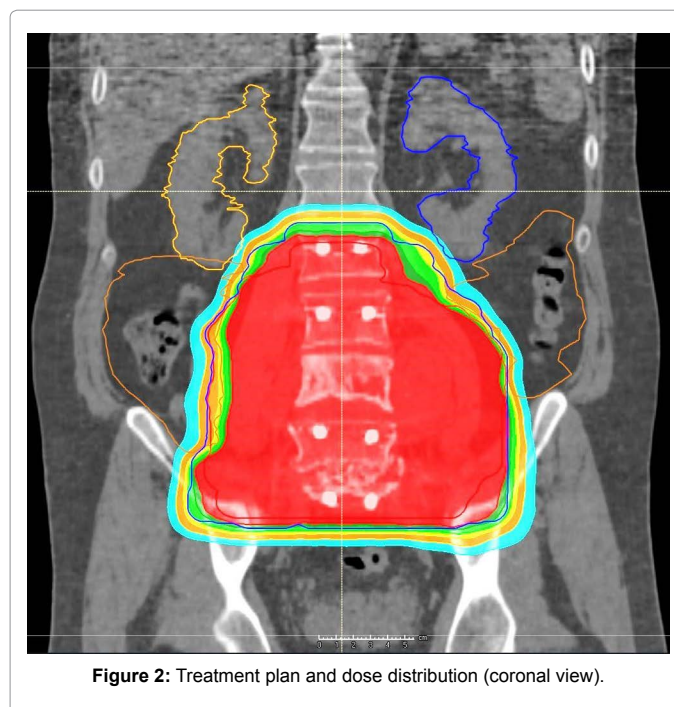


Figure 2: Treatment plan and dose distribution (coronal view).

Patients in the study of Li et al. [10] received anti-cholinesterase agents to control MG symptoms during radiotherapy and a low dose of corticosteroids was also used in some patients to maintain remission. In our report the patient was treated with corticosteroid two weeks after the start of PT without showing any worsening of MG symptoms before the beginning of medical corticosteroid therapy.

Despite no clear and reliable explanations regarding the possible cause of correlation between MG exacerbation and radiotherapy reported in the literature are available, this study suggests that a greater sparing of the normal tissue may reduce also the damage to the lymphatic tissue, limiting the risk of exacerbation of MG.

References

1. Sciubba DM, Chi JH, Rhines LD, Gokaslan ZL (2008) Chordoma of the spinal column. *Neurosurg Clin N Am* 19: 5-15.
2. Klekamp J, Samii M (1996) Spinal chordomas-results of treatment over a 17 year period. *Acta Neurochir (Wien)* 138: 514-519.
3. De Amorim Bernstein K, DeLaney T (2016) Chordomas and chondrosarcomas-The role of radiation therapy. *J Surg Oncol* 114: 564-569.
4. Rotondo RL, Folkert W, Liebsch NJ (2015) High-dose proton-based radiation therapy in the management of spine chordomas: Outcomes and clinicopathological prognostic factors. *J Neurosurg Spine* 23: 788-797.
5. Silvestri NJ, Wolfe GI (2012) Myasthenia gravis. *Semin Neurol* 32: 215-226.
6. Levin N, Abramsky O, Lossos A (2005) Extrathymic malignancies in patients with myasthenia gravis. *J Neurol Sci* 237: 39-43.
7. Evoli A, Batocchi AP, Tonali P, Marciano M (1998) Risk of cancer in patients with myasthenia gravis. *Ann NY Acad Sci* 841: 742-745.
8. Vincent A, Bowen J, Newsom-Davis J, McConville J (2003) Seronegative generalised myasthenia gravis: clinical features, antibodies and their targets. *Lancet Neurol* 2: 99-106.
9. MacLennan C, Beeson D, Buijs A-M, Vincent A, Newsom-Davis J (1997) Acetylcholine receptor expression in human extraocular muscles and their susceptibility to myasthenia gravis. *Ann Neurol* 41: 423-433.
10. Li Y, Chen P, Ding L, Luo C, Wang H, et al. (2015) Clinical outcome and predictive factors of irradiation-associated myasthenia gravis exacerbation in thymomatous patients. *Neurol Sci* 36: 2121-2127.
11. Lysandropoulos AP, Mavroudakos N (2012) Exacerbation of myasthenia gravis after postoperative radiotherapy for a thymoma. *Acta Neurol Belg* 112: 65-66.
12. Ishida S (1996) Changes in clinical and immunological status after post-thymectomized irradiation for invasive thymoma with myasthenia gravis. *Rinsho Shinkeigaku* 36: 629-632.