

Protective Effects of *Urtica dioica* and Cimetidine® on Liver Function Following Acetaminophen Induced Hepatotoxicity in Mice

Juma KK*, Maina SG, Muriithi JN, Mwangi BM, Mworja KJ, Mwonjoria MJ, Ngeranwa JN and Mburu ND

Department of Biochemistry and Biotechnology, Kenyatta University, Nairobi, Kenya

Abstract

Studies have demonstrated that *Urtica dioica* promotes regeneration of the liver cells following damage by carbon tetrachloride. This study investigated the effects of *Urtica dioica* on liver function following acetaminophen overdose. Mice were divided into eight groups of ten each. Acetaminophen at 250 mg/kg and 500 mg/kg significantly ($p < 0.05$) reduced red blood cells, neutrophils and albumins while mean corpuscular hemoglobin, lymphocytes, alanine amino transferase, aspartate amino transferase, prothrombin time and liver pathology were increased. Lactate dehydrogenase was significantly reduced in acetaminophen 250 mg/kg while acetaminophen 500 mg/kg significantly increased alkaline phosphatase and total bilirubin. Even after exposure to acetaminophen toxicity, mice pre-treated with *Urtica dioica* retained the following parameters within normal range: neutrophils, lymphocytes, alanine amino transferase, and liver integrity. Mice co-treated with the drug cimetidine had all parameters within normal except for aspartate amino transferase at acetaminophen dose of 500 mg/kg. The result suggests that *Urtica dioica* and cimetidine are both hemoprotective and hepatoprotective. They have potential in the management of acetaminophen toxicity.

Keywords: Acetaminophen toxicity; *Urtica dioica*; Hepatotoxicity; Hepatoprotection; Antioxidants; Cimetidine.

Introduction

Acetaminophen is one of the most widely used over the counter and prescription drug for treatment of pain and fever [1]. At therapeutic doses, it is very safe and has the same efficacy as aspirin and ibuprofen. However, over the years, cases of acetaminophen toxicity have been documented. The first reported case of acetaminophen toxicity was that of two patients that had developed hepatotoxicity following an overdose [2]. The key finding of the toxicity was the development of necrosis of the hepatocytes. In addition, polymorphonuclear leukocytic infiltration was also observed. Since then, it was understood that necrosis was a key mechanism of action of acetaminophen toxicity. However, necrosis of the cells as a mechanism of inducing apoptosis has been ruled out [3]. Instead, covalent binding in acetaminophen toxicity been suggested [4,5].

Acetaminophen has been attributed to more than half the cases of acute liver failure in the US and Britain. Additionally, in the US, the drug has been associated with a direct overdose cost of about US 87 million on an annual basis [6,7]. Liver dysfunction is immediate and has been shown to take place by about 30 minutes after administration of acetaminophen for the pro-coagulant activity. Similarly alanine amino transferase (ALT) and aspartate amino transferase (AST) reach peak levels in 3 to 7 hours [1,8].

The current regimen for the management of acetaminophen overdose involves using oral or IV infusion of *N*-acetyl cysteine (NAC) [9]. However, NAC has been associated with severe side effects such as seizures, intracranial hypertension, epileptic status and cerebral edema [10]. In addition there are cases of treatment failure in the management of acetaminophen toxicity [7]. Cimetidine is a drug used in the management of patients with ulcers arising from complications of stomach and esophagus promoted by the presence of too many acids. Using animal models, it was shown that the drug was effective as an antidote for acetaminophen poisoning [11,12]. However, it has not been approved for use in humans [13,14]. So, there is need to explore alternative treatment regime for managing acetaminophen over dosage.

The history of *Urtica dioica* dates back to 3000–2000 BC during the Bronze Age and it was also used in the management of rheumatism,

lethargy, coma, paralysis typhus and cholera. The use of *Urtica dioica* as an antidote for poisoning goes back to the 16th century following the work of the herbalist John Gerard, who used stinging nettle as an antidote for poison. Culpeper also used stinging nettle in the management of venomous stings from animals. Nettle has also been suggested to be a tonic and of nutritional value. It has been used in the management of scurvy, anemia, and lack of energy [15]. Recent studies have shown that *Urtica dioica* can regenerate induced damage to liver cells [1,16,17]. In cases of liver poisoning, it has been observed to reverse toxicity effects caused by carbon tetrachloride (CCl₄) [18]. This study was therefore conceived with the aim of determining the effect of *Urtica dioica* on the liver following acetaminophen poisoning.

Materials and Methods

Animals

Mice were bred at the animal house in the Department of Biochemistry and Biotechnology. This study used mice of 8–10 weeks old, weighing between 24–27 g. The mice were maintained in accordance with established guidelines for care and use of laboratory animals. The animals were fed on a standard diet and water provided *ad libitum*.

Plant extraction

Urtica dioica plants were collected from Bungoma County in Western Kenya. Leaves were collected from the plants that were about 1-2 meters tall. About 6 kg of leaves were washed and dried hygienically

*Corresponding author: Kelvin Juma, Department of Biochemistry and Biotechnology, Kenyatta University, P.O. Box 43844-00100, Nairobi, Kenya, Tel: +254 728 898233; E-mail: Juma.kelvin85@gmail.com

Received April 23, 2015; Accepted May 07, 2015; Published May 09, 2015

Citation: Juma KK, Maina SG, Muriithi JN, Mwangi BM, Mworja KJ et al. (2015) Protective Effects of *Urtica dioica* and Cimetidine® on Liver Function Following Acetaminophen Induced Hepatotoxicity in Mice. J Develop Drugs 4: 130. doi:10.4172/2329-6631.1000130

Copyright: © 2015 Juma KK, et al. This is an open-access article distributed under the terms of the Creative Commons Attribution License, which permits unrestricted use, distribution, and reproduction in any medium, provided the original author and source are credited.

inside a closed room for about 1 month. They were then ground to obtain powder (about 1.5 kg) which was dissolved in 4.0 L of distilled water and heated to 60°C and filtered. The filtrate was evaporated to dryness, at reduced pressure, using a rotary vacuum evaporator at a constant temperature of 45°C. The extract was then freeze-dried at -55°C. The lyophilized aqueous extract was utilized for biological experiments as previously [19].

Qualitative phytochemical screening

Phytochemical screening of bioactive compounds in *Urtica dioica* extract was done using standard procedures as follows: tannins [20], alkaloids [21], cardiac glycosides [22], terpenes [23], flavonoids [20], phenolic [24], saponins [20] and steroids [22].

Elemental analysis

Urtica dioica extract was analyzed using X-ray fluorescence technique to determine the quantitative levels of minerals ions using the S2-picofox Spectrometer for Total Reflection X-Ray Fluorescence (TXRF) machine following the manufactures instructions.

Treatment

Urtica dioica extract was administered to the mice through oral gavage at 450 mg/kg body weight on a daily basis for 4 days. Acetaminophen (Lab and Allied Ltd, Nairobi, Kenya) was administered intraperitoneally (IP) at a dosage of 250 mg/kg and 500 mg/kg on the 4th day depending on the treatment arm. Cimetidine 400 mg/kg was also administered IP to the all positive control groups. Treatment arms were as follows: Group A: normal saline. Group B: *Urtica dioica*. Group C: acetaminophen 250 mg/kg. Group D: acetaminophen 500 mg/kg. Group E: Pre-treated with *Urtica dioica* orally followed by acetaminophen 250 mg/kg. Group F: Pre-treated with *Urtica dioica* followed by acetaminophen 500 mg/kg. Group G: acetaminophen 250 mg/kg followed by cimetidine administered after two hours. Group H: acetaminophen 500 mg/kg followed by cimetidine administered after two hours. The weight of mice was measured on days 1 and 4.

Hematological analysis

Venous blood was obtained from the tail. The first drop of blood was wiped off and the following five drops were collected in ethylene di-amine tetra acetic acid (EDTA) vials for use in the blood analysis. Total white blood cells counts (TWBC), red blood cells (RBC), mean corpuscular volume (MCV), mean corpuscular hemoglobin (MCH) and mean corpuscular hemoglobin concentration (MCHC) were computed using an improved coulter counter (Mindray Beckman Coulter 2800, Shanchon Mindray Bio-Medical Electronica Co., Ltd. China). Thick and thin smears of blood were prepared, fixed in formalin, and stained with giemsa stain on glass slides and observed using a microscope for determination of the neutrophils, eosinophil's, basophils, monocytes and lymphocytes using the Schilling method [1,25].

Biochemical analysis

Serum was processed and alanine amino transferase (AST), aspartate amino transferase (AST), alkaline phosphatase (ALP), gamma (γ) glutamyl transferase (γ -GT), lactate dehydrogenase (LDH) and bilirubin levels were assessed using BS-800M Biochemistry auto analyzer (Shanchon Mindray Bio-Medical Electronica Co., Ltd. China). Albumin levels were determined using the bromocresol green technique [26]. Prothrombin time (PT), was assayed using the thromboplastin reagent assays kit following the manufactures recommendation.

Histological analysis

Animals were sacrificed and liver samples observed and isolated. The tissues were fixed using 10% neutral buffered formalin solution and dehydrated gradually in ascending concentration of alcohols at 50, 60, 70, 80, 90, and 100% and thereafter cleared in xylene. The liver lobes were then embedded in paraffin. Blocks of liver tissues were then sectioned in 4-5 μ m thickness; and stained with hematoxylin and eosin. The sections were examined under a light microscope to determine the extent of tissue necrosis and degeneration of photomicrographs were taken [27]. Grading was done according to protocol developed by Kandis et al. [28].

Data management and statistical analysis

A statistical analysis tool for Microsoft (WINKS SDA 7.0.6) was used to perform one way analysis of Variance (ANOVA) followed by Tukey Kramer test (Tukey's post hoc) with Bonferroni adjustment for multiple comparisons between the different groups in the study. T-test was used for comparison of the weight changes differences among treatment groups for days one and four. It was also used for comparison of differences between the means values for the female and male PT values. Significant difference between the treatments groups were reported at $p < 0.05$.

Results

Phytochemical and Mineral screening

Qualitative analysis of *Urtica dioica* for eight selected bioactive compounds indicated that the plant contained alkaloids, tannins, terpenes, flavonoids and phenols. However, saponins, glycosides and steroids were undetected. X-ray fluorescence technique showed that a total of 27 elements were detected in *Urtica dioica* (Table 1). Elements with high concentrations were potassium, calcium, chlorine, molybdenum, bromine, strontium, iron, rubidium, zinc, manganese, titanium, and copper. In this group potassium occurred at the highest concentration of 89594 ppm while copper was the least at 5.72 ppm. Argon, vanadium, chromium, sodium, magnesium, aluminium, silicon, nickel, arsenic, selenium, yttrium, mercury, lead, gallium, and sulphur were in concentrations of less than 0.5 ppm.

Body weight

The mean weight of mice at the start of the experiment was between 24.02 g to 26.40 g. Four days later, the weight ranged between 24.21 g to 27.67 g. The group of mice with the highest weight gain (+1.27 g) was one from the group that was given standard feed supplemented with *Urtica dioica* (Figure 1). On the other hand, the largest weight loss (-1.41 g), was from the group fed on standard feed only. The net weight gain for the mice group that received standard feed supplemented with *Urtica dioica* was 1.04 g while those that received standard feed had a net weigh loss of -0.99 g. Paired *t*-test of weight on day 1 and 4 showed that two out of the three group of mice that were fed standard feed supplemented with *Urtica dioica* had significant weight gain: Group B (calculated $t=5.65391$; Degree of freedom (DF)=9; $p < 0.001$ and Group F (calculated $t=3.06011$; DF=9; $p < 0.05$). On the other hand, two of the three groups with significant weight lose were those fed on standard feed: Group C (calculated $t=3.23174$; DF=9; $p < 0.05$) and Group D (calculated $t=5.33396$; DF=9; $p < 0.001$); while the third was Group E (calculated $t=2.74298$; DF=9; $p < 0.05$) that was feed on standard feed supplemented with *Urtica dioica*.

Element	Concentrations (ppm)
Molybdenum (Mo)	12500 ± 1207
Chlorine (Cl)	15450 ± 1472
Potassium (K)	89594 ± 1641
Calcium (Ca)	31225 ± 1003
Argon (Ar)	<0.5
Sulphur (S)	<0.5
Titanium (Ti)	7.36 ± 0.60
Vanadium (V)	<0.5
Chromium (Cr)	<0.5
Manganese (Mn)	42.0 ± 0.8
Iron (Fe)	178 ± 3
Nickel (Ni)	<0.15
Copper (Cu)	5.72 ± 0.17
Zinc (Zn)	91.0 ± 1.7
Arsenic (As)	<0.1
Selenium (Se)	<0.1
Bromine (Br)	382 ± 13
Rubidium (Rb)	133 ± 4
Strontium (Sr)	272 ± 16
Yttrium (Y)	<0.1
Mercury (Hg)	<0.1
Lead (Pb)	<0.1
Sodium (Na)	<0.5
Magnesium (Mg)	<0.5
Aluminium (Al)	<0.5
Silicon (Si)	<0.5
Gallium (Ga)	<0.5

Table 1: *Urtica dioica* elemental analysis.

Body condition of mice

Mice administered with acetaminophen at doses of 250 mg/kg or 500 mg/kg body weight were dormant, sickly, had a rough coat and poor appetite. However, the mice in the control; *Urtica dioica*; co-treated groups of *Urtica dioica* and acetaminophen and also those co-treated with acetaminophen and cimetidine were alert and active, had glossy coat, and were of good appetite.

Hematology

Mice pre-treated with *Urtica dioica* had significantly low ($p < 0.001$) levels of red blood cell and significantly elevated MCH ($p < 0.001$) and lymphocytes ($p < 0.05$) levels when compared to control (Table 2). Acetaminophen toxicity caused a significant increase in the levels of MCH ($p < 0.001$) and lymphocyte ($p < 0.05$) and a significant drop in the levels of RBC ($p < 0.001$) and neutrophils ($p < 0.05$). Mice that were pre-treated with *Urtica dioica* at 450 mg/kg for four days followed with administration of acetaminophen at 250 mg/kg recorded elevated levels of MCV, MCH, neutrophils, eosinophils and monocytes. At the same time they had reduced levels of TWBC, RBC, MCHC and lymphocytes while the levels of basophils remained unchanged. Post hoc test analysis for multiple comparisons showed that there was a significant increase in MCV ($p < 0.05$) and MCH ($p < 0.001$) and a significant decrease in RBC ($p < 0.001$) (Table 3). In addition, mice treated with *Urtica dioica* followed by 500 mg/kg acetaminophen showed elevated MCV, MCH, MCHC, neutrophils, eosinophils and basophils. While the levels of TWBC, RBC, lymphocytes and monocytes were lower. Post hoc analysis indicated a significant increase in the MCV ($p < 0.001$) and MCH ($p < 0.001$) and a significant decrease ($p < 0.001$) in RBC levels. Haematological values of mice that were co-treated with 250 mg/kg or 500 mg/kg of acetaminophen and 400 mg/kg of cimetidine showed the no significant differences ($p > 0.05$) with those of the control group.

Biochemical parameters

Mice treatment with *Urtica dioica* caused a significant ($p < 0.05$) increase in the aspartate amino transferase and albumin ($p < 0.05$) levels and a reduction ($p < 0.05$) in lactate dehydrogenase (Table 3). Mice treated with 250 mg/kg acetaminophen caused a significant increase in the levels of ALT, AST, Albumin and PT ($p < 0.001$). On the other hand there was a significant decrease in LDH ($p < 0.05$) and albumin levels ($p < 0.001$). While those treated with acetaminophen at 500 mg/kg showed that (ALT, AST, ALP, and PT; $p < 0.001$) and (total bilirubin; $p < 0.05$) were significantly higher. The toxicity also caused a significant decrease in albumin levels ($p < 0.001$).

Mice co-treated with 250 mg/kg or 500 mg/kg acetaminophen and 400 mg/kg cimetidine had high enzyme levels for all parameters except for ALP when compared to the control. Tukey's post hoc test showed the differences observed were statistically in-significant ($p > 0.05$) for all treatments at 250 mg/kg. However, AST levels were significantly high ($p < 0.05$) in the group with 500 mg/kg acetaminophen and 400 mg/kg cimetidine.

Pre-treatment of mice with *Urtica dioica* followed with 250 mg/kg of acetaminophen resulted in elevated ALT, ALP, γ -GT, TB, and PT when compared to the control group (Table 3). On the other hand AST, LDH and Albumin were reduced. Multiple comparisons showed that differences in five of the parameters (ALT, AST, ALP, γ -GT and TB) were statistically non-significant ($p > 0.05$). LDH and albumin were significantly ($p < 0.001$) lowered, while prothrombin time was significantly ($p < 0.001$) increased.

Mice treated with *Urtica dioica* and 500 mg/kg of acetaminophen displayed a different profile and the parameters found to be high were ALT, AST, ALP, λ -GT, TB, and PT when compared to the control group (Table 3). LDH and Albumin levels were reduced. Post hoc test showed that difference observed on three (γ -GT, TB and albumin) of the eight differences were statistically non-significant ($p > 0.05$). Four of the parameters (ALT, AST, ALP and PT) were significantly high ($p < 0.001$) while lactate dehydrogenase was significantly low ($p < 0.05$).

Comparison of prothrombin time in males and females mice

Analysis of PT in male and female mice showed that females had a slightly higher PT activity time compared to their male counterparts as shown in Figure 2. However, paired *t*-test showed that the difference between the two means for the males and females were statistically insignificant (DF= 4; $p > 0.05$) at the 8 different treatment groups.

Histopathology

Liver sections from control, *Urtica dioica* and cimetidine treated groups showed normal hepatic architectures. In acetaminophen treated sham control groups at both doses of 250 mg/kg and 500 mg/kg degenerated and necrotic hepatocytes in centrilobular region. They also had hepatic lesions, along with significant fatty degeneration, distortion of hepatic cords, dilations and congested central vein. These were in tandem with other morphological signs of congestion. Physical examination of the liver showed hepatomegaly, pale in colour and had a smooth surface with visible small spots on the surface. *Urtica dioica* treated groups showed regenerative changes with significant sustained hepatic architecture almost similar to the control group at both doses of 250 mg/kg and 500 mg/kg body weight of acetaminophen. Less significant changes were seen with lower doses of 250 mg/kg compared to 500 mg/kg of acetaminophen in the 450 mg/kg *Urtica dioica* treated groups (Figure 3).

Assays	Control	UD 450 mg/kg	Acet 250 mg/kg	Acet 500 mg/kg	UD+Acet 250 mg/Kg	UD+Acet 500 mg/kg	Acet 250mg + Cimet 400mg	Acet 500mg + Cimet 400mg
TWBC ($\times 10^9/L$)	5.11 \pm 1.08	6.96 \pm 1.85	5.74 \pm 0.89	6.34 \pm 2.09	4.72 \pm 0.55	3.80 \pm 2.56	4.75 \pm 1.20	5.15 \pm 0.97
RBC ($\times 10^{12}/L$)	8.08 \pm 1.10	5.63 \pm 0.51**	4.77 \pm 1.41**	4.85 \pm 0.95**	4.57 \pm 0.81**	3.91 \pm 1.16**	8.61 \pm 1.43	8.58 \pm 1.18
MCV (fl)	45.76 \pm 2.75	48.84 \pm 2.35	50.32 \pm 3.00	50.22 \pm 2.02	51.18 \pm 4.20*	56.61 \pm 7.00**	46.96 \pm 2.02	46.43 \pm 2.74
MCH (pg)	13.60 \pm 1.07	15.39 \pm 0.57**	16.16 \pm 0.42**	15.98 \pm 0.42**	16.12 \pm 0.74**	16.00 \pm 0.62**	13.73 \pm 0.99	13.49 \pm 1.24
MCHC (g/dl)	29.67 \pm 0.93	31.67 \pm 1.10	32.01 \pm 1.93	31.62 \pm 1.65	29.27 \pm 8.18	29.76 \pm 2.34	29.22 \pm 1.35	28.96 \pm 1.13
NEUT (%)	30.00 \pm 1.33	28.80 \pm 1.03	27.90 \pm 0.57*	27.80 \pm 1.03**	30.10 \pm 1.60	30.70 \pm 1.06	29.70 \pm 0.95	29.90 \pm 0.74
LYM (%)	51.60 \pm 1.08	54.00 \pm 1.33*	54.80 \pm 0.63*	54.60 \pm 1.08*	51.40 \pm 0.97	51.20 \pm 0.63	51.90 \pm 1.29	52.20 \pm 1.69
EOS (%)	9.40 \pm 0.70	9.30 \pm 1.06	9.10 \pm 0.57	9.10 \pm 0.57	9.50 \pm 0.71	9.50 \pm 0.97	9.30 \pm 0.82	9.40 \pm 0.52
MONO (%)	8.20 \pm 1.23	7.50 \pm 0.85	7.60 \pm 0.52	7.00 \pm 0.82	8.30 \pm 0.82	7.80 \pm 0.63	8.30 \pm 0.82	7.80 \pm 1.23
BAS (%)	0.80 \pm 0.42	0.60 \pm 0.70	0.70 \pm 0.48	0.70 \pm 0.82	0.80 \pm 0.92	1.00 \pm 0.82	1.00 \pm 0.47	0.80 \pm 0.42

The *p* values are for multiple comparisons between the control and other treatments: **p*<0.05, ***p*<0.001. TWBC: Total white blood cells; RBC: Red Blood Cells; MCV: Mean Corpuscular Volume; MCH: Mean Corpuscular Hemoglobin; MCHC: Mean Corpuscular Hemoglobin Concentration; NEUT: Neutrophils; LYM : Lymphocytes; EOS: Eosinophils; MONO: Monocytes; BAS: Basophils.

Table 2: Comparisons of hematological parameters of Swiss albino mice subjected to treatment regimens of *Urtica dioica*, acetaminophen and cimetidine.

Assays	Control	UD 450 mg/kg	Acet 250 mg/kg	Acet 500 mg/kg	UD+Acet 250 mg/Kg	UD+Acet 500 mg/kg	Acet 250mg + Cimet 400 mg	Acet 500 mg+Cimet 400 mg
ALT(U/L)	62.22 \pm 16.00	69.80 \pm 9.88	305.20 \pm 91.56**	349.80 \pm 86.42**	120.8 \pm 32.06	199.2 \pm 89.30**	65.50 \pm 28.21	95.71 \pm 37.48
AST(U/L)	313.78 \pm 71.50	478.60 \pm 43.13*	707.4 \pm 67.09**	940.60 \pm 139.05**	251.80 \pm 39.23	788.80 \pm 1.20**	414.00 \pm 204.77	494.28 \pm 138.69*
ALP(U/L)	4.60 \pm 2.55	6.80 \pm 5.26	8.40 \pm 2.97	15.80 \pm 7.76**	7.83 \pm 0.83	13.85 \pm 0.40**	3.00 \pm 1.76	3.44 \pm 1.13
γ -GT(U/L)	1.30 \pm 0.48	2.40 \pm 2.07	3.60 \pm 0.55	3.80 \pm 2.78	3.20 \pm 3.96	3.80 \pm 2.28	1.90 \pm 1.37	1.50 \pm 0.93
LDH (U/L)	1203.40 \pm 264.50	889.80 \pm 124.53*	866.40 \pm 164.05*	1344.40 \pm 396.47	719.60 \pm 33.59**	831.40 \pm 116.75*	1525.00 \pm 209.72	1248.00 \pm 37.78
TB(μ mol/L)	11.94 \pm 4.09	9.94 \pm 2.87	17.64 \pm 3.22	30.00 \pm 21.80*	12.98 \pm 5.50	21.04 \pm 6.81	22.70 \pm 5.85	19.40 \pm 9.42
Alb(mg/ml)	30.40 \pm 2.06	32.30 \pm 1.16*	22.60 \pm 0.84**	18.30 \pm 1.16**	23.90 \pm 0.99**	29.30 \pm 0.95	30.70 \pm 1.25	30.70 \pm 1.42
PT(Secs)	12.30 \pm 0.95	13.10 \pm 0.57	15.70 \pm 0.67**	18.10 \pm 0.57**	15.50 \pm 0.53**	17.00 \pm 1.05**	12.40 \pm 0.70	12.80 \pm 0.63

The *P* values are for multiple comparisons between the control and other treatments **P*<0.05, ***P*<0.001. TB: Total Bilirubin; ALT: Alanine Aminotransferase; AST: Aspartate Amino Transferase; ALP: Alkaline Phosphatase; Γ -GT: Gamma Glutamyl Transferase; LDH: Lactate Dehydrogenase; TB: Total Bilirubin; Alb: Albumin; PT: Prothrombin Time; Acet: Acetaminophen; UD: *Urtica dioica*; Cimet: Cimetidine.

Table 3: Comparisons of biochemical parameters of Swiss albino mice subjected to treatment regimens of *Urtica dioica*, acetaminophen and cimetidine.

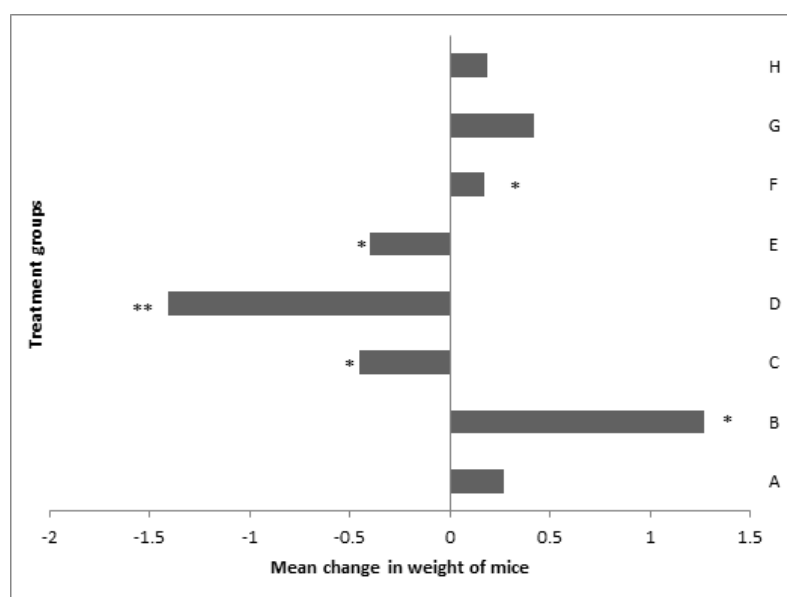


Figure 1: Change in mean body weight of mice fed on either standard feed or standard feed supplemented with *Urtica dioica*: *p* values are from paired t-test between the weight of day 1 and 4, **p*<0.05, ***p*<0.001, Group A=Standard feed, Group B=Standard feed+*Urtica dioica*, Group C=Standard feed, Group D=Standard feed, Group E=Standard feed+*Urtica dioica*; Group F=Standard feed+*Urtica dioica*, Group G=Standard feed, Group H=Standard feed.

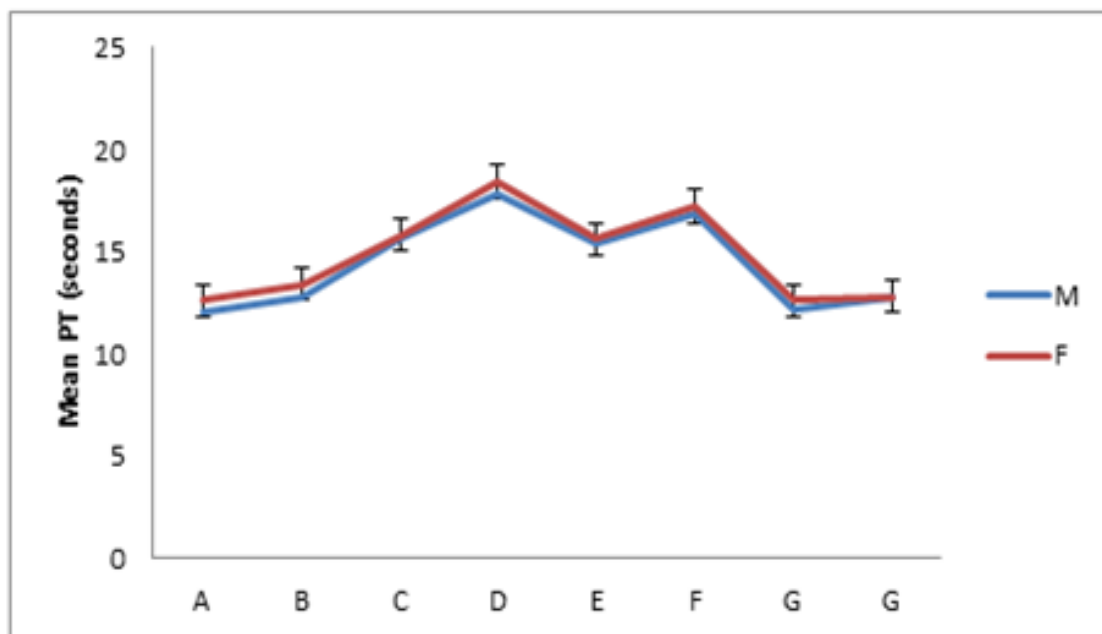


Figure 2: Males versus female prothrombin values: p values are from paired t-test between the mean male and female PT values, * $p < 0.05$, ** $p < 0.001$, Group A=control, Group B=*Urtica dioica*, Group C=acetaminophen 250 mg/kg, Group D=acetaminophen 500 mg/kg, Group E=*Urtica dioica*+acetaminophen 250 mg/kg; Group F=*Urtica dioica*+acetaminophen 500 mg/kg, Group G=acetaminophen 250 mg/kg+cimetidine 400 mg/kg, Group H=acetaminophen 250 mg/kg+cimetidine 400 mg/kg.

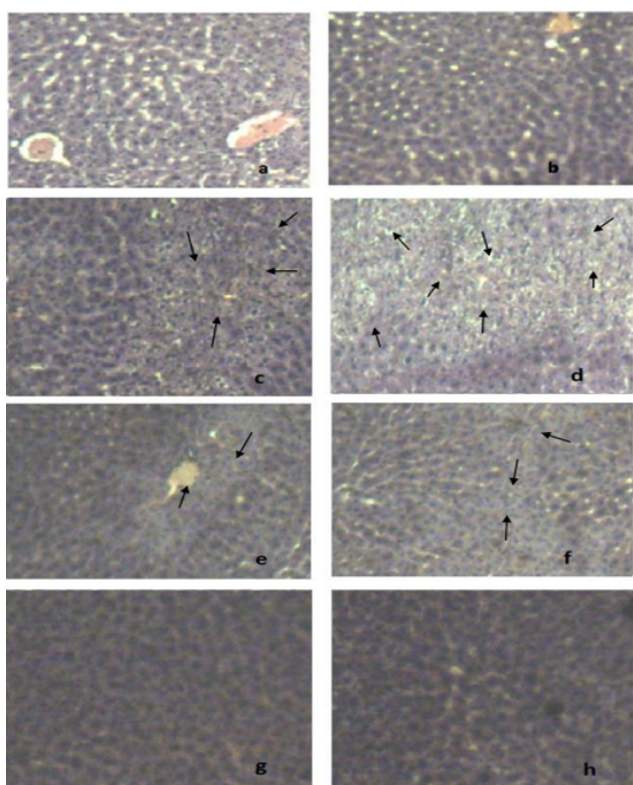


Figure 3: Photographs for histopathology of the liver of mice, a=control, b=*Urtica dioica*; c=acetaminophen 250 mg/kg; d=acetaminophen 500 mg/kg; e=*Urtica dioica*+acetaminophen 250 mg/kg; f=*Urtica dioica*+acetaminophen 500 mg/kg; g=acetaminophen 250 mg/kg+cimetidine 400 mg/kg; h=acetaminophen 250 mg/kg+cimetidine 400 mg/kg. Arrow (↑) indicates the regions of necrosis.

Discussion

Acetaminophen toxicity caused a reduction in red blood cells and neutrophils. This is similar to findings made on dogs and rats [1,29,30]. Depletion of red blood cells causes hyperbilirubinaemia [29], while neutropenia is as a result of anemia, splenomegaly, and damage to the bone marrow [31-33]. Acetaminophen administration produced a dose related elevation of ALT, AST and PT. High levels of ALT [8,16,30,34,35] and AST [3,11,18] in acetaminophen-induced toxicity at doses of 100–500 mg/kg. However, lower doses of acetaminophen (16-66 mg/kg) showed an insignificant elevation of ALT and AST [30]. Elevated levels of these biomarkers are an indication of hepatotoxicity [36,37]. Gender differences in PT have been reported [8,38]; however, similar findings were not duplicated in this study. Elevation of ALP, total bilirubin and reduction of albumin levels is a further indication of severe damage and dysfunction of the liver [39]. There was an insignificant difference in γ -GT levels contrary to the observations of Olaleye et al. [35] following a dose of 2 g/kg of acetaminophen which was 400% higher than in this study. Therefore, γ -GT bio-marker is informative at extremely high toxic doses.

Normal levels of neutrophils, ALT, AST, total bilirubin and albumin were observed in mice pre-treated with *Urtica dioica* suggesting that *Urtica dioica* is hepatoprotective. Phytochemical and elemental analysis showed that *Urtica dioica* contained alkaloids, tannins, terpenes, flavonoids and phenols, and 27 mineral elements. *Urtica dioica* hepatoprotective abilities may be as a result of the presence of flavonoids, polyphenols, ascorbic acid, carotenoids, tannins and lignin's among the plant constituents [40]. They are free radical scavengers and hence promote hepatoprotection [40]. Polyphenols specifically inhibit the cytochrome P-450 enzymes [41]. Minerals are also hepatoprotective to xenobiotics [42]. Minerals elements of zinc, selenium, magnesium and copper reported suggest great potential of hepatoprotection [42]. Cimetidine caused an insignificant variation in hematological and biochemical parameters indicating its hemoprotective and hepatoprotection potential.

Histological analysis showed normal liver tissues in the control, *Urtica dioica* and cimetidine treated mice. However, histopathological changes were observed in mice treated with acetaminophen and were dose related. Acetaminophen overdoses is responsible for liver injury and failure in both animals and humans [43]. Cell death may occur as a result of apoptosis and necrosis [43]. Acetaminophen metabolite referred to as *N*-acetyl-*p*-benzoquinone imine (NAPQ1) predisposes the liver to damage by oxidative stress. This also amplifies the potential for the free radical chain reactions. This leads to hepatic injury as evidenced by leakage of cellular enzymes into the plasma. This is a result of cell necrosis which interferes with the integrity of the cell membrane affecting cellular transport in hepatocytes [44]. Inhibition of protein synthesis has also been indicated in cases of reactive free radicals that may bind covalently to cellular macromolecules. Improvement in tissue pathology was observed in mice treated with acetaminophen and managed with 450 mg/kg of *Urtica dioica*. An even better protection was observed in cimetidine treated mice. Regeneration of tissues after induction of damage is similar to other study findings [1,3,17,18,30,36]. *Urtica dioica* is also hepatoprotective in alcohol and CCl₄ [17,1]. Hence, acetaminophen at 250 mg/kg and 500 mg/kg are hepatotoxic, while *Urtica dioica* and cimetidine are hepatoprotective as reported in this study. This study has provided further evidence to show that *Urtica dioica* is hepatoprotective and has potential for exploitation.

Cimetidine is a drug used in the management of patients with ulcers. It was also shown to be effective as an antidote for acetaminophen poisoning over three decades ago in animal studies [11]. This is therefore the only other study that has investigated and demonstrated the hepatoprotection properties of cimetidine. In conclusion this work suggests that *Urtica dioica* and cimetidine are both hemoprotective and hepatoprotective. They have potential in the management of acetaminophen toxicity.

Acknowledgement

We acknowledge Mr. James Adino and Mr. Wycliff Wenwa, Animal house, Department of Biochemistry and Biotechnology, Kenyatta University. Mr. Fred Idewa and Mr Joseph Kihara, Kenyatta University Anatomy Laboratory. Finally, Mr. Simion Kipkorir Bartilol, University of Nairobi, Institute of Nuclear Science and Technology for their technical support in this project for their technical support in this research study.

References

- Oyedemi KO, Bolarinwa AF, Adabanjia RB (2013) Evaluation of haematological and reproductive effect of paracetamol (acetaminophen) in Female Albino Rats. IOSR J Dent and Medic Sci 3:72-75.
- Davidson DG, Eastham WN (1966) Acute liver necrosis following overdose of paracetamol. Br Med J 2: 497-499.
- Gujral JS, Knight TR, Farhood A, Bajt ML, Jaeschke H (2002) Mode of cell death after acetaminophen overdose in mice: apoptosis or oncotic necrosis? Toxicol Sci 67: 322-328.
- Bessems JG, Vermeulen NP (2001) Paracetamol (acetaminophen)-induced toxicity: molecular and biochemical mechanisms, analogues and protective approaches. Crit Rev Toxicol 31: 55-138.
- Nelson SG, Wan Z, Stan MA (2002) S(N)2 ring opening of beta-lactones: an alternative to catalytic asymmetric conjugate additions. J Org Chem 67: 4680-4683.
- Larson AM, Polson J, Fontana RJ, Davern TJ, Lalani E, et al. (2005) Acetaminophen-induced acute liver failure: results of a United States multicenter, prospective study. Hepatology 42: 1364-1372.
- Hodgman MJ, Garrard AR (2012) A review of acetaminophen poisoning. Crit Care Clin 28: 499-516.
- Ganey PE, Luyendyk JP, Newport SW, Eagle TM, Maddox JF, et al. (2007) Role of the coagulation system in acetaminophen-induced hepatotoxicity in mice. Hepatology 46: 1177-1186.
- Saito C, Zwingmann C, Jaeschke H (2010) Novel mechanisms of protection against acetaminophen hepatotoxicity in mice by glutathione and N-acetylcysteine. Hepatology 51: 246-254.
- Heard K, Schaeffer TH (2011) Massive acetylcysteine overdose associated with cerebral edema and seizures. Clin Toxicol (Phila) 49: 423-425.
- Ruffalo RL, Thompson JF (1982) Cimetidine and acetylcysteine as antidote for acetaminophen overdose. South Med J 75: 954-958.
- Speeg KV Jr, Mitchell MC, Maldonado AL (1985) Additive protection of cimetidine and N-acetylcysteine treatment against acetaminophen-induced hepatic necrosis in the rat. J Pharmacol Exp Ther 234: 550-554.
- Critchley JA, Dyson EH, Scott AW, Jarvie DR, Prescott LF (1983) Is there a place for cimetidine or ethanol in the treatment of paracetamol poisoning? Lancet 1: 1375-1376.
- Zira A, Mikros E, Giannioti K, Galanopoulou P, Papalois A, et al. (2009) Acute liver acetaminophen toxicity in rabbits and the use of antidotes: a metabonomic approach in serum. J Appl Toxicol 29: 395-402.
- Vance K (2015) Stinging Nettle: History of stinging Nettle.
- Adeneye AA, Olagunju JA, Benebo AS, Elias SO, Adisa AO, et al. (2008) Nephroprotective effects of the aqueous root extract of *Harungana madagascariensis* (L). In acute and repeated dose acetaminophen renal injured rats. Inter J Appl Res Nat Prod 1: 6-14.
- Oguz S, Kanter M, Erboğa M, Toydemir T, Sayhan MB, et al. (2015) Effects of *Urtica dioica* on oxidative stress, proliferation and apoptosis after partial hepatectomy in rats. Toxicol Ind Health 31: 475-484.
- Kanter M, Meral I, Dede S, Gunduz H, Cemek M, et al. (2005) Effects of *Nigella sativa* L. and *Urtica dioica* L. on lipid peroxidation, antioxidant enzyme systems and some liver enzymes in CCl₄-treated rats. J Vet Med A Physiol Pathol Clin Med 50: 264-268.
- Das M, Sarma BP, Rokeya B, Parial R, Nahar M, et al. (2011) Antihyperglycemic and antihyperlipidemic activity of *Urtica dioica* on type 2 diabetic model rats. J Diabetol 2:1-6.
- Jigna P, Sumitra VC (2007) In vitro antimicrobial activity and phytochemical analysis of some Indian medicinal plant. Turk J Biol 31: 53-58.
- Oguyemi AO (1974) Sofowora A (ed.) Proceedings of a conference. African medicinal plants. University of Ife, Ife, pp. 4-10.
- Rasool R, Ganai BA, Akbar S, Kamili AN, Masood A (2010) Phytochemical screening of *Prunella vulgaris* L. - an important medicinal plant of Kashmir. Pak J Pharm Sci 23: 399-402.
- Harborne JB (1973) Phytochemical methods. London: Chapman and Hall Ltd.
- Martinez A, Valencia G (2003) Manual de practicas de Farmacognosia y Fitoquimia: 1999. 1. Medellin: Universidad de Antioquia; Marcha fotiquimica 59-65.
- Emeka EJI, Atinuke OO (2010) Biochemical, haematological and histological effects of dietary supplementation with leaves of *Gnetum africanum* Welw. On paracetamol-induced hepatotoxicity in rats. Intern J Pharm 6:872-879.
- Bitiren M, Musa D, Ozgonul A, Ozaslan M, Kocyigit A, Sogut O, et al. (2010) Protective effects of Green tea (*Camelia Sinensis*), *Hypericum perforatum*, and *Urtica dioica*, on hepatic injury and lymphocytes DNA damage induced by carbon tetrachloride in Wistar Rats. Intern J Pharm 6: 241-248.
- Drury R, Wallington E, Cancerson R (1976) Carlton's Histopathological Techniques (4th edn.) Oxford University Press, New York.
- Kandis H, Karapolat S, Yildirim U, Saritas A, Gezer S, et al. (2010) Effects of *Urtica dioica* on hepatic ischemia-reperfusion injury in rats. Clinics (Sao Paulo) 65: 1357-1361.
- Harvey JW, French TW, Senior DF (1986) Hematologic abnormalities associated with chronic acetaminophen administration in a dog. J Am Vet Med Assoc 189: 1334-1335.
- Payasi A, Chaudhary M, Singh BM, Gupta A, Sehgal R (2010) Sub-Acute Toxicity Studies of Paracetamol Infusion in Albino Wistar Rats. Intern J Pharm Sci Drug Res 2:142-145.
- Cheesbrough M (2006) District Laboratory Practice in Tropical Countries: Part 2. Cambridge University Press, New York, USA.

32. Korpi-Steiner NL, Hoyne JB, Hoyer JD, Saenger AK (2008) Hemolytic anemia following attempted suicide. Clin Chem 54: 2071-2074.
33. FDA reports (2009) List of reactions reported by people taking Acetaminophen.
34. Habib-ur-Rehman M, Mahmood T, Salim T, Afzal N, Ali N, et al. (2009) Affect of silymarin on serum levels of ALT and GGT in ethanol induced hepatotoxicity in albino rats. J Ayub Med Coll Abbottabad 21: 73-75.
35. Olaleye MT, Amobonye AE, Komolafe K, Akinmoladun AC (2014) Protective effects of Parinari curatellifolia flavonoids against acetaminophen-induced hepatic necrosis in rats. Saudi J Biol Sci 21: 486-492.
36. Konrad L, Müller HH, Lenz C, Laubinger H, Aumüller G, et al. (2000) Antiproliferative effect on human prostate cancer cells by a stinging nettle root (*Urtica dioica*) extract. Planta Med 66: 44-47.
37. Thapa BR, Walia A (2007) Liver function tests and their interpretation. Indian J Pediatr 74: 663-671.
38. Lemini C, Jaimez R, Franco Y (2007) Gender and inter-species influence on coagulation tests of rats and mice. Thromb Res 120: 415-419.
39. El-Sayed el-SM, Mansour AM, Nady ME (2015) Protective effects of pterostilbene against acetaminophen-induced hepatotoxicity in rats. J Biochem Mol Toxicol 29: 35-42.
40. Gilani AH, Janbaz KH (1995) Preventive and curative effects of Artemisia absinthium on acetaminophen and CCl4-induced hepatotoxicity. Gen Pharmacol 26: 309-315.
41. Bray BJ, Perry NB, Menkes DB, Rosengren RJ (2002) St. John's wort extract induces CYP3A and CYP2E1 in the Swiss Webster mouse. Toxicol Sci 66: 27-33.
42. Iyanda AA, Anetor JI, Oparinde DP, Adeniyi FA (2010) Effects of methionine containing paracetamol formulation on serum vitamins and trace elements in male rats. Niger J Physiol Sci 25: 129-134.
43. Hinson JA, Roberts DW, James LP (2010) Mechanisms of acetaminophen-induced liver necrosis. Handb Exp Pharmacol : 369-405.
44. Meganathan M, Madhana Gopal K, Sasikala P, Mohan J, Gowdhaman N, et al. (2011) Evaluation of Hepatoprotective Effect of Omega 3-Fatty Acid against Paracetamol Induced Liver Injury in Albino Rats. Glob J Pharmacol 5: 50-53.