

Protective Effects of Umbelliferone in Experimental Testicular Ischaemia/Reperfusion Injury in Rats

Ayman M. Mahmoud*

Physiology Division, Zoology Department, Faculty of Science, Beni-Suef University, Salah Salim St., 62514, Beni-Suef, Egypt

Abstract

Testicular torsion, a true emergency urologic case, causes biochemical and morphological changes mediated by ischaemia/reperfusion injury of the testicular tissue. Ischaemia/reperfusion injury is associated with excessive production of reactive oxygen and nitrogen species. The present study was designed to investigate the possible protective effects of umbelliferone (UMB) in a rat model of testicular torsion/detorsion, focusing on oxidative stress and antioxidant defenses. Rats were pre-treated with either 50 or 100 mg/kg body weight UMB for 7 days through oral gavage. Rats were then subjected to testicular torsion for 2 h, and an orchiectomy was performed after 2 h of detorsion. The levels of lipid peroxidation and nitric oxide were significantly ($P < 0.001$) increased in the testis of torsion/detorsion-induced rats. Testicular reduced glutathione, superoxide dismutase and glutathione peroxidase as well as serum inhibin B levels were decreased significantly ($P < 0.001$) after torsion/detorsion. Pre treatment of the torsion/detorsion-induced rats with either UMB dose markedly decreased lipid peroxidation and nitric oxide levels, and ameliorated testicular antioxidant defenses and serum inhibin B levels. In addition, UMB-treated animals displayed an improved histological appearance. It could be concluded that the cytoprotective effects of UMB on the ischaemia/reperfusion testicular injury are mediated through attenuation of oxidative stress.

Keywords: Ischemia/reperfusion; Testicular torsion; 7-hydroxycoumarin; Inhibin B; Oxidative stress

Introduction

Testicular torsion is a true emergency urologic case and a delay in its management can lead to loss of the testicle [1]. It is common during the pubertal period and appears as an urgent urological problem causing deterioration in testicular functions [2]. Ischaemia/reperfusion resulting from testicular torsion/detorsion is the initial pathophysiologic event in this urologic case [3]. Ischaemia/reperfusion injury is associated with superfluous production of reactive oxygen species (ROS) and reactive nitrogen species (RNS) [4]. In addition, ischaemia/reperfusion injury involves neutrophil recruitment [5], lipid peroxidation, apoptosis, pro-inflammatory cytokines, anoxia and alteration to microvascular blood flow [6]. Upon reperfusion, oxygen is supplied to the testes leading to production of ROS, which can cause endothelial damage, germinal cell apoptosis and DNA damage [7]. Because of the imbalance between the mitochondrial respiratory function and restoration of oxygen, ischaemia/reperfusion injury is associated also with excessive generation of mitochondrial superoxide [8]. Therefore, attenuation of ischaemia/reperfusion-induced oxidative stress can offer an important strategy for preventing testicular injury after torsion/detorsion. Umbelliferone (UMB; 7-hydroxycoumarin; Figure 1 is a coumarin derivative widely distributed in plants with free radical scavenging and antioxidant properties [9]. UMB has been reported to exhibit potent antioxidant, anti-inflammatory, antitumor and antidiabetic effects [10-12]. Recently, Wang et al. [13] reported the protective effects of UMB on cerebral ischemia/reperfusion injury. However, no studies have discussed the ameliorative effects of UMB in ischemia/reperfusion injury in testicular torsion. The present study was designed to investigate the possible protective effects of UMB against ischemia/reperfusion-induced oxidative stress in a model of testicular torsion in rats.

Materials and Methods

Chemicals

Umbelliferone (UMB), glutathione (GSH), thiobarbituric acid

(TBA), pyrogallol, 5,5'-dithiobis-(2-nitrobenzoic acid) (DTNB), trichloroacetic acid (TCA), 1,1,3,3-tetramethoxypropane were 4 purchased from Sigma (USA). All other chemicals used were commercially available and of analytical grade.

Experimental animals

White male albino rats weighting about 130-150 g obtained from the animal house of the National Research Centre (Giza, Egypt), were used in the present investigation. They were kept under observation for one week before the onset of the experiment for habituation and to exclude any intercurrent infection. The chosen animals were housed in plastic good aerated cages at normal atmospheric temperature ($25 \pm 2^\circ\text{C}$) as well as normal 12 h light/dark cycle. Rats were given access of water and supplied daily with standard diet of known composition. The experiments were conducted in accordance with the ethical guidelines for investigation of laboratory animals and were approved by Committee of Beni-Suef University (Egypt).

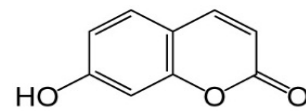


Figure 1: Structure of Umbelliferone.

*Corresponding author: Ayman M. Mahmoud, Physiology Division, Zoology Department, Faculty of Science, Beni-Suef University, Salah Salim St., 62514, Beni-Suef, Egypt, Tel: +201144168280; E-mail: ayman.mahmoud@science.bsu.edu.eg

Received December 09, 2015; Accepted December 18, 2015; Published December 21, 2015

Citation: Mahmoud AM (2016) Protective Effects of Umbelliferone in Experimental Testicular Ischaemia/Reperfusion Injury in Rats. Anat Physiol 6: 189. doi:10.4172/2161-0940.1000189

Copyright: © 2016 Mahmoud AM. This is an open-access article distributed under the terms of the Creative Commons Attribution License, which permits unrestricted use, distribution, and reproduction in any medium, provided the original author and source are credited.

Experimental design

Twenty-four rats were divided into four groups (N = 6) and anesthetized with ketamine (90 mg/kg). Following anesthesia, a midline incision was made in the scrotum. In all the groups except for the sham-operated group, torsion was created by rotating the right testis 720° clockwise for 2 h. The torsion was maintained by fixing the testis in the scrotum with a silk suture, and the incision was closed. The suture was removed, and the right testis was then detorted and replaced in the scrotum for 2 h.

Group I (Sham-operated): Received the vehicle 0.5% carboxymethylcellulose (CMC) orally for 7 days. Testes were taken out through the incision lines then replaced, and a silk suture was placed through the tunica albuginea.

Group II (Torsion/Detorsion): Received the vehicle 0.5% CMC orally for 7 days and subjected to torsion/detorsion.

Group III (50 mg UMB/Torsion/Detorsion): Received 50 mg/kg body weight umbelliferone dissolved in 0.5% CMC orally for 7 days and subjected to torsion/detorsion.

Group IV (100 mg UMB/Torsion/Detorsion): Received 100 mg/kg body weight umbelliferone dissolved in 0.5% CMC orally for 7 days and subjected to torsion/detorsion.

Samples preparation

At the end of the experiment, animals were sacrificed and blood samples were collected, left to coagulate and centrifuged at 3000 rpm for 10 min to separate serum. Testes were immediately excised, cleaned and washed twice with ice-cold saline. The testes (10% w/v) were homogenized in chilled phosphate buffered saline (PBS), and then centrifuged at 3000 rpm for 15 min. The clear homogenates were collected and stored at -20°C for biochemical analysis. Other samples from the testes were fixed in 10% buffered formalin for histological study.

Biochemical assays

Assay of lipid peroxidation: Lipid peroxidation was determined in the testicular homogenate by measuring malondialdehyde (MDA) according to the method of Preuss et al. [14]. Briefly, tissue homogenate was precipitated with 76% TCA and the mixture was centrifuged at 3000 rpm for 10 min. The supernatant was collected and mixed with 1.07% TBA, then incubated for 30 min at 80°C with shaking. After incubation, cold 90% TCA was added, and the absorbance was determined at 532 nm. 1,1,3,3 tetramethoxypropane served as a standard.

Assay of nitric oxide

Nitric oxide level was estimated in the testicular homogenate as nitrite according to the method of Montgomery and Dymock [15] using reagent kit purchased from Biodiagnostics (Egypt). The assay is based on the Griess method which is a simple colorimetric reaction between nitrite, N-(1-naphthyl) ethylenediamine and sulfonamide to produce a pink product with maximum absorbance at 543 nm.

Assay of reduced glutathione (GSH): GSH concentration was determined in the homogenate of testis according to the method of Beutler et al. [16]. Tissue homogenate was precipitated with a solution containing 1.67% glacial metaphosphoric acid, 0.2% EDTA and 30% NaCl, and incubated for 5 min followed by centrifugation at 3000 rpm. The clear supernatant was mixed with Na₂HPO₄ and DTNB reagent. The absorbance was measured at 412 nm.

Assay of superoxide dismutase (SOD) activity: SOD activity was determined in the homogenate of testis according to the method of Marklund and Marklund [17]. The reaction mixture consisted of tissue homogenate, Tris/EDTA buffer (pH 8.0), 10 mM pyrogallol and distilled water. The absorbance at zero time and after 10 min was measured at 420 nm. One enzyme unit is defined as the enzyme activity that inhibits autooxidation of pyrogallol by 50%.

Assay of glutathione peroxidase (GPx) activity: GPx activity was assayed according to the method of Matkovic et al. [18]. Briefly, the tissue homogenate, Tris buffer (pH 7.6), 3.28 mM hydrogen peroxide and 2 mM GSH were mixed and incubated for 10 min at room temperature. A precipitating solution containing 1.67% glacial metaphosphoric acid, 0.2% EDTA and 30% NaCl was added, and samples were centrifuged at 3000 rpm for 5 min. The supernatant was separated and mixed with DTNB, and the absorbance was measured at 412 nm.

Assay of serum inhibin B: Serum inhibin B concentration was determined using ELISA kit purchased from ABNOVA (USA), according to the manufacturer's instruction. The assay is a quantitative test for detecting inhibin B peptide based on the principle of competitive enzyme immunoassay.

Histopathological Study

The testes were flushed with cold saline and then fixed in 10% buffered formalin for at least 24 h. The specimens were then dehydrated in ascending series of ethanol, cleared in xylene and embedded in paraffin wax. Blocks were prepared and 4 µm thick sections were cut by a sledge microtome. The paraffin embedded sections were deparaffinized, washed and stained with hematoxylin and eosin (H&E). The stained slides were examined under light microscope.

Statistical Analysis

Statistical analysis was performed using GraphPad Prism 5 software (GraphPad Software, San Diego, CA, USA). Results were expressed as mean ± standard deviation (SD) and all statistical comparisons were made by means of the one-way ANOVA test followed by Tukey's test post hoc analysis. A P value <0.05 was considered significant.

Results

UMB attenuates torsion/detorsion-induced oxidative stress

Data concerning the effects of torsion/detorsion and UMB on testicular lipid peroxidation levels are represented in Figure 2. The lipid peroxidation marker MDA was significantly (P<0.001) elevated in group II (torsion/detorsion) compared to group I (sham operated) (5.54 ± 0.36 versus 2.63 ± 0.32 nmol/100 mg). Pre-treatment of rats with either 50 mg or 100 mg/kg UMB significantly (P<0.001) protected rats against torsion/detorsion-induced lipid peroxidation; the recorded results were 3.12 ± 0.24 and 2.78 ± 0.22 nmol/100 mg for the 50 mg and 100 mg/kg UMB doses, respectively.

Nitric oxide levels, assayed as nitrite, showed a significant (P<0.001) increase in testes of group II (torsion/detorsion) rats (70.63 ± 14.43 µmol/100 mg) when compared with the sham operated group (26.22 ± 2.75 µmol/100 mg), as depicted in Figure 3. The testes of rats pre-treated with 50 mg/kg UMB for 7 days and then exposed to torsion/detorsion showed significant (P<0.01) decrease in nitrite content (39.23 ± 2.65 µmol/100 mg). Similarly, rats pre-treated with 100 mg/kg UMB exhibited significant (P<0.001) decrease in testicular nitrite

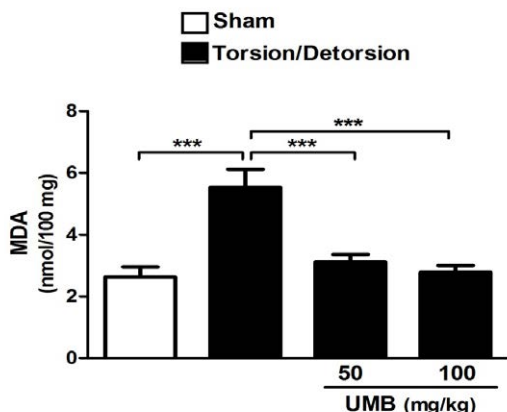


Figure 2: Effect of UMB on testicular lipid peroxidation levels. Data are mean ± SD, (N=6). ***P<0.001.

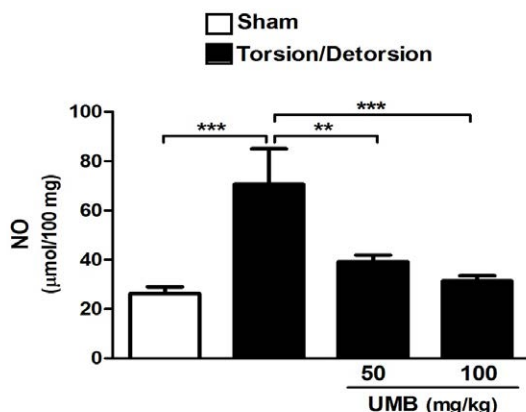


Figure 3: Effect of UMB on testicular nitric oxide levels. Data are mean ± SD, (N=6). **P<0.01 and ***P<0.001.

content ($31.39 \pm 2.15 \mu\text{mol}/100 \text{ mg}$) when compared with the torsion/detorsion group.

UMB ameliorates antioxidant defenses in torsion/detorsion-induced rats

Torsion/detorsion significantly ($P<0.001$) decreased testicular GSH content in group II when compared to the sham operated group (6.05 ± 1.31 versus $16.89 \pm 1.41 \text{ nmol}/100 \text{ mg}$). Rats pre-treated with either 50 mg or 100 mg/kg UMB showed significant ($P<0.001$) increase in testicular GSH content when compared with the torsion/detorsion group; the recorded results were 14.94 ± 1.69 and $15.83 \pm 1.79 \text{ nmol}/100 \text{ mg}$ for the 50 mg and 100 mg/kg UMB doses, respectively (Figure 4).

SOD activity showed a significant ($P<0.001$) decrease in testes of torsion/detorsion-induced rats ($1.54 \pm 0.31 \text{ U/g}$) when compared with the sham operated group ($3.92 \pm 0.27 \text{ U/g}$), as represented in Figure 5. Pre-treatment of the torsion/detorsion-induced rats with 50 mg/kg UMB dose produced significant ($P<0.01$) amelioration of the SOD activity ($2.83 \pm 0.29 \text{ U/g}$). Likewise, the 100 mg/kg UMB dose significantly increased SOD activity ($3.00 \pm 0.32 \text{ U/g}$) when compared with the torsion/detorsion group.

Testicular GPx activity exhibited the same behavioral pattern where it was decreased in torsion/detorsion-induced rats (15.16 ± 1.72

U/g) when compared with the sham group ($6.37 \pm 0.79 \text{ U/g}$; Figure 6). Pre-treatment of the torsion/detorsion-induced rats with either dose of UMB significantly ($P<0.001$) alleviated testicular GPx activity; the recorded results were 13.22 ± 1.98 and $14.01 \pm 1.27 \text{ U/g}$ for the 50 mg and 100 mg/kg UMB doses, respectively.

UMB increases serum inhibin B levels in torsion/detorsion-induced rats

Serum inhibin B levels showed a significant ($P<0.001$) decrease in torsion/detorsion group ($38.23 \pm 4.28 \text{ pg/ml}$) when compared with the sham operated rats ($78.07 \pm 8.13 \text{ pg/ml}$). Rats pre-treated with 50 mg/kg UMB dose showed significant ($P<0.001$) increase in serum inhibin B level ($70.71 \pm 5.89 \text{ pg/ml}$). Similarly, rats received the higher UMB dose (100 mg/kg) for 7 days before torsion/detorsion exhibited a significant ($P<0.001$) increase in serum inhibin B ($72.13 \pm 6.00 \text{ pg/ml}$) when compared with the torsion/detorsion group, as represented in Figure 7.

UMB mitigates torsion/detorsion-induced histological alterations in rats

Histopathological study revealed normal histological appearance of testicular tissue of group I (Figure 8A). In the testicular tissue sections of group II (torsion/detorsion), there were some histopathological changes including, degeneration, disorganization and desquamation

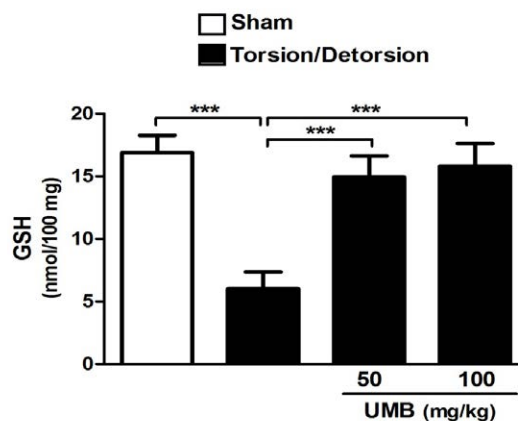


Figure 4: Effect of UMB on testicular reduced glutathione levels. Data are mean ± SD, (N=6). ***P<0.001.

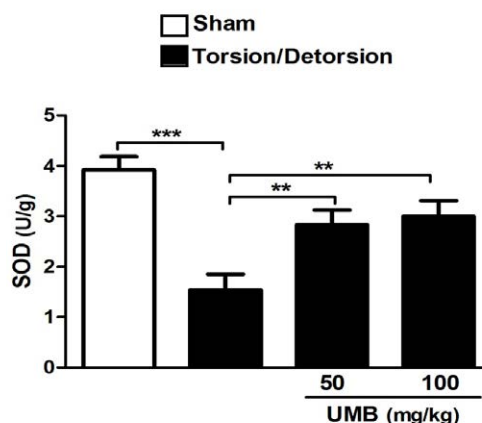
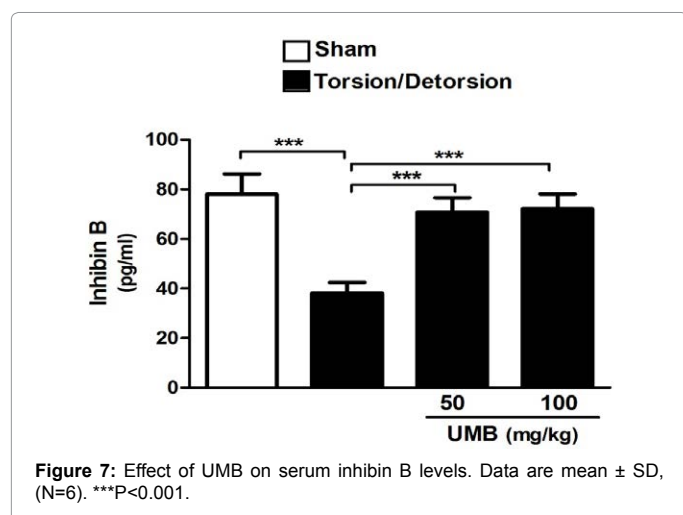
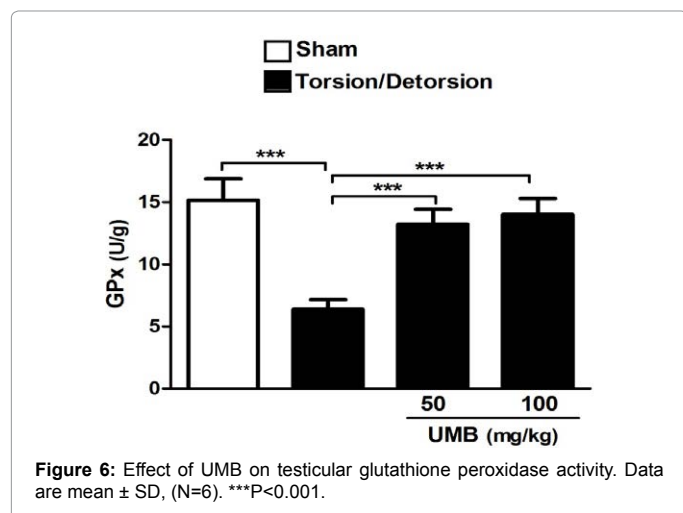


Figure 5: Effect of UMB on testicular superoxide dismutase activity. Data are mean ± SD, (N=6). **P<0.01 and ***P<0.001.



in germinal cells, and interstitial oedema, capillary congestion and hemorrhage (Figure 8B; Table 1). In rats pre-treatment with either dose of UMB, these histopathological changes were significantly less obvious, as shown in Table 1 and Figures 8C and 8D, respectively.

Discussion

In this investigation, we evaluated the effects of pre-treatment with UMB in a rat model of testicular torsion. We found for the first time that UMB pre-treatment protected testicular tissue against ischemia/reperfusion injury through attenuation of oxidative stress and potentiating the antioxidant defenses.

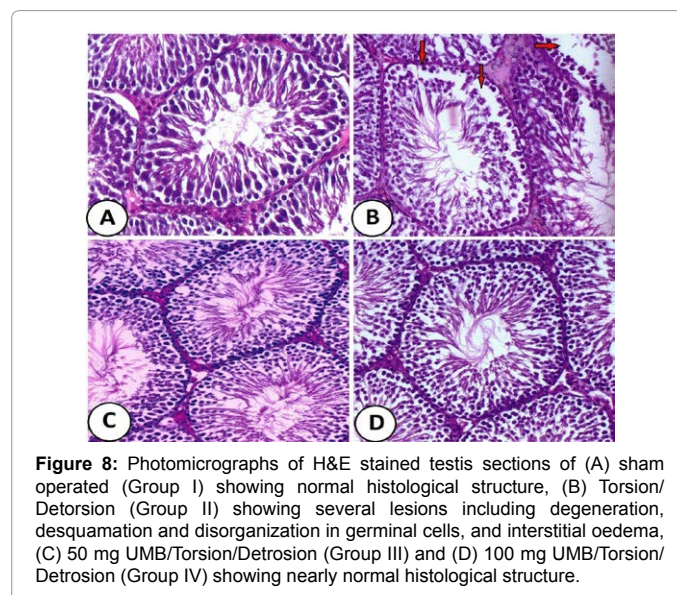
Testicular torsion/detorsion induces biochemical and morphological changes mediated by ischemia/reperfusion injury such as oxidative stress [4]. Here, testicular torsion/detorsion induced significant increase in lipid peroxidation and nitric oxide. Because of their high concentration of polyunsaturated fatty acids in the plasma membrane, mammalian testes are vulnerable to oxidative stress, particularly to lipid peroxidation [19]. In addition, decreased blood flow during ischemia causes hypoxia which results in elevated levels of lipid peroxides, lactic acid and hypoxanthine in ischemic tissue [20]. Thereafter, increased blood flow after ischemia leads to the production of large amounts of ROS and RNS. This is known as reperfusion injury which induces oxidative stress and further damage in the ischemic

tissue [20]. Moreover, Lysiak et al. [21] stated that ischemia/reperfusion injury in many aspects resemble an inflammatory response connected with recruitment of activated neutrophils in the testis. The reperfusion neutrophils activate nicotinamide adenine dinucleotide phosphate (NADPH) oxidase resulting in increased ROS production [22].

Pre-treatment of the torsion/detorsion-induced rats with UMB markedly decreased lipid peroxidation and nitric oxide in the testes, suggesting a protective effect of UMB against ischemia/reperfusion injury. Nitric oxide has a key role in modulating tissue injury and blood flow under normal and several pathological conditions [23]. In the present study, the elevated nitric oxide levels could be attributed to overproduction by activated inducible nitric oxide synthase [24]. Through its radical scavenging property, UMB markedly decreased nitric oxide levels in the testes. The antioxidant and radical scavenging activity of UMB has been reported in several studies [10-13].

GSH and enzymatic antioxidants showed significant decrease in testes of the rats subjected to torsion/detorsion, an effect that was reversed by UMB pre-treatment. Therefore, it seems that the protective mechanism of UMB on ischemia/reperfusion injury is mediated, at least in part, via potentiating the antioxidant defenses. In parallel to our study, a recent study conducted by Wang et al. [13] demonstrated that UMB significantly increased enzymatic defenses in a rat model of cerebral ischemia/reperfusion injury. In addition, Sim et al. [25] demonstrated that UMB increased the gene expression and activity of SOD and catalase in liver of chronic alcohol-fed rats, and thus, decreased lipid peroxide and mitochondrial ROS levels.

Histopathological examination of testicular tissue from the rats exposed to torsion/detorsion revealed increased disorganization



Histopathological lesions	T/D	T/D + 50 mg UMB	T/D + 100 mg UMB S/T/D
Degeneration in germinal cells	++	+	+
Reduction in germinal cell counts	-	-	-
Disorganisation in germinal cells	++	-	-
Desquamation in germinal cells	++	-	-
Interstitial oedema	+	-	-
Haemorrhage	+	-	-

Table 1: Histopathological lesions in testis of experimental groups.

and degeneration in germinal cells, and capillary congestion and interstitial oedema, which were ameliorated by UMB pre-treatment. The protective effects of UMB on the testis after testicular ischemia/reperfusion injury was further confirmed by assaying inhibin B which showed a significant decrease in serum of torsion/detorsion-induced rats. Reduced circulating inhibin B levels have been demonstrated in adolescent boys after testicular torsion, particularly after orchidectomy [26]. Ozkan et al. [27] compared serum inhibin B levels to histopathologic parameters (Johnsen's score) on contralateral testicular damage after unilateral testicular torsion and suggested that determination of inhibin B levels to evaluate testicular damage is more effective than histopathologic examination and also evaluates complete testicular function. Pre-treatment with UMB restored the reduced levels of serum inhibin B, suggesting both potent protective effect of UMB and high value of serum inhibin B in evaluating testicular damage after torsion/detorsion.

In conclusion, the present study confers new information that pre-treatment with UMB could induce protective effects against testicular ischemia/reperfusion injury as demonstrated by increased serum inhibin B, potentiated testicular antioxidant defenses and attenuated oxidative stress.

Conflict of Interest

Authors declared that they have no conflict of interest.

Funding

This research received no specific grant from any funding agency in the public, commercial, or not-for-profit sectors.

References

1. Visser AJ, Heyns CF (2003) Testicular function after torsion of the spermatic cord. *BJU Int* 92: 200-203.
2. Barada JH, Weingarten JL, Cromie WJ (1989) Testicular salvage and age-related delay in the presentation of testicular torsion. *J Urol* 142: 746-748.
3. Viguera RM, Reyes G, Rojas-Castañeda J, Rojas P, Hernández R (2004) Testicular torsion and its effects on the spermatogenic cycle in the contralateral testis of the rat. *Lab Anim* 38: 313-320.
4. Filho DW, Torres MA, Bordin AL, Crezcynski-Pasa TB, Boveris A (2004) Spermatic cord torsion, reactive oxygen and nitrogen species and ischemia-reperfusion injury. *Mol Aspects Med* 25: 199-210.
5. Turner TT, Bang HJ, Lysiak JL (2004) The molecular pathology of experimental testicular torsion suggests adjunct therapy to surgical repair. *J Urol* 172: 2574-2578.
6. Cuzzocrea S, Riley DP, Caputi AP, Salvemini D (2001) Antioxidant therapy: a new pharmacological approach in shock, inflammation, and ischemia/reperfusion injury. *Pharmacol Rev* 53: 135-159.
7. Yaaymurdur H, Nuhoaylu B (2008) Effect of phosphodiesterase 5 inhibitors on apoptosis and nitric oxide synthases in testis torsion: an experimental study. *Pediatr Surg Int* 24: 205-211.
8. Jung JE, Kim GS, Chen H, Maier CM, Narasimhan P, et al. (2010) Reperfusion and neurovascular dysfunction in stroke: from basic mechanisms to potential strategies for neuroprotection. *Mol Neurobiol* 41: 172-179.
9. Zhao D, Islam MN, Ahn BR, Jung HA, Kim BW, et al. (2012) In vitro antioxidant and anti-inflammatory activities of *Angelica decursiva*. *Arch Pharm Res* 35: 179-192.
10. Ramesh B, Pugalendi KV (2006) Antihyperglycemic effect of umbelliferone in streptozotocin-diabetic rats. *J Med Food* 9: 562-566.
11. Lima FO, Nonato FR, Couto RD, Barbosa Filho JM, Nunes XP, et al. (2011) Mechanisms involved in the antinociceptive effects of 7-hydroxycoumarin. *J Nat Prod* 74: 596-602.
12. Vasconcelos JF, Teixeira MM, Barbosa-Filho JM, Agra MF, Nunes XP, et al. (2009) Effects of umbelliferone in a murine model of allergic airway inflammation. *Eur J Pharmacol* 609: 126-131.
13. Wang X, Li R, Wang X, Fu Q, Ma S (2015) Umbelliferone ameliorates cerebral ischemiareperfusion injury via upregulating the PPAR gamma expression and suppressing TXNIP/NLRP3 inflammasome. *Neurosci Lett* 600: 182-187.
14. Preuss HG, Jarrell ST, Scheckenbach R, Lieberman S, Anderson RA (1998) Comparative effects of chromium, vanadium and gymnema sylvestre on sugar-induced blood pressure elevations in SHR. *J Am Coll Nutr* 17: 116-123.
15. Montgomery H, Dymock J (1961) The determination of nitrite in water. *Analyst* 86: 414-416.
16. Beutler E, Duron O, Kelly BM (1963) Improved method for the determination of blood glutathione. *J Lab Clin Med* 61: 882-888.
17. Marklund S, Marklund G (1974) Involvement of the superoxide anion radical in the autoxidation of pyrogallol and a convenient assay for superoxide dismutase. *Eur J Biochem* 47: 469-474.
18. Matkovic B, Szabo L, Varga IS (1998) Determination of enzyme activities in lipid peroxidation and glutathione pathways (in Hungarian). *Laboratoriumi Diagnosztika* 15: 248-249.
19. Hekimoglu A, Kurcer Z, Aral F, Baba F, Sahna E, et al. (2009) Lycopene, an antioxidant carotenoid, attenuates testicular injury caused by ischemia/reperfusion in rats. *Tohoku J Exp Med* 218: 141-147.
20. Akora B, Altu ME, Balci A, Hakverdi S, Ynden Z, et al. (2008) Gradual detorsion of torsioned rat testis attenuates ischemia reperfusion injury. *J Pediatr Surg* 43: 1879-1884.
21. Lysiak J, Nguyen QA, Turner T (2002) Peptide and nonpeptide reactive oxygen scavengers provide partial rescue of the testis after torsion. *J Androl* 23: 400-409.
22. Salmasi AH, Beheshtian A, Payabvash S, Demehri S, Ebrahimkhani MR, et al. (2005) Effect of morphine on ischemia-reperfusion injury: experimental study in testicular torsion rat model. *Urology* 66: 1338-1342.
23. Serarslan Y, Yönden Z, Ozgiray E, Oktar S, Güven EO, et al. (2010) Protective effects of tadalafil on experimental spinal cord injury in rats. *J Clin Neurosci* 17: 349-352.
24. Andiran F, Okur DH, Kilinc A, Gedikoglu G, Kilinc K, et al. (2000) Do experimentally induced ipsilateral testicular torsion, vas deferens obstruction, intra-abdominal testis or venous obstruction damage the contralateral testis through a common mechanism? *Br J Urol Int* 85: 330-335.
25. Sim MO, Lee HI, Ham JR, Seo KI, Kim MJ, et al. (2015) Anti-inflammatory and antioxidant effects of umbelliferone in chronic alcohol-fed rats. *Nutr Res Pract* 9: 364-369.
26. Taskinen S, Taskinen M, Rintala R (2008) Testicular torsion: orchietomy or orchiopexy? *J Pediatr Urol* 4: 210-213.
27. Ozkan KU, Aydin M, Muhtarou S, Konta O (2001) Evaluation of contralateral testicular damage after unilateral testicular torsion by serum inhibin B levels. *J Pediatr Surg* 36: 1050-1053.