

Proper Management of Rapidly Growing Large B-Cell Primary Thyroid Lymphoma, Case Report and Review of Literature

Mohamed Tarek Hafez* and Richard W Nason

Section of Surgical Oncology, Department of Surgery, CancerCare Manitoba, University of Manitoba, GF440 A 820 Sherbrook Street, Winnipeg, Manitoba, R3A 1R9, Canada

*Corresponding author: Mohamed Tarek Hafez, MD, Section of Surgical Oncology, Department of Surgery, CancerCare Manitoba, University of Manitoba, GF440 A 820 Sherbrook Street, Winnipeg, Manitoba, R3A 1R9, Canada, Tel: 00201211700004; E-mail: mthafez@yahoo.com

Received date: January 20, 2017; Accepted date: February 9, 2017; Published date: February 14, 2017

Copyright: © 2017 Hafez MT, et al. This is an open-access article distributed under the terms of the Creative Commons Attribution License, which permits unrestricted use, distribution, and reproduction in any medium, provided the original author and source are credited.

Abstract

Background: Primary thyroid lymphoma is a rare type of thyroid cancer. It accounts for 1 to 5% of all thyroid cancers and 1 to 2% of all lymphomas outside the lymph nodes. Frequently, based on histology and fine-needle aspiration biopsy (FNA), it is difficult to distinguish between anaplastic carcinoma and thyroid lymphoma. Open biopsy is usually needed to confirm diagnosis

Case Presentation: We present the clinical history, physical findings, imaging studies and treatment plan of a 60-year-old male patient with malignant B cell lymphoma of the thyroid gland. The patient was presented to cancer care Manitoba with rapidly growing neck mass and Hoarseness for three weeks. CT scan of the neck showed large right-sided paratracheal mass consistent with thyroid malignancy, with destruction of the right side of the thyroid cartilage and abnormal small Level II right-sided nodes. The mass was measured to be 7.1 × 4.5 × 5.7 cm. There was displacement of the trachea to the left, but with no compromise of the airway noted. FNA was not diagnostic. Open biopsy under general anesthesia was done and sent for frozen section, which came suggestive of lymphoma. The patient kept intubated in surgical ICU and started on high dose steroid until the diagnosis was confirmed as B-Cell lymphoma then medical oncology staff managed him.

Conclusion: Lymphoma of the thyroid gland should be considered in patients with a rapidly enlarging goiter. If there is any doubt of the diagnosis, open surgical biopsy should be performed to confirm the diagnosis.

Keywords: Thyroid; Lymphoma, B-Cell; Thyroid Cancer

Abbreviations FNA: Fine-Needle Aspiration; ICU: Intensive Care Unit; PTL: Primary Thyroid Lymphoma; CLT: Chronic Lymphocytic Thyroiditis; DLBCL: Diffuse Large B Cell Lymphoma; MALT: Mucosa Associated Lymphatic Tissue; NHL: Non Hodgkin Lymphoma; R-CHOP: Rituximab, Cyclophosphamide, Doxorubicin, Oncovin, Prednisone; CT: Computed Tomography; MRI: Magnetic Resonance Imaging

Introduction

Primary thyroid lymphoma (PTL) accounts for 1-5% of thyroid tumors and 1-2.5% of all lymphomas. The most common clinical presentation of PTL is a rapidly enlarging thyroid mass associated with compressive symptoms like dyspnea, dysphagia and pain [1]. Association of chronic lymphocytic thyroiditis (CLT) with PTL has been found to be between 25 and 75% [2]. However not all patients of CLT develop lymphoma of the thyroid gland. Pathologically two-thirds of PTL are represented by diffuse large B cell lymphoma (DLBCL) arising either de novo or in the context of a concomitant indolent non Hodgkin Lymphoma of the mucosa associated lymphatic tissue (MALT) [3]. The optimal management for a PTL is chemotherapy, radiation therapy. The role for surgery has its utmost importance in emergency situations to relieve compression and for diagnostic purposes.

Frequently, based on histology and fine-needle aspiration cytology (FNA), it is difficult to distinguish between anaplastic thyroid cancer and thyroid lymphoma. In most instances, thyroid lymphoma is diagnosed only after thyroid surgery for suspicious carcinoma [4].

The increased use of immunocytochemical lymphoid markers has improved the diagnosis and categorization of thyroid lymphoma [5]. Cases which were previously diagnosed, as anaplastic carcinoma could turn out to be primary thyroid lymphoma. Recent onset of symptoms or a rapid change in size of a pre-existing thyroid mass are the hallmarks of both thyroid lymphoma and anaplastic carcinoma [6]. It is important to distinguish between these two tumors because anaplastic carcinoma has a much poorer prognosis, with few patients surviving beyond 2 years, whereas primary thyroid lymphoma has a favorable outcome with cyclophosphamide based multimodality chemotherapy in combination with radiotherapy [4].

Case Presentation

60-year-old gentleman was seen at Cancer Care Manitoba referred for three-week history of a neck mass. Prior to this, he had not noticed any neck nodules or any neck symptoms. He noted that the mass has progressively increased in size in the last three weeks. He also noted hoarse voice as well as dysphagia, which he felt, has progressed. He did describe dysphagia for both solids and liquids. He did not describe any shortness of breath or any B symptoms. There was no family history of thyroid malignancy and no history of head and neck radiation.

On examination, there was a large neck mass and some leftward displacement of the trachea. Also, there was a tender right-sided Level II lymph node on examination. There was no axillary lymphadenopathy noted, and no splenomegaly noted.

He had a Computed tomography (CT) of the neck done in June 2014. There was noted to be a large right-sided paratracheal mass consistent with thyroid malignancy, with destruction of the right side of the cartilage and abnormal small Level II right-sided nodes. The mass was measured to be 7.1 × 4.5 × 5.7 cm. There was displacement of the trachea to the left, but with no compromise of the airway noted.

To further investigate, we arranged for him to have an urgent neck ultrasound done and fine needle aspiration biopsy. FNA biopsy came as unsatisfactory for diagnosis. Another FNA biopsy was taken and came as predominantly lymphocytes, neutrophils, and tiny microphages and these features were not diagnostic. He was booked for open biopsy versus thyroidectomy as the possible diagnosis with this patient would be lymphoma versus anaplastic thyroid cancer.

After awake intubation, the central compartment of the neck was approached and there were no planes between thyroid and strap muscles. We elected to perform open biopsy and frozen section which was most consistent with thyroid lymphoma. We terminated the procedure at this point and in consultation with surgical intensive care unit, the patient was kept intubated till the final diagnosis is confirmed. He started high dose steroids for four days, which had produced a dramatic resolution in the tumor. The final diagnosis came back as diffuse large B-cell lymphoma of the thyroid gland and the patient started on prednisone 50 mg a day.

The patient is going to continue on prednisone 50 mg a day for the moment and we have applied for R-CHOP (Rituximab, Cyclophosphamide, Doxorubicin, Oncovin®, Prednisone). He continued to take the prednisone 50 mg a day up until the first R-CHOP and after the R-CHOP the prednisone was tapered off. He had four cycles with R-CHOP. Post treatment infused CT scan of the neck was ordered and showed significant interval improvement; the previously noted soft tissue mass in relation to the right thyroid is no longer evident and the right level II lymph node has decreased in size. Other neck lymph nodes have also decreased in size.

Review of Literature

Primary thyroid lymphoma includes less than 5% of extranodal non-Hodgkin lymphoma and less than 5% of all thyroid cancers. Development of immunocytochemical lymphoid markers has improved the success rate of an accurate diagnosis of thyroid lymphoma by FNA. Although thyroid lymphoma is not a common cancer, it is very important to distinguish primary thyroid lymphoma from anaplastic thyroid carcinoma since the prognosis is very different; few patients with anaplastic thyroid carcinoma survive beyond 2 years; while primary thyroid lymphoma generally has a favorable outcome [5].

Malignant tumors of the thyroid are largely divided into 2 categories: tumors that originate from the thyroid gland proper and extraordinary tumors that appear as a thyroid gland malignancy (such as thyroid lymphoma, which commonly develop in organs other than the thyroid gland). Thyroid lymphoma is a heterogeneous and diverse disease entity and not a single disease. Most of thyroid lymphomas are of B-cell origin, and few histologic subtypes are recognized [7].

The most common histologic subtype is DLBCL, which displays the most aggressive clinical course. The second common subtype of histology is MALT, which has a relatively benign clinical course. MALT lymphomas are often associated with Hashimoto's thyroiditis.

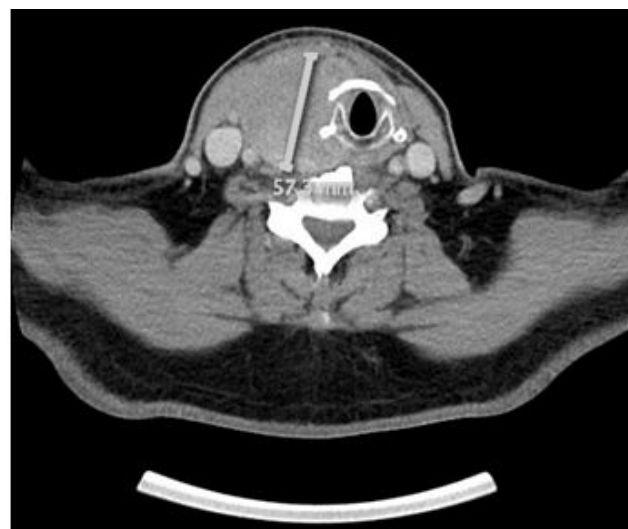


Figure 1: Pre-treatment CT scan showing the larger thyroid mass.

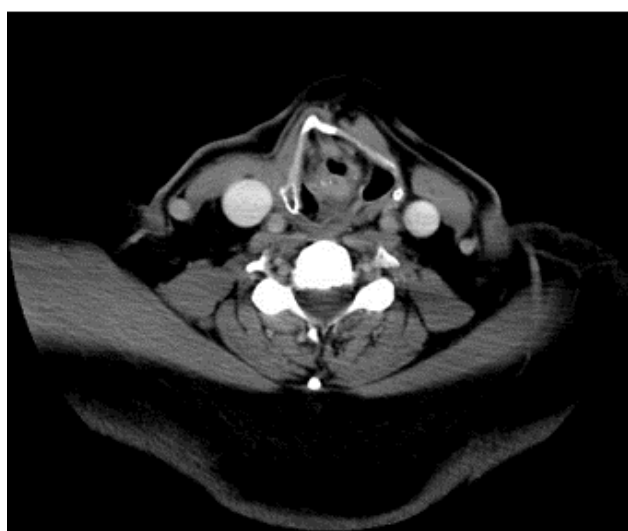

Figure 2: Post-treatment CT scan showing significant interval improvement.

The development of MALT lymphoma from Hashimoto's thyroiditis takes a long time, sometimes as long as 30 years. MALT lymphoma is generally characterized by an indolent clinical course, although transformation from MALT lymphoma to aggressive lymphoma may occur in some cases [8].

Follicular lymphomas usually show a predominantly follicular pattern and oftentimes a clinically protracted course of disease; the response to therapy is short-lived, resulting in frequent recurrences. In order to distinguish DLBCLs from MALT lymphomas and also MALT

lymphomas from Hashimoto's disease, immunohistochemical stains, flow cytometry analysis of biopsy tissue, FNA biopsy, and molecular genetic analysis may be needed to aid in the diagnosis.

The most common presenting symptom is a painless enlargement of the thyroid gland, which is typically seen in up to 50% of cases. The neck mass is usually smooth, bulky, and rubbery. Thyroid lymphomas frequently present on one side of the thyroid gland. Hoarseness, dysphagia, dyspnea, and stridor are also common presenting symptoms. The presence of constitutional symptoms (lymphoma's B symptoms) are not frequent, and few patients experience B symptoms, such as fever, night sweats, and weight loss. Most of thyroid lymphoma patients are euthyroid, yet some can be hypothyroid [9].

Thyroid lymphomas often create diagnostic and therapeutic difficulties. Until FNA was developed in the late 1970s, thyroid lymphoma was frequently diagnosed postoperatively, subsequent to thyroidectomy for presumed thyroid cancer. An ultrasound-guided FNA biopsy of a hypoechoic or pseudocystic lesion is the preferred procedure since a blind FNA is often unable to differentiate malignant lymphoma from chronic lymphocytic thyroiditis. The sufficient tissue sampling is very important for appropriate interpretation of the histopathologic examination. Advances in immunocytochemistry have enhanced the capacity to make the diagnosis of this entity accurate [9].

CT and magnetic resonance imaging (MRI) are the most useful imaging studies for diagnosis and staging of thyroid lymphomas. Ultrasound is also a very useful imaging study in revealing a thyroid nodule that often clearly distinguishes from normal thyroid tissue and is also a helpful tool in the successful localization and FNA procedures, compared with random blind biopsies. However, an ultrasound is not a reliable test in identifying lymphoma invasion to surrounding structures such as lymph nodes, the esophagus, and carotid artery [10,11].

As malignant lymphomas are very sensitive to both chemotherapy and radiotherapy, radiation treatment or combination chemotherapy and radiation therapy has become the standard of thyroid lymphoma treatment. Surgical resection of the thyroid mass is no longer a routine part of the management strategy. Surgery plays a role in biopsy for establishing a correct diagnosis as well as in palliating critical symptoms associated with large obstructive lymphomas [12].

Most treatment failures seem to develop within the first 2 years after therapy, although late recurrences can occur. Regular follow-up is required for early detection of recurrent disease, as well as prompt and appropriate management of hypothyroidism and hypocalcemia. Serum calcium and parathyroid hormone should be monitored. Prolonged, lifelong follow-up seems reasonable as late relapses and second malignancies have been reported. At each follow-up visit, a careful history and a complete physical examination should be performed. The first follow-up visit should be 4 to 6 weeks after completion of treatment and then patients should be followed every 3 to 4 months for the first year. After the first year, patients should be seen every 6 months for the next 2 to 3 years, and then annually thereafter [13].

Based on histological subtype, Derringer et al, found disease-specific 5-year survival rates for MALT lymphoma, mixed lymphoma, and DLBCL of 100, 78, and 71%, respectively. Poor prognostic factors include advanced age and stage, presence of DLBCL, lack of treatment with radiation or surgery, greater tumor size, mediastinal involvement, rapid clinical growth, and the presence of B symptoms, dysphagia, or stridor [5].

Conclusion

Lymphoma of the thyroid gland should be considered in patients with a rapidly enlarging goiter. If there is any doubt of the diagnosis, open surgical biopsy should be performed to confirm the diagnosis.

References

1. Ansell SM, Grant CS, Habermann TM (1999) Primary thyroid lymphoma. *Semin Oncol* 26: 316-323.
2. Anderson T, Chabner BA, Young RC, Berard CW, Garvin AJ, et al. (1982) Malignant lymphoma. 1. The histology and staging of 473 patients at the National Cancer Institute. *Cancer* 50: 2699-2707.
3. Rossi D (2009) Thyroid lymphoma: beyond antigen stimulation. *Leuk Res* 33: 607-609.
4. Nix PA, Nicolaidis A, Coatesworth AP (2006) Thyroid cancer review 3: management of medullary and undifferentiated thyroid cancer. *Int J Clin Pract* 60: 80-84.
5. Derringer GA, Thompson LD, Frommelt RA, Bijwaard KE, Heffess CS, et al. (2000) Malignant lymphoma of the thyroid gland: a clinicopathologic study of 108 cases. *Am J Surg Pathol* 24: 623-639.
6. Wirtzfeld DA, Winston JS, Hicks WL Jr., Loree TR (2001) Clinical presentation and treatment of non-Hodgkin's lymphoma of the thyroid gland. *Ann Surg Oncol* 8: 338-341.
7. Thieblemont C, Mayer A, Dumontet C, Barbier Y, Callet-Bauchu E, et al (2002) Primary thyroid lymphoma is a heterogeneous disease. *J Clin Endocrinol Metab* 87: 105-111.
8. Morgen EK, Geddie W, Boerner S, Bailey D, Santos GC (2010) The role of fine-needle aspiration in the diagnosis of thyroid lymphoma: a retrospective study of nine cases and review of published series. *J Clin Pathol* 63: 129-133.
9. Sarinah B, Hisham AN (2010) Primary lymphoma of the thyroid: diagnostic and therapeutic considerations. *Asian J Surg* 33: 20-24.
10. Takashima S, Ikezoe J, Morimoto S, Harada K, Kozuka T, et al. (1989) MR imaging of primary thyroid lymphoma. *J Comput Assist Tomogr* 13: 517-518.
11. Takashima S, Morimoto S, Ikezoe J, Arisawa J, Hamada S, et al. (1989) Primary thyroid lymphoma: comparison of CT and US assessment. *Radiology* 171: 439-443.
12. Widder S, Pasiaka JL (2004) Primary thyroid lymphomas. *Curr Treat Options Oncol* 5: 307-313.
13. Onal C, Li YX, Miller RC, Poortmans P, Constantinou N, et al. (2011) Treatment results and prognostic factors in primary thyroid lymphoma patients: a rare cancer network study. *Ann Oncol* 22: 156-164.