

## Primary Breast Lymphoma with Unconventional Presentation: A Case Report

Uzma Nisar, Maria Khan\*, Shahana Nisar and Shamrez Khan

Armed Forces Institute of Pathology, Rawalpindi, Pakistan

\*Corresponding author: Maria Khan, Armed Forces Institute of Pathology, Rawalpindi, Tel: 00923319111986; E-mail: kmaria22@hotmail.com

Received date: July 17, 2017; Accepted date: August 02, 2017; Published date: August 05, 2017

Copyright: © 2017 Nisar U, et al. This is an open-access article distributed under the terms of the Creative Commons Attribution License, which permits unrestricted use, distribution, and reproduction in any medium, provided the original author and source are credited.

### Abstract

Primary breast lymphoma (PBL) is a unique clinical finding accounting for 0.4–0.5% of all neoplasms in breast with a painless palpable mass being a most common presentation. On histopathological findings and radiological imaging, Diffuse large B-cell lymphoma (DLBCL) is the most widespread identifiable type of PBL. We report a case who presented with Primary breast lymphoma having multiple metastatic lesions in lymph nodes, muscles and bones.

**Keywords:** Primary breast lymphoma; Diffuse large B-cell lymphoma

### Introduction

Breast involvement is a very infrequent finding of extranodal lymphoma. Primary breast lymphomas (PBLs) correspond to 0.4–0.5% of all malignant tumors of the breast, 0.38–0.7% of all lymphomas, and 1.7–2.2% of all extranodal lymphomas [1,2]. The most frequent tumors of breast tissue are ductal and lobular carcinomas. Breast involvement by lymphoma is very rare event. It can suggest itself as a primary breast tumor or as an extranodal expression in systemic disease. Since extranodal manifestation is more familiar in non-Hodgkin's lymphoma (NHL) than Hodgkin's disease (HD), with NHLs covering the majority of PBLs [3,4]. Secondary BL (SBL) is more common. The rarity of BL can be attributed to the fact that the breast contains very little lymphoid tissue [5]. It has been revealed in various studies that high grade lymphomas is noticeable as diffuse breast enlargement, whereas low and intermediate grade tumors frequently have nodular patterns [6].

Wiseman and Liao described the diagnostic criteria for PBL, which remains the standard characterization for this entity. As no definite pathologic features distinguish breast from other extranodal sites of lymphoma, their description appears to be preeminent for evaluation and specifically targeting treatment of the tumor site [7]. The specific criteria for PBL diagnosis include:

1. The clinical location of presentation is the breast.
2. A previous history of lymphoma or indication of widespread disease are absent at diagnosis.
3. In pathologic specimen, lymphoma is recognized with close association to breast tissue.
4. Ipsilateral lymph nodes may be involved if they develop simultaneously with the primary breast tumor.

PBLs specifically affect women (in men only 10 cases have been reported so far). 8 The incidence of PBLs is growing; recently Aviles and coll reported a review of 96 patients, 4 whereas The International Extranodal Lymphoma Study Group (IELSG) has 204 cases registered [8,9].

Herein, we report a rare case of primary non-Hodgkin lymphoma of the breast metastasizing to multiple muscles and bones of the body, with B-cell phenotype, diagnosed by mammography and computed tomography and confirmed by histopathological examination.

### Clinical Report

A 25-years-old female presented with 3 months history of painful swelling of left hip and upper thigh. She also gave history of concomitant hard painless swelling in her right breast which had increased rapidly in size in the last seven months. She also complained of severe pain in right leg and iliac region. Her family history was negative for breast cancer. She was married, menstruating, and had 3 children. She gave history of weight loss but her history was negative for fever and night sweats. On physical examination the patient appeared conscious and oriented but was pale and cachexic. Her vitals revealed blood pressure of 110/75 mm Hg; pulse 70/min; temperature 98°F and respiratory rate 16/min.

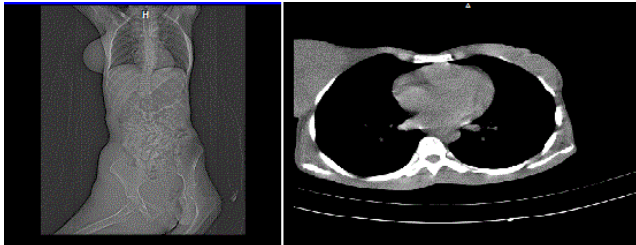
There was a large fungating mass in the right breast with nipple retraction and Peau'd' orange. On palpation the mass was hard and immobile. Left breast was normal. A huge mass was also noted in the right inguinal region, gluteal region, upper thigh and right iliac fossa.

Her laboratory investigations revealed, total leucocyte count of  $6.2 \times 10^9/L$ , haemoglobin of 7.8 gram/dl, differential leukocyte count (DLC) neutrophils 71%. Her C-reactive protein (CRP) was 32 IU/L and ESR 36mm at 1st hour. Lactate dehydrogenase (LDH) levels were raised 270U/ L. Fasting plasma glucose was 8.6 mmol/l and creatinine kinase 649 U/ L.

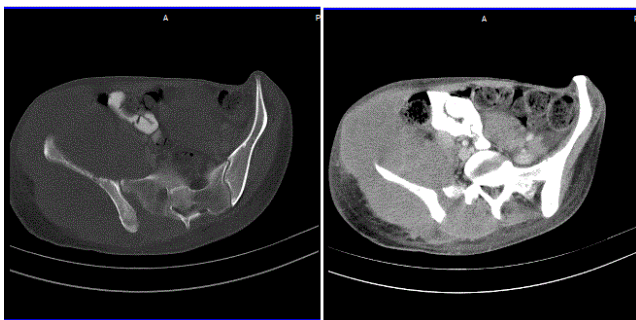
On radiological imaging, Sonomammography revealed large, nodular, solid, mixed echogenicity mass measuring about  $12 \times 10.5 \times 12.5$  cm (TxAPxCC) in the right breast, replacing the normal parenchyma. There was posterior acoustic shadowing and the underlying pectoral muscles were infiltrated by the mass. Color Doppler imaging showed low resistance blood flow. A few enlarged lymph nodes were noted in the ipsilateral axilla. Left breast appeared grossly normal. X-ray of pelvis and femur showed erosive lesions in the right side of sacrum and iliac bone.

Further, the mass was evaluated with Contrast enhanced computed tomography (CECT) chest and abdomen which revealed a large solid

right breast mass showing heterogenous enhancement with intravenous contrast (Figure 1). Large lobulated soft tissue solid mass was also seen completely surrounding the right iliac bone, infiltrating the right lower lateral abdominal wall muscles, the lower part of right Psoas muscle and extending down the right iliac fossa, right gluteal region and upper thigh (Figure 2).



**Figure 1 :** The mass was evaluated with Contrast enhanced computed tomography (CECT) chest and abdomen which revealed a large solid right breast mass showing heterogenous enhancement with intravenous contrast.



**Figure 2:** Large lobulated soft tissue solid mass was also seen completely surrounding the right iliac bone, infiltrating the right lower lateral abdominal wall muscles, the lower part of right Psoas muscle and extending down the right iliac fossa, right gluteal region and upper thigh.

There was penetration and erosion of the right iliac bone and partial destruction of right side of the sacrum. A bone scan showed evidence of increased uptake in the right iliac bone and sacrum. Multiple enlarged lymph nodes were also noted in the axillary and para-aortic region in the right iliac fossa, left iliac fossa. These findings were highly suggestive of breast carcinoma with soft tissue and bone involvement and metastatic paraortic and axillary lymphadenopathy.

Histopathological investigation (fine-needle aspiration (FNA) and core biopsy) were also performed. Fine-needle aspiration of the right axillary lymph node showed atypical lymphoid cells suggestive of malignancy. The histopathology findings confirmed the diagnosis with stage IVB Primary Diffuse Large B-cell Lymphoma (DLBCL); active B-cell type. The immunohistochemical studies illustrated positivity for tumor populations CD19, CD20, CD79a, bcl-2, bcl-6 and MUM-1 and CD10.

After the diagnosis of primary diffuse large B-cell non-Hodgkin lymphoma, chemotherapy was initiated using the R-CHOP regimen (rituximab, cyclophosphamide, adriamycin, vincristine and

prednisone). The masses in the breast and hip region somewhat regressed with chemotherapy but the patient died within four months of completion of treatment.

In summary, the patient had diffuse large B-cell lymphoma, stage IV B, having multiple enlarged lymph nodes and multiple extranodal localization (breast, muscle, and bone).

## Discussion

Primary breast lymphoma (PBL) remains an infrequent finding, so clinicians treating breast carcinomas should be aware of this entity in order to differentiate its clinical presentation, management, and prognosis from breast carcinoma cases [10]. With the improvement in novel diagnostic modalities and the increasing frequency of PBL, substantiates the significance of awareness and clinical information of this rare disease. It is predominantly (95%–100%) reported among female patients and is very rare finding in males [11]. Breast lymphomas represent 1.2% of all non-Hodgkin lymphomas, with frequency of primary and secondary cases being similar. Isolated breast lymphoma occurs in less than 1% of all patients with non-Hodgkin's lymphoma. Right breast lesions are major findings, and the most common morphologic type is diffuse large B-cell lymphoma, similar to our case with large right sided breast mass [12].

In previous series of 470 patients with NHLs, PBLs were diagnosed in 1.3% of patients, and 6 of 192 patients (3.1%) with extranodal presentation had the breast as the primary site, as evident in our case. Although secondary involvement of the breast during the course of lymphomas is not uncommon, the breast is rarely a primary site for lymphomas [13]. The incidence is high between 9 and 85 years, with the maximum frequency in the sixth decade [2]. In breast, malignant lymphoma is an unusual diagnosis. Lymphomas can manifest as a primary breast tumor, or it can involve the breast secondarily as part of a metastatic event. According to the literature, the true prevalence of breast lymphoma has complex determination process [14,15]. Although its etiology is unknown, its association with different processes, like estrogen and autoimmune diseases has been portrayed, none of these associations were so far found in our patient [16].

As previously noted, there are array of histologic subtypes of lymphoma that can exist in primary breast lymphomatous disease. The most common subtype of which is diffuse large cell non-Hodgkin's lymphoma. Primary breast lymphoma can also show evidence typical of MALT (mucosal associated lymphoid tissue) lymphoma. Burkitt-like lymphoma is typically thought to be associated with pregnancy [17]. The histopathological findings are based on, breast tumors being categorized as large cell B-cell lymphomas, monocytoid B-cell lymphomas (MBCL), and undifferentiated [18]. In the present case, FNA of the right axillary lymph node showed atypical lymphoid cells suggestive of malignancy. FNAC is ideal for the primary diagnosis of PBL as it assist in early detection and treatment. However, the differential diagnosis of PBL should be made according to the pathological findings, which is crucial for understanding the typing and staging of these tumors [19].

The most universal mammographic findings include a solitary well defined mass that may have an irregular border, which is consistent with the finding in the present case. PBLs are seldom calcified and do not have a spiculated appearance on mammography. Ultrasonography evaluation of PBL usually display a hypochoic lesion having well-defined borders that lack significant posterior enhancement or acoustic shadowing, which may sometimes falsely indicate a benign cyst and

occasionally a lobulated mass representing a huge tumor [20]. According to Paulus, the lymphomatous involvement of the breast has a noticeable predilection to form relatively circumscribed masses on a mammogram [21].

PBL can be classified based on the presenting symptoms as Type A having atypical symptoms and Type B having fever, night sweats and weight loss. 11 Patients with breast lymphoma clinical presentation are similar to that of patients with other mammary neoplasia. These findings include a palpable breast mass on self-examination or clinical breast examination. According to Domchek, more than 90% of patients with breast lymphoma presented with a palpable mass [22]. BL can present with variety of symptoms. These are non-specific symptoms and may mimic those of breast carcinoma. According to the literature, the most frequent presenting symptom was an enlarging, painless breast mass. Pain has been reported to occur in 4–25% of patients. Other local signs, such as nipple retraction or discharge and skin changes, can also be present [3]. However, in another study 24% of Breast lymphomas (BL) were clinically asymptomatic when identified accidentally on mammograms [23]

In agreement with previous reports, most patients presented with painless solitary or multiple breast lumps. Systemic symptoms occurred in only 8% of cases. Some authors regard bilateral involvement as a possible specific feature of BL in contrast to breast cancer [5]. In contrast to study by Liu and Clark, there were no instances of bilateralism [24]

The diagnostic evaluation for lymphoma is comparable to that for breast adenocarcinoma. Once an abnormal finding is confirmed by radiographic studies and clinical, histologic confirmation of lymphoma is definitely required. Nonetheless, the increased employment of screening mammography does not have proportionally increased the diagnosis of primary breast lymphoma nor has it facilitated earlier detection of breast lymphoma in patients [22].

The management strategies for PBL vary broadly, from surgical intervention to combination of radiotherapy and chemotherapy. However, updated standard guideline for PBL treatment lacks. In the past, management of primary breast lymphoma typically involved excision of the lesion. Wiseman and Liao reported poor prognosis of patients with primary breast lymphoma treated with surgery alone or those treated with radiation therapy only [7]. In the recent past, the gold standard for management of breast lymphomas was surgery [25]. Presently this perception has been challenged, and the role of surgery has lost most of its importance [26]. In several studies, mastectomy for PBL was not supported because it revealed neither improved survival nor reduced risk of recurrence. However, reports have recommended that surgery should be offered for diagnosis only and that minimally invasive surgery is the more appropriate option because extensive surgery may carry a high risk of morbidity. Also, axillary dissection adds no therapeutic advantage [27]. Patients with high grade lymphoma or intermediate grade lymphoma are typically treated with cytotoxic chemotherapy with or without the addition of external beam radiation therapy. Many of these patients will not ultimately require surgical ablation. Radiation therapy alone is inadequate in controlling the disease for primary breast lymphoma [28]. So far this is a novel case report from our region, as no studies have been published yet regarding breast lymphoma with metastasis to multiple bones and muscles of the body.

## Conclusion

This is an atypical case of (B-cell type) breast lymphoma in a woman with a painless mass in the right breast metastasizing to multiple bones and muscles of the body. Screening and diagnosis of PBL based on advanced radiological investigations are valuable for identification of this rare neoplasm. Moreover, early and accurate diagnosis of PBL is crucial for selecting the appropriate treatment strategies to avoid potentially injurious surgical interventions. This case report can help in awareness building among clinicians to make the way for early diagnosis, appropriate treatment and favorable outcomes of breast lymphoma.

## References

1. Misra A, Kapur BML, Rath GK (1991) Primary breast lymphoma. *J Surg Oncol* 47: 265-270.
2. Mattia AR, Ferry JA, Harris NL (1993) Breast lymphoma. A B-cell spectrum including the low grade B-cell lymphoma of mucosa associated lymphoid tissue. *Am J Surg Pathol*. 17: 574-587.
3. Sabate JM, Gomez A, Torruja S, Camins A, Roson N, et al.(2002) Lymphoma of the breast: clinical and radiological features with pathological correlation in 28 patients. *Breast J*. 8: 294-304.
4. Aviles A, Delgado S, Nambo MJ, Neri N, Murillo E, et al. (2005) Primary breast lymphoma: results of a controlled clinical trial *Oncology* 69: 256-260.
5. Brogi E, Harris NL (1999) Lymphomas of the breast: pathology and clinical behaviour. *Semin Oncol*. 26: 357-364
6. Surov A, Holzhausen HJ, Wienke A (2012) Primary and secondary breast lymphoma: prevalence, clinical signs and radiological features. *Br J Radiol*. 85: e195-e205
7. Wiseman C, Liao KT (1972) Primary lymphoma of the breast. *Cancer*. 29: 1705-1712.
8. Murata T, Kuroda H, Nakahama T, Goshima H, Shiraishi T, et al. (1996) Primary non-Hodgkin malignant lymphoma of the male breast. *Jpn J Clin Oncol*. 26: 243-247
9. Ryan G, Mantelli G, Kuper-Hommer M, Tsang R, Pruneri G, et al. (2008) Primary diffuse large B-cell lymphoma of the breast. Prognostic factors and outcome of a study by the International Extranodal Lymphoma Study Group. *Ann Oncol*.19: 233-241.
10. Zhao YF, Jiao F, Liang HQ (2014) Primary malignant non-Hodgkin's lymphoma of the breast: A case report. *Oncol Lett*. 8: 2597-600.
11. Yang H, Lang RG, Fu L (2011) Primary breast lymphoma (PBL): A literature review. *Clin Oncol Cancer Res* 8:128-132.
12. Topalovski M, Cristan D, Mattson JC (1999) Lymphoma of the breast: a clinicopathologic study of primary and secondary cases. *Arch Pathol Lab Med* 123:1208-1218.
13. Barista I, Tekuzman G, Firat D (1994) Non-Hodgkin's lymphomas in Turkey: eighteen years' experience at the Hacettepe University. *Jpn J Cancer Res*. 85: 1200-1207.
14. Lee WK, Duddalwar VA, Rouse HC, Lau EW, Bekhit E, et al. (2009) Extranodal lymphoma in the thorax: crosssectional imaging findings. *Clin Radiol*. 64:542-549.
15. DeCosse JJ, Berg JW, Fracchia AA, Farrow JH (1962) Primary lymphosarcoma of the breast. A review of 14 cases. *Cancer* 15:1264-1268.
16. Cheah CY, Campbell BA, Seymour JF(2014) Primary breast lymphoma. *Cancer Treat Rev*. 40: 900-908.
17. Jones DE, Avignon MB, Lawrence R, Latshaw RF (1980) Burkitt's lymphoma: obstetric and gynecologic aspects. *Obstet Gynecol*. 56: 533-536.
18. Hugh JC, Jackson FI, Hanson J, Poppema S (1990) Primary breast lymphoma. An immunohistologic study of 20 new cases. *Cancer*. 66: 2602-2611.

19. Schwartz IS, Stranchen JA (1990) Lymphocytic mastopathy: An autoimmune disease of the Breast? *Am J Clin Pathol.* 93: 725-730.
20. Suzuki Y, Tokuda Y, Okumura A, Saito Y, Ohta M, et al. (1990) Three cases of malignant lymphoma of the breast. *Japanese Journal of Clinical Oncology.* 30:33-36.
21. Paulus DD (1990) Lymphoma of breast. *Radiol Clin North Am* . 28: 833-840
22. Domchek SM, Hecht JL, Fleming MD, Pinkus GS, Canellos GP, et al. (2002) Lymphomas of the breast: primary and secondary involvement. *Cancer.* 94: 6-13.
23. Ganjoo K, Advani R, Mariappan MR, McMillanA, Horning S, et al. (2007) Non-Hodgkin lymphoma of the breast. *Cancer.* 110: 25-30.
24. Balu-Maestro C, Bruneton JN, Rogopoulos A, Marcy PY, Guidicelli T, et al. (1992) Mammographic and ultrasonographic appearances of lymphoma of the breast. *Eur Radiol.* 2: 565-569.
25. Farinha P, Andre S, Cabecadas J, Soares J (2002) High frequency of MALT lymphoma in a series of 14 cases of primary breast lymphoma. *Appl Immunohistochem Mol Morphol.* 10:115-120.
26. Tanaka T, Hsueh CL, Hayashi K, Awai M, Nishihara K, et al. (1984) Primary malignant lymphoma of the breast: with a review of 3 cases among Japanese subjects. *Acta Pathol Jpn.* 34: 361-373.
27. Jennings WC, Baker RS, Murray SS (2007) Primary breast lymphoma: the role of mastectomy and the importance of lymph node status. *Ann Surg* . 245: 784-789.
28. Babovic N, Jelic S, Jovanovic V (2000) Primary non-Hodgkin lymphoma of the breast. Is it possible to avoid mastectomy. *J Exp Clin Cancer Res.* 19:149-154.