

Prevention of Ureter Fistula and Other Side Effects of Radical Hysterectomy of Uterine Cervical Cancer

Kazuo Maeda*

Department of Obstetrics and Gynecology, Tottori University School of Medicine, Yonago, Japan

*Corresponding author: Kazuo Maeda, Honorary Professor, Department of Obstetrics and Gynecology, Tottori University School of Medicine, Yonago, Japan, Tel: 81-859-22-6858; E-mail: maedak@mocha.ocn.ne.jp

Received date: Aug 01, 2016; Accepted date: Aug 26, 2016; Published date: Sep 02, 2016

Copyright: © 2016 Maeda K. This is an open-access article distributed under the terms of the Creative Commons Attribution License, which permits unrestricted use, distribution, and reproduction in any medium, provided the original author and source are credited.

Abstract

Purpose: To prevent hazardous effects of radical hysterectomy of uterine cervical cancer.

Methods and results: The operation technique was modified Wertheim's radical hysterectomy, improved in Japan and by the author. The side effects of the operation were 1) Continuous vaginal urinary incontinence caused by ureter fistula, which was produced by pelvic infection of wound secretion after surgery, and it was prevented by the aseptic aspiration drainage of pelvic secretion, where the secretion was aseptically removed and ureter wall damage, urinary fistula and incontinence were prevented. 2) Pelvic lymph cyst was prevented by the ligation of open inguinal lymph duct, which was left open after the resection of pelvic lymph-nodes. The pelvic inflammatory cyst disappeared after lymph-duct ligation in the lymph node resection. 3) Difficult urination due to bladder palsy was reduced preserving pelvic nerves in the cardinal ligament, but limitedly in cases of no cancer infiltration in the ligament.

Conclusion: Side effects caused by the radical hysterectomy were prevented when their developmental process was clarified and suitable cares were applied.

Keywords: Uterine cervical cancer; Radical hysterectomy; Side effect; Ureter fistula; Lymph cyst; Bladder dysfunction

Methods

The prevention of ureter fistula

The separation of ureter from neighbor tissue was as narrow as possible, and its nourishing blood vessel was preserved in radical hysterectomy, avoiding the ureter immersion into infected wound secretion.

The removal of wound secretion was a problem, because vaginal or pudendal drainage resulted bacterial infection and pelvic abscess, promoting the ureter necrosis and fistula. Therefore the author planned aseptic drainage through two sterile silicon tubes of which open tips were deeply inserted into both side pelvic wound cavities, then outside tips were connected to the Cortina aspiration bottle used in common surgery (Figures 1 and 2), where the technique achieved aseptically closed aspiration drainage to drain the wound secretion preventing bacterial infection. The wound secretion of bloody fluid was aspirated for 300-400 ml in 3-4 postoperative days, then the aspiration stopped and tubes were removed. There was no bacterial infection without pelvic inflammation, at the same time the ureter fistula was completely prevented and no pelvic inflammation was experienced in Tottori University hospital eternally, while its development was to be 2% of common radical hysterectomy of infectious drainage.

Introduction

Although radical hysterectomy of cervical cancer was performed under laparotomy in the past, the prevention of its side effects will be still useful. As the radical hysterectomy was performed to remove possible dissemination of cancer cell in the pelvic tissue and lymph nodes with the resection of uterus and adnexa, large uncovered tissue wound was exposed after surgery, and massive wound secretion was accumulated in the pelvic floor, developing pyrogenic inflammation affecting isolated ureter, of which tissue tends to develop necrotic fistula and continuous urinary incontinence into postoperative vagina, heavily disturbing patient, where some cases received single nephrectomy of fistula side to stop the incontinence. The ureter fistula was an important problem in radical hysterectomy, and various drainages were tried, but no fistula was prevented due to bacterial infection of wound fluid, and it was formed in 2 % in radical hysterectomy.

Lymph cyst was formed in the pelvis after radical operation, where bacterial infection was frequent. No postoperative lymph cyst would be favorable in cervical cancer operation.

The urinary dysfunction due to bladder palsy caused by the cutting of pelvic nerve in the cardinal ligament in radical hysterectomy.

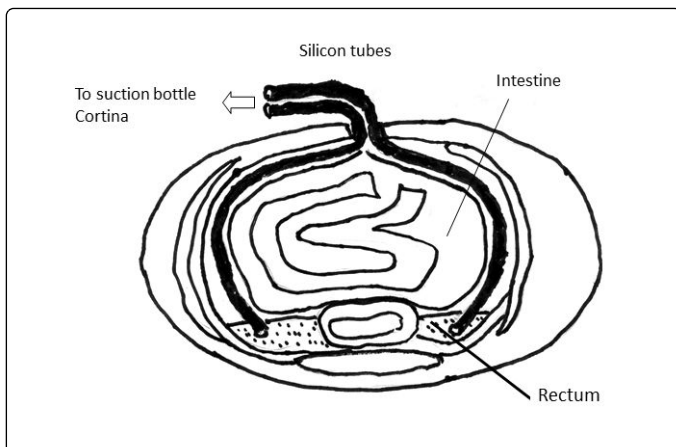


Figure 1: Sterile silicon tubes' open tips are inserted into the wound secretion accumulated at para rectal spaces of pelvic floor, and connected to Cortina aspiration bottle to aseptically remove the wound secretion after radical hysterectomy.

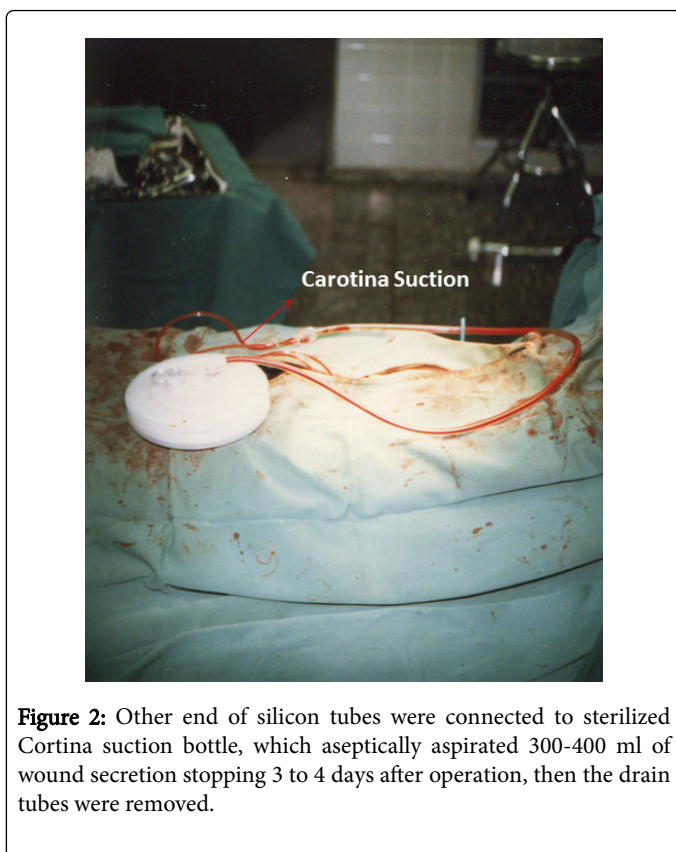


Figure 2: Other end of silicon tubes were connected to sterilized Cortina suction bottle, which aseptically aspirated 300-400 ml of wound secretion stopping 3 to 4 days after operation, then the drain tubes were removed.

The prevention of lymph cyst

Since the postoperative lymph cyst and its inflammation was produced by the accumulation of leaked lymphatic fluid after lymph node resection, the open end of lymph duct was ligated above the inguinal region in the resection of external iliac lymph node, in addition upper open end of lymph duct was ligated, by the author. No lymph cyst was formed after the ligation, and lymph cyst inflammation was totally prevented.

The prevention of urination dysfunction

The pelvic nerves located in the cardinal ligament was separated from the connected tissue of the ligament and preserved in case of no cancer infiltration to the ligament. Urinary bladder muscle palsy would be prevented and difficult urination would be reduced.

Discussion and Conclusion

Successful result of cervical cancer treatment will be shown by 5 years survival rate after the operation. It was 85% in Tottori university hospital in stage II cases after the introduction of preventive procedure in the radical operation. The 85% of 5 years survival rate was average success in stage II in Japan, namely, the curability of cervical cancer was not damaged by the management to reduce side effect of radical hysterectomy.

The procedure of our radical hysterectomy was reported to a Journal with stereoscopic photos [1]. Although it was an advanced surgery for cervical cancer, its application is limited in the stage 0 to early III stage. More wide therapeutic regimen will be anti-cancer pharmaceutical therapy, which may achieve complete remission in the future, which means complete disappearance with anti-cancer agents, not only metastases and infiltration, but also the primary focus in the uterus. Is it dream to experience complete disappearance of uterine cervical cancer by drinking anti-cancer agent.

Therefore, it is desired to achieve complete remission by systemic anti-cancer agents of great progress in common cancer including cervical cancer.

References

1. Maeda K (2004) Private history of safe radical hysterectomy. *Japan Obstetric and Gynecologic therapy*. 89: 594-601.

This article was originally published in a special issue, entitled: "**Recent Research & Review on HPV & Cervical Cancer**", Edited by S4