

## Preparation of Amniotic Membrane and It's Application in the Treatment of Skin Loss and Lyell's Syndrome (Toxic Epidermal Necrolysis): Current State and New Opportunities

Agnieszka Klama-Baryla<sup>1,2</sup>, Wojciech Łabuś<sup>1\*</sup>, Diana Kitala<sup>1,3</sup>, Małgorzata Kraut<sup>1</sup>, and Marek Kawecki<sup>1,3</sup>

<sup>1</sup>Centre for Burns Treatment in Siemianowice Śląskie, Poland

<sup>2</sup>Silesian Higher Medical School in Katowice, Poland

<sup>3</sup>University of Bielsko-Biała, Poland

\*Corresponding author: Wojciech Labus, Centre for Burns Treatment in Siemianowice Slaskie, Siemianowice Slaskie, Poland, Tel: +48 696 082 038; E-mail: wojciech.labus@gmail.com

Received date: August 28, 2017; Accepted date: September 08, 2017; Published date: September 14, 2017

Copyright: © 2017 Klama-Baryla A, et al. This is an open-access article distributed under the terms of the Creative Commons Attribution License, which permits unrestricted use, distribution, and reproduction in any medium, provided the original author and source are credited.

### Abstract

Amniotic membrane is a good protection against bacterial infections, reduces losses of proteins, fluids and electrolytes, decreases pain from burns and accelerates healing. Due to its richness in nutrients and low immunogenicity, it is often used as a skin substitute. Human amnion may be prepared in tissue banks, as biostatic or biovital grafts. There are various methods of amniotic graft preparations developed to make them efficient in surgical treatment and prevent the risk of transmission of infectious diseases. This paper presents the current clinical application of human amnion in the treatment of skin losses, such as burns to the face and Lyell's syndrome (toxic epidermal necrolysis). It also describes new applications of fetal membranes for other diseases. Placental grafts are often an alternative therapy in the situations when standard treatment does not yield desirable effects. Such grafts are especially beneficial in comparison to many other bioactive therapies, including low cost, easy manipulation, capability of promoting cell migration and proliferation and stimulation of stem cell activity.

**Keywords:** Amniotic membrane; Placenta; Amniotic mesenchymal stem cells; Amniotic fluid; Placental grafts; Toxic epidermal necrolysis; Burns of the face

**Abbreviations:** KTN: Keratocan; TGF-  $\beta$ : Transforming Growth Factor Beta; FGF: Fibroblast Growth Factor; HGF: Hepatocyte Growth Factor; PEDF: Pigment Epithelium-Derived Factor; SJS: Stevens-Johnson Syndrome; TEN: Toxic Epidermal Necrolysis; IL-6: Interleukin 6; IL-8: Interleukin 8; GRO: Growth-Related Oncogene; MCP-1: Monocyte Chemoattractant Protein 1; ICAM: Intravascular Adhesion Molecule; HAM: Human Amniotic Membrane; DMSO: Dimethyl Sulfoxide; EDTA: Ethylene Diamine Tetraacetic Acid; ECM: ExtraCellular Matrix; DFUs: Diabetic Foot Ulcers; TCC: Total Contact Cast; CM: Collagen Membrane; BBM: Deproteinized Bovine Bone Mineral; dHACA: Dehydrated Human Amnion and Chorion Allograft

### Introduction

The amniotic membrane is a thin, semipermeable tissue which constitutes the inner layer of the gestational sac. Placental grafts for clinical purposes are prepared from the placenta of carefully selected and examined donors. The placentas are obtained by gynecologists during cesarean section or natural labor from patients who have given their informed consent [1,2]. Human amnion may be prepared in tissue banks, as biostatic or biovital grafts, it is collected from women qualified as eligible on the basis of negative results of serological tests, and medical interviews. Thanks to the characteristics of the amniotic membrane, such as lack of expression of histocompatibility antigens, it is possible to transplant the membrane without using immunosuppressive drugs and without the risk of graft rejection. Also, its antibacterial properties are an argument in favor of its wide clinical

use, as the risk of postsurgical complications is much lower. Another important feature of the amniotic membrane is its antiadhesive effect. Thanks to these properties, it constitutes a treatment method for serious skin losses alternative to standard therapies using autologous grafts. Currently, treatment of skin losses with amniotic grafts is a standard therapeutic procedure in surgical departments specializing in the treatment of skin wounds, such as burns and ulcers. The amnion is also used in reconstruction procedures (e.g. vaginoplasty) and other surgical procedures in the area of the head, neck, abdomen and pelvis [1,2].

The amnion has also anti-inflammatory properties related to the presence of anti-inflammatory mediators and the ability to induce apoptosis of mononuclear cells, including lymphocytes and macrophages. Furthermore, the amnion reduces the expression of major histocompatibility complex (MHC) class II. Its anti-inflammatory effect indirectly prevents scar formation. The studies on the use of the amniotic membrane in ophthalmology proved that it can prevent scarring by means of inhibition of TGF-  $\beta$  signalling during transcription. The amniotic stromal matrix has the ability to maintain the expression of Keratocan (KTN) in human keratinocyte cultures. Therefore, the effect on TGF- $\beta$  signalling is important not only for the inhibition of scar formation but also for the maintenance of proper phenotype of keratinocytes. The amniotic membrane contains pigment epithelium-derived factor (PEDF), which is a strong antiangiogenic factor. Moreover, the amniotic membrane exhibits an analgesic effect, which has been observed in the treatment of chemical burns, severe bacterial keratitis, Stevens-Johnson syndrome (SJS), toxic epidermal necrolysis (TEN) and the acute phase of painful corneal vesicles [1-3].

The amniotic membrane is a good protection against bacterial infections, reduces losses of proteins, fluids and electrolytes, decreases

pain in burned places and accelerates healing [4]. Thanks to mesenchymal cells and factors they secrete: interleukin 6 (IL-6), interleukin 8 (IL-8), growth-related oncogene (GRO), monocyte chemoattractant protein-1 (MCP-1) and intravascular adhesion molecule (ICAM), the amnion stimulates the growth of the patient's stem cell population and modulates the response of these cells in the tissues of the healing wound [5]. The inhibition of neutrophils by the amniotic cells leads to reduction of the inflammation and slower collagen decomposition, which results in quicker wound healing [6]. The multilayer amniotic membrane consisting of epithelial cells, fibroblasts and a basement membrane [7], works as an extracellular matrix (ECM). The amniotic basement membrane is rich in hyaluronic acid, collagen type I, III, IV, V and VI, laminin, elastin, fibronectin, proteoglycans [7]. Many of the properties described above are maintained also by the amniotic membrane after the cells are removed (deculturized membrane). Many studies show that antibacterial properties are also maintained by the deculturized amnion [8]. It was also proved that it facilitates healing of infected wounds [9], which may be a solution for wounds colonized by multidrug-resistant strains. Deculturized amniotic membrane is also proved to inhibit the growth of *E. coli* (ATCC 25922), *S. aureus* (ATCC 25923) and *P. aeruginosa* (ATCC 27853) [7]. These properties make it adequate for antibacterial applications, also as grafts soaked with antibiotics or antiseptics [10].

Another significant property of the amnion is the stimulation of epithelialization, possible thanks to the secretion of such factors as fibroblast growth factor (FGF), hepatocyte growth factor (HGF) and transforming growth factor beta (TGF- $\beta$ ) by the amniotic cells [11].

It has also been proved that amniotic stem cells are capable of transdifferentiation into cells of various organs, such as cardiomyocytes, osteoblasts, fibroblasts and cells similar to hepatocytes. Another important trait of these cells is their immunomodulatory properties. They can suppress immune response through inhibition of T cells, B cells, NK cells and dendritic cells [12-14].

As amniotic tissues are rich in nutrients, non-immunogenic and stimulating wound healing, there are very often used as skin substitutes [15].

Due to its unique characteristics, deculturized amniotic membrane is used as a skin substitute, and also as scaffolding for cell cultures [16]. It has been proved that single layers of human amniotic membrane (HAM) may be used for the creation of complex 3D scaffoldings with cells [17]. It is known that the amnion stimulates cell proliferation and maturation [7]; this applies also to skin cells (keratinocytes and fibroblasts) [18]. Therefore, the amniotic membrane is often used as a matrix for cell cultures or scaffold for their transfer [19]. The procedure of obtaining deculturized amnion is simple and cheap, and consists in incubation in 1% trypsin-EDTA solution at 37°C for 30 minutes, which results in total removal of epithelial and mesenchymal cells [15].

The aforementioned properties of the amniotic membrane contributed to the fact that the use of fetal membranes as skin grafts was reported as early as in 1910. Davis used the fetal membrane in the treatment of thermal burns [20], while three years later Sabella applied


it in the therapy of skin burns and ulcers. Even these first attempts of clinical use showed no infections, pain alleviation and acceleration of the reepithelialization process of the damaged skin surfaces [21]. In 1940, researchers reported promising results of using amniotic grafts in eyeball surface treatment [22]. Since then, amniotic membrane has begun to be commonly used in wound healing, as a support for the treatment of burns and chronic wounds [23].

Despite the promising results showing that the amnion accelerated healing and regeneration, in the following years the use of amniotic membranes was reduced and grafting did not become a widely used practice. Placental tissues were treated as an untrustworthy source of tissue, entailing the risk of transmission of infectious diseases, such as human immunodeficiency virus (HIV). It was also difficult to prepare the grafts, as well as to store and transport them [23]. Along with the improvement of processing techniques and the implementation of quality control systems which minimized the risk of infectious disease transmission, amniotic membranes started to be used again in ophthalmology in 1990. Their use grew quickly and at the end of the 20th century, they became the most popular types of graft in ophthalmology [22]. After the successes in the clinical use of the amnion in ophthalmology, grafts were adapted to be used for skin losses.

### Amniotic graft preparation methods

The improvement of placental tissues preparation techniques resulted in more frequent use of amniotic grafts for wound treatment, not limited only to the applications in ophthalmology. There are various methods of amniotic graft preparation developed to make the grafts efficient in surgical treatment and prevent the risk of transmission of infectious diseases. Amnion donors may agree to donate their placentas from their live-born children when it does not endanger the health of the mother or the child. The placentas are usually collected during C-sections as this method enables tissue collection in aseptic conditions, without passing through the birth canal. All donors must be free from infectious diseases, including HIV, hepatitis B and C, and syphilis, in accordance with the law in force.

Tissue allografts may be processed using various techniques. For example, many allografts (collected from tissue donors) and xenografts (obtained from animal tissues) are completely deculturized in order to remove the immunogenic cell components and prevent graft rejection. Deculturization leads to the removal of immunoreactive cellular components and protein factors, but leaves the biologically indifferent skeleton built of extracellular matrix structurally intact. Deculturization is proposed as a preventive method against rejection of heterografts or allografts (e.g. of human dermis). However, placental grafts come from placental tissues which are immunologically indifferent. Placental tissues contain small amounts of HLA antigens and do not induce immune responses. Therefore, it is enough to gently clean placental tissues to remove blood and other tissue remnants while maintaining the natural bioactivity of the graft - total deculturization is not required. The most frequent method of tissue graft preservation against degradation is cryopreservation, i.e. freezing in very low temperatures.



**Figure 1:** Chosen stages of production of allogeneous biostatic human amniotic grafts: a) amniotic membrane in a transport container; b) rinsing; c) clipping an uneven fragment and measuring graft surface; d) packing before radiation sterilization.

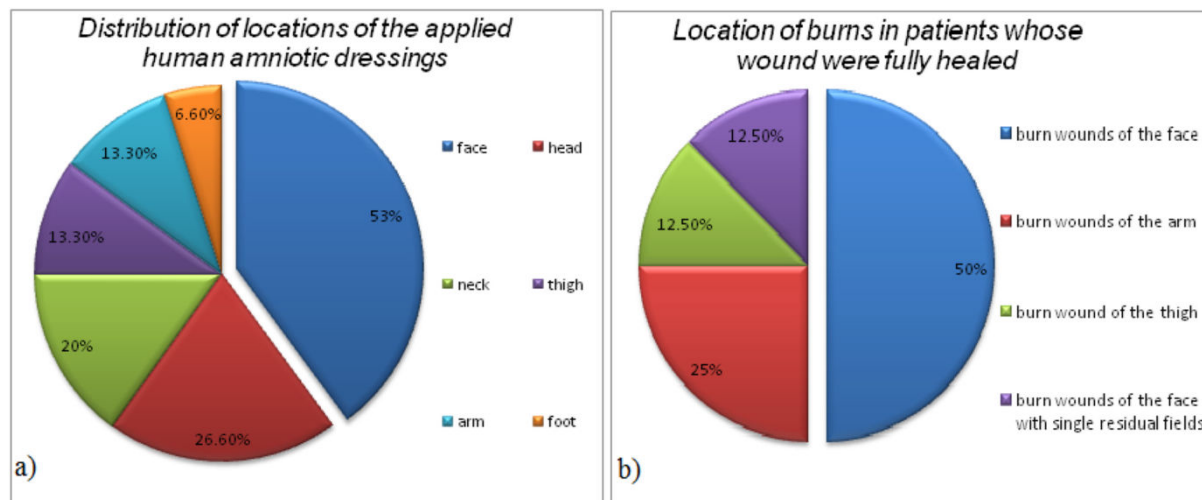
Cryopreservation may prevent tissue degradation by reducing the enzymatic and chemical activity, and inhibiting microbial growth. However, cryopreserved grafts require specialist storage and transport methods, and supervision of the temperature using liquid nitrogen, dry ice or low-temperature freezers, often at  $-80^{\circ}\text{C}$  or  $-150^{\circ}\text{C}$ . Cryopreservation requires the use of cryoprotectants, such as dimethyl sulfoxide (DMSO) and glycerin to reduce the effect of ice formation in the cells. Ice inside the cells can destroy their membranes and damage the extracellular matrix. However, the use of cryoprotectants can be cytotoxic in high concentrations, or if the exposure time is longer. Therefore, careful rinsing of the tissues is required before applying the graft. Tissue dehydration is an increasingly more popular alternative to cryopreservation. It can be obtained through lyophilization or freeze-drying. Dehydrated tissues are protected without the need of freezing in dry ice or liquid nitrogen. However, the procedure may change tissue microstructure and extracellular matrix (Figure 1).

Amniotic grafts can also be sterilized to reduce the risk of donor-related infectious diseases. Although the grafts are prepared in aseptic conditions in order to reduce the risk of a bacterial or viral infection, they can be sterilized using e.g. gamma rays or electron-beam sterilization, to reduce the transmission risk even further. Even though high radiation levels may potentially lead to cross-linking or cause protein denaturation in the irradiated tissue, sterilized amniotic membrane maintains its biological activity both clinically and *in vitro* studies [4,24]. This data shows that sterilization has no significant effect on the biological activity of amniotic grafts, while it ensures maximum patient safety [4,24].

Each amniotic graft preparation technique has its advantages and disadvantages. However, its main goal is such tissue processing that will maximally remove materials that are dangerous from the perspective of safe grafting to the patient, but at the same time maintain the natural properties and biological activity of the grafts in order to ensure maximum efficiency and support in wound healing. The growth in demand for amniotic membrane is to a great extent a result of its usefulness in the treatment of many disorders, not only wounds. The amnion has found applications in orthopedics, neurosurgery, gynecological surgery, periodontology, general and reconstruction surgery and many other medical disciplines [23].

Currently, the treatment of burns up to degree IIB and Lyell's syndrome (toxic epidermal necrolysis) involves applying dressings prepared from allogeneous amnion collected and prepared in accordance with binding standards and developed procedures. The placenta collection procedure is carried out in accordance with the rules of the aseptic technique. The placentas are rinsed in saline solution and placed in a labeled transport container filled with transport liquid. The liquid is a mixture of saline solution and antibiotics. The selection of the antibiotics is made on the basis of the current microbiological situation of the hospital. The transport container with the tissue material is described in a manner which excludes the possibility of an error (name, surname and ID no. of the donor, collection date) and then stored in a special refrigerator at  $+4^{\circ}\text{C}$  until it is transported to the tissue bank. After conducting all necessary tests, the amnion is transported to the preparation room where it will be prepared in sterile conditions in a laboratory intended for tissue processing in a laminar flow cabinet. The amnion undergoes five cycles of rinsing in saline solution using a vortex mixer at the temperature of  $+4^{\circ}\text{C}$ . Each rinsing lasts five minutes. Then, the amnion is placed under the laminar flow cabinet and manually separated from the chorionic layer. The amnion is then rinsed in saline solution at  $+4^{\circ}\text{C}$ . The rinsing is repeated on a clean dish. Later, the amnion is spread on a glass plate and the excess of blood and mucus is removed using sterile swabs. The following stage involves cutting uneven fragments off with a scalpel, and measuring the graft surface area. The prepared material is packed to a sterile bag that is closed using a vacuum sealer. The sac with the graft is placed in another bag, on which an ISBT 128 label is placed. The label contains the graft description, donation number, graft surface area and data of the tissue bank where it has been prepared. It includes also a sterilization indicator. The grafts labeled this way are packed in triple bags and stored at the temperature of  $-80^{\circ}\text{C}$  until they are transported for radiation sterilization. They are transported at the temperature of  $-70^{\circ}\text{C}$  ensured by dry ice filling the transport container.

After sterilization, microbiological tests are performed in order to release the prepared biostatic amniotic grafts for clinical use. If the microbiological tests results are negative and after the medical documentation of the donor has been verified, the grafts may be clinically used.



**Figure 2:** a) Amniotic dressing were used on: the face (53%), head (26.6%), neck (20%), thigh (13,3%), arm (13,3%) and foot (6,6 %); b) Completely healed burn wounds were obtained on the face (50%), arm (25%) and thigh (12.5%). Healing with single residual fields was obtained in 12.5% of patients, the wounds were located on the face.

### Use of amnion in the treatment of shallow skin losses and in Lyell's Syndrome (Toxic Epidermal Necrolysis) – own experiences

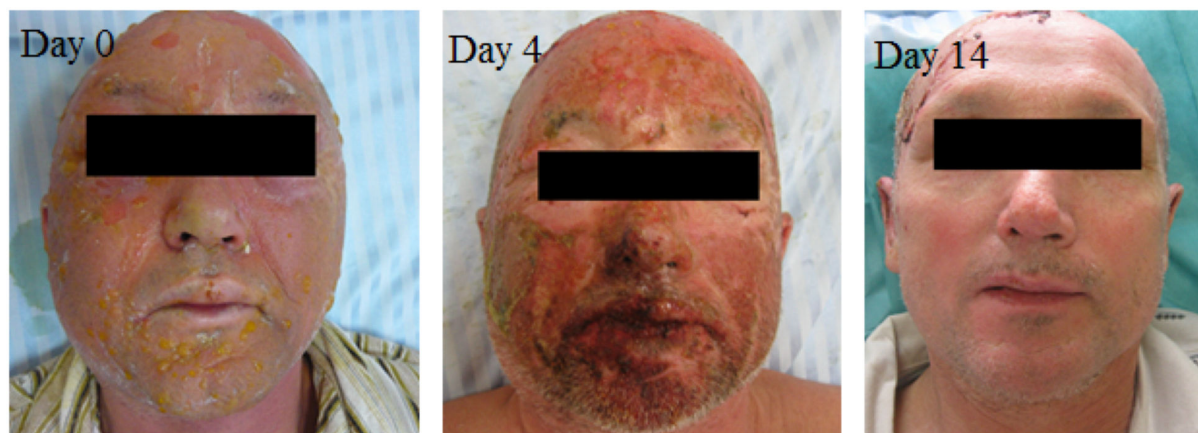In patients with shallow skin losses caused by burns (thermal, chemical), mechanical injuries or toxic epidermal necrolysis, amniotic grafting is the basic surgical treatment method. The transplantation is performed in first days after admission, as soon as the general condition of the patient is good enough to carry out the procedure. The procedure is performed in the operating theatre, using full aseptic techniques. First, the wounds are cleaned with an aseptic agent, and then the amniotic dressing (delivered from the tissue bank) is applied.

The amnion is covered with a sterile protective dressing with 1% neomycin ointment. The amnion has very good adhesion to wounds, therefore no sutures are required. After the grafting, the patients are still hospitalized in order to ensure continuous observation of the healing progress. The patients are examined during daily visits of the physician, who evaluates the wound healing under the amniotic dressing. The assessment includes healing progress and final healing of the burned places. If symptoms of a wound infection appear, a wound swab is collected in order to administer adequate antibiotics. Before and after surgery, the patients receive antithrombotic prophylaxis (low molecular weight heparin), analgesics (tramadol) and antibiotics in accordance with binding treatment standards. If there is no progress in wound healing, the patients undergo additional hyperbaric oxygen

therapy, which supports the treatment. In the post-hospitalization period, the patients were recommended to use replenishing agents for 2 months. The preliminary results of clinical effects of the human amnion showed various application locations of the grafts. In a hospital dedicated to treatment of adults, the amnion was used as a dressing for wounds of epidermis and dermis, degrees IIA and IIB in the burn classification scale. The chart below presents the percentage distribution of locations of the wounds treated with amniotic dressings.

In many cases, IIA degree burns do not require grafts and may be treated at home. However, regardless of the extensiveness of a II degree burn, if the burn covers the face, genital organs, hands or feet, it should be treated in hospital conditions. The application of the amnion is indicated especially in the case of burns of the face, where the esthetic effect of the treatment is very important. Such treatment leads to complete healing in as many as 80% of the patients; wounds healed with single residual fields were observed in only 6% of the patients. In 13% of patients treated with amniotic grafts, lack of healing caused multidrug-resistance strains infection was observed.

In the time period August 2011 to March 2017, the tissue bank prepared 252,592 cm<sup>2</sup> of biostatic human amniotic grafts for a monospecialist hospital treating burns in adults. 246 783 cm<sup>2</sup> of amniotic grafts were used in 528 patients, including 10 patients with Lyell's syndrome - toxic epidermal necrolysis (Figure 2).



**Figure 3:** Clinical effects of using amniotic drafts on burns on the face on day 0, 4 and 14.

Full healing of wounds after the application of the amnion takes place especially in the case of burns on the face. Significant graft manipulation capabilities also contribute to the wide use of amniotic grafts in burns of the face [25]. The figure below presents the effect of face wound healing under human amniotic grafts (Figure 3).

Toxic epidermal necrolysis (TEN) known also as Lyell's Syndrome is a rare, though life-threatening, mucocutaneous disorder with an epidermal detachment of a total body surface area (TBSA) of >30%. [26]. It often appears as a serious adverse reaction to medication, and less frequently as a complication of skin infections. The dermatological diagnosis is based mainly on the clinical symptoms, together with a histological analysis of a biopsy specimen showing a typical necrolysis across the whole thickness of the epithelium caused by extensive apoptosis of keratinocytes. Due to high risk of death, the treatment requires a quick diagnosis, identification, and discontinuation of the causative factor, and specialist supportive care [25]. The prompt withdrawal of the suspected drug, fluid and electrolyte replacement and topical wound care are the first line of therapy [27]. TEN has a very serious, often life-threatening course. Its average mortality rate ranges from 25% to 35%. Mortality can be even higher in elder patients and patients in whom the area of skin necrolysis is large [25]. Although systemic interventions may change the clinical course of this disease, local supportive therapy increases the survival rate and accelerates wound healing (Figure 4) [28].

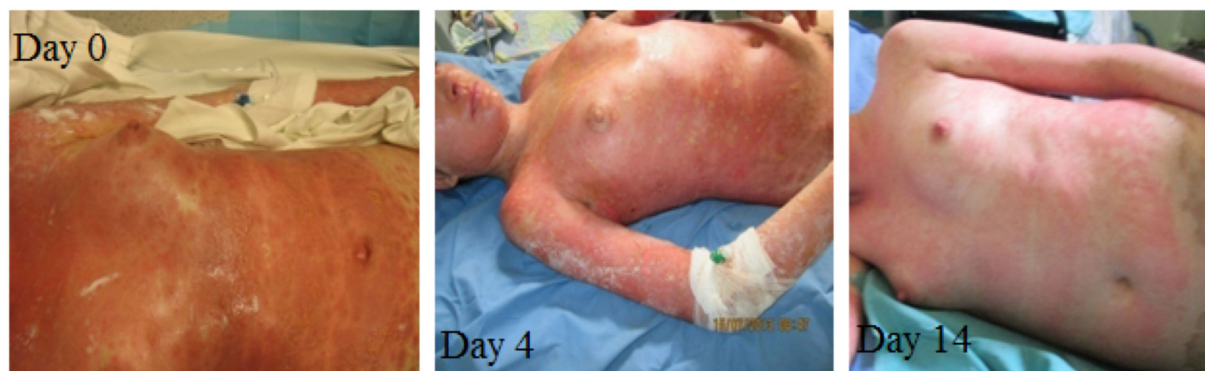The wounds are treated while most skin blisters are maintained because they act as natural dressings and probably facilitate reepithelialization. The wounds are cleaned very gently, and then amniotic grafts are applied. An extraordinary clinical usefulness of the amniotic membrane has been observed in the case of the treatment of Lyell's syndrome.

### New possibilities of application of grafts prepared from placental tissues

Current clinical uses proved the amazing efficiency of grafts prepared from placental tissues, mainly the amniotic membrane. A single-layer amnion is used for healing eye surfaces because

ophthalmology requires thin graft layers. Currently, the amniotic membrane is being used in increasingly more applications. Amniotic grafts have been found effective in the treatment of diabetic foot ulcers [DFUs]. In the study, amniotic grafts were combined with Total Contact Cast (TCC) dressings. TCC is a well-adjusted, partial immobilization of the foot with a light plaster dressing. It enables putting weight on the wounded foot without greater restrictions. It is made using quickly hardening synthetic fibers, which enable even distribution of pressure both on undamaged skin and directly on the wound and its surroundings. The wound must be earlier properly cleaned and secured. The use of the amnion and TCC led to the closure of the DFU-related wound in all patients studied, including the patients with complicated diabetic foot ulcers lasting for more than one year, in which standard treatment did not bring positive effects [29]. The extracellular substance of the amnion was proved to be useful in the regeneration of peripheral nerves. Moreover, it was found that the amniotic membrane is a biodegradable scaffold with unique biochemical and mechanical properties conducive to nerve regeneration [30]. It has also been presented that decellularized amnion may be used as a nourishing layer for a part of stem cells necessary for neuronal differentiation [31]. It can also serve as a scaffold for chondrocytes and be used for cartilage regeneration [32].

In gynecology, amniotic membranes may be used as a supportive therapy for Asherman's syndrome. The disease involves the formation of adhesions and fibrosis in the endometrium. The fibrosis is treated via hysteroscopy, but additional use of amniotic membranes improves regeneration of the endometrium [30]. The amniotic membrane was also used in the treatment of Miller disease for gum recession class I and II. The study compared the efficacy of amniotic membrane and autologous grafts of epithelium taken from the mouth. The results showed that the application of the amniotic membrane instead of connective tissue gives a comparable effect while eliminating the donor site wound, which is crucial for the patient's wellbeing. The studies presented recommend using the amniotic membrane as an alternative to autologous grafts [33]. The amniotic acid was also used in the treatment of periodontitis [34].



**Figure 4:** Clinical effects of using amniotic drafts in toxic epidermal necrolysis on day 0, 4 and 14.

The amniotic membrane combined with deproteinized bovine bone mineral [BMM) was compared in clinical trials with the collagen membrane combined with BBM as to their efficiency in the treatment of periodontal inflammations. It was proved that both the use of amniotic membrane and collagen membrane combined with deproteinized BBM improves the condition of periodontium in the studied patients. The amnion did not cause a significant gum recession and is considered to be a new barrier membrane in the treatment of such diseases [35]. Another disease of the oral cavity is temporomandibular joint ankylosis, which is a serious condition, mainly due to injuries responsible for the reduction of mandible functionality. The amnion was used in the treatment of such injuries as an interdisciplinary membrane characterized with functional adjustment capabilities, non-immunogenicity and low cost. The study proved that the amniotic membrane is a biocompatible material which can find its application in the treatment of temporomandibular joint ankylosis as a good alternative for the prevention of recurrence of ankylosis and restoration of satisfactory functionality of the joints [36].

*In vitro* studies indicated that the amniotic membrane may be useful in the treatment of cancers because of its properties, such as inhibition of angiogenesis and secretion of proapoptotic factors. The study was aimed at the evaluation of cryopreserved amniotic membrane on the induction of cancer cells death and the assessment of its antiangiogenic properties. Cancer cells were treated with fresh and frozen membrane and evaluated in the scope of angiogenesis and levels of antiangiogenic factors. It was shown that the viability of the cultured cancer cells did not differ significantly after treatment with fresh and frozen amniotic membrane. On the other hand, the cryopreservation procedure significantly lowered the levels of the antiangiogenic factors. These promising results show that the capability to induce death of cancer cells and antiangiogenic properties of the amniotic membrane are maintained even after cryopreservation [37]. Another promising feature of the amniotic membrane is its ability to reduce the formation of scar tissue – as a fetal tissue it significantly minimizes cicatrization [38].

Placental drafts may consist of a single layer of amniotic tissue or combine it with a chorionic layer, creating a multilayer draft. The amnion and the chorion together are used in the preparation of thicker grafts.

The application of aseptically prepared amnion and chorion as an allogeneous graft [dehydrated human amnion and chorion allograft, dHACA) was compared with standard treatment for wound closure in

the course of non-healing, chronic diabetic foot ulcers (DFUs). It was proved that aseptically prepared amnion and chorion dressing heals wounds related to diabetic foot ulcers significantly faster than standard treatment – wound healing was achieved as early as after 6 and 12 weeks from grafting, with minimal graft losses [39].

Placental grafts may be prepared also as particles suspended in a fluid, in order to enable injection into places of losses caused during sports-related injuries. Such tissues were injected in order to alleviate pain and promote healing of soft tissues, as well as for the treatment of inflammations and promotion of healing in plantar fascia injuries [24].

Although scientific and clinical data focused mainly on the amnion, there is an increasing interest in the application of other placental tissues as tissue grafts supporting wound healing. Thanks to structural and functional differences between placental tissues, they may provide various products used for the treatment of skin losses of various origins. The structure and biological composition of the umbilical cord and amniotic fluid indicate a possibility of clinical use of other tissues, not only the amniotic membrane. Thicker grafts are easier to suture while liquid grafts enable implantation to the target place by injection.

The umbilical cord and Wharton's jelly are rich in hyaluronic acid and numerous regulatory growth factors and cytokines. As the umbilical cord is thicker than the amniotic membrane, it can be easier for manipulation when a thicker graft for deeper wounds is needed and at the same time it has a comparable composition of regulatory proteins that accelerate wound healing. The amniotic fluid may be transplanted as a liquid graft by an injection to the wound (e.g. OrthoFlo, MiMedx Group, Inc.). The amniotic fluid contains growth factors, cytokines, proteins, carbohydrates, lipids, hormones, electrolytes, hyaluronic acid as well as other nutrients which play a protective and regulatory role in the inflammatory process and promote regenerative processes [3,40,41]. Although clinical data related to the amniotic fluid is limited, there are studies which indicated that amniotic fluid injections are safe, result in pain reduction and support wound healing [42,43].

Furthermore, preclinical models in *in vivo* studies showed that the amniotic fluid facilitates the healing of burns as well as losses of cartilage, bone, tendon and nerve injuries [44,45]. The placenta is also a rich source of collagen, especially collagen type I. That is why placental collagen is currently studied as a potential source for creating collagen scaffoldings in the form of sponge or fillers of empty spaces in existing matrices (e.g. AmnioFill™, MiMedx Group, Inc.). Furthermore,

unbound, purified placental collagen is used for the creation of meshed collagen fibres in the production of threads and materials used in tendon regeneration (e.g. CollaFix™, MiMedx Group, Inc.).

In spite of an increasing social awareness and consequent growth in the number of donors, burn centers suffer from the scarcity of amniotic membranes for grafts due to an increasing clinical demand. Therefore, animal placentas may become an alternative source of tissues for grafts. Our research team has conducted preliminary studies in which the amniotic grafts were prepared from the placentas collected from transgenic pigs. The studies show that the preparation of the pig amnion does not differ largely from that of a human amnion. In the course of the studies, a single collection of placentas from transgenic animals enabled the preparation of significantly more grafts than in the case of human material, which is a great advantage of this source of placentas over human ones. However, it must be pointed out that it is only an alternative source and should not replace human placentas.

## Conclusion

Placentas have a great potential as a source of tissues for the preparation of biostatic and biovital grafts. The preparation of such grafts is performed in tissue banks, in accordance with applicable norms, following the procedures developed. Placental tissues are immunologically privileged as membranes joining the mother and the fetus and exhibit large immune tolerance. The results of the clinical trials show that they ensure a significant improvement of the healing process by providing cytokines which change the wound environment and stimulate endogenous cells. This way they promote the natural process of skin healing. These unique traits of grafts prepared from placental tissues influence their clinical use in the treatment of chronic wounds, burns in Lyell's syndrome, in cosmetic and reconstruction surgery, as well as other medical disciplines, e.g. sports medicine.

Placental grafts are often an alternative therapy in the situations when standard treatment does not yield desirable effects. Such grafts are especially beneficial in comparison to many other bioactive therapies, including low cost, easy manipulation, low immunogenicity, antibacterial properties, inflammation-modulating effect, capability of promoting cell migration and proliferation and stimulation of stem cells activity. These cellular reactions have a beneficial influence on the wound healing process through promotion of tissue reconstruction and inhibition of scarring.

The low cost of graft preparation and lack of ethical dilemmas results in increasingly wider application of placental tissues. In spite of the increasing social awareness and growing number of human amnion donors, in more and more cases the clinical demand for biostatic amniotic grafts exceeds their availability. This results in a need for searching for alternative sources, such as transgenic animals, for example pigs, which enable the collection of a significantly larger placenta during one labor, and the preparation of grafts of larger surface area.

## Acknowledgement

The work presented was financially supported by The National Centre for Research and Development (grant number INNOMED/I/17/NCBR/2014) as part of "INNOMED" entitled: "Development of innovative technologies for the use of transgenic pig tissues for biomedical purposes". Acronym "MEDPIG".

## References

1. Niknejad H, Peirovi H, Jorjani M, Ahmadiani A, Ghanavi J, et al. (2008) Properties of the amniotic membrane for potential use in tissue engineering. *Eur Cell Mater* 15:88-99.
2. Bourne G (1962) The foetal membranes. A review of the anatomy of normal amnion and chorion and some aspects of their function. *Postgrad Med J* 38: 193-201.
3. Underwood MA, Gilbert WM, Sherman MP (2005) Amniotic fluid: not just fetal urine anymore. *J Perinatol* 25: 341-348.
4. Koob TJ, Rennert R, Zabek N, Massee M, Lim JJ, et al. (2013) Biological properties of dehydrated human amnion/chorion composite graft: implications for chronic wound healing. *Int Wound J* 10: 493-500.
5. Massee M, Chinn K, Lei J, Lim JJ, Young CS, et al. (2016) Dehydrated human amnion/chorion membrane regulates stem cell activity in vitro. *J Biomed Mater Res B Appl Biomater* 104: 1495-1503.
6. Maan ZN, Rennert RC, Koob TJ, Januszyk M, Li WW, et al. (2015) Cell recruitment by amnion chorion grafts promotes neovascularization. *J Surg Res* 193: 953-962.
7. Gholipourmalekabadi M, Bandehpour M, Mozafari M, Hashemi A, Ghanbarian H, et al. (2015) Decellularized human amniotic membrane: more is needed for an efficient dressing for protection of burns against antibiotic-resistant bacteria isolated from burn patients. *Burns* 41: 1488-1497.
8. Tehrani FA, Ahmadiani A, Niknejad H (2013) The effects of preservation procedures on antibacterial property of amniotic membrane. *Cryobiology* 67:293-298.
9. Inge E, Talmi YP, Sigler L, Finkelstein Y, Zohar Y, et al. (1991) Antibacterial properties of human amniotic membranes. *Placenta* 12: 285-288.
10. Branski LK, Herndon DN, Celis MM, Norbury WB, Masters OE, et al. (2008) Amnion in the treatment of pediatric partial-thickness facial burns. *Burns*. 34: 393-399.
11. Benirschke K, Burton GJ, Baergen RN (2012) Pathology of the Human Placenta. 6th ed, Springer-Verlag Berlin Heidelberg, New York, p. 941.
12. Cheng T, Yang B, Li D, Ma S, Tian Y, et al. (2015) Wharton's jelly transplantation improves neurologic function in a rat model of traumatic brain injury. *Cell Mol Neurobiol* 35: 641-649.
13. Nevala-Plagemann C, Lee C, Tolar J (2015) Placenta-based therapies for the treatment of epidermolysis bullosa. *Cytotherapy* 17: 786-795.
14. Wu KH, Mo XM, Han ZC, Zhou B (2011) Stem cell engraftment and survival in the ischemic heart. *Ann Thorac Surg* 92: 1917-1925.
15. Sanluis-Verdes A, Yebra-Pimentel Vilar MT, García-Barreiro JJ, García-Camba M, Ibáñez JS, et al. (2015) Production of an acellular matrix from amniotic membrane for the synthesis of a human skin equivalent. *Cell Tissue Bank*. 16: 411-23.
16. Mahmoudi-Rad M, Abolhasani E, Moravvej H, Mahmoudi-Rad N, Mirdamadi Y (2013) Acellular amniotic membrane: an appropriate scaffold for fibroblast proliferation. See comment in PubMed Commons below *Clin Exp Dermatol* 38: 646-651.
17. Xue SL, Chen GG, Lü X, Mei R (2016) Effects of Human Acellular Amniotic Membrane on Postsurgical Recovery of Nail Beds. *Sichuan Da Xue Xue Bao Yi Xue Ban* 47: 533-536.
18. Wilshaw SP, Kearney JN, Fisher J, Ingham E (2006) Production of an acellular amniotic membrane matrix for use in tissue engineering. *Tissue Eng* 12: 2117-2129.
19. Akazawa K, Iwasaki K, Nagata M, Yokoyama N, Ayame H, et al. (2016) Double-layered cell transfer technology for bone regeneration. *Sci Rep*. 6: 33286.
20. Davis JS (1910) Skin transplantation with a review of 550 cases at the Johns Hopkins Hospital. *Johns Hopkins Med* 15: 307-396.
21. Sabella N (1913) Use of fetal membranes in skin grafting. *Med Records NY* 83: 478-480.
22. Dua HS, Azuara-Blanco A (1999) Amniotic membrane transplantation. *Br J Ophthalmol* 83: 748-752.

23. Fetterolf DE, Snyder RJ (2012) Scientific and clinical support for the use of dehydrated amniotic membrane in wound management. *Wounds* 24: 299–307.
24. Zelen CM, Serena TE, Denoziere G, Fetterolf DE (2013) A prospective randomised comparative parallel study of amniotic membrane wound graft in the management of diabetic foot ulcers. *Int Wound J* 10: 502–507.
25. Jeschke MG, Shahrokhi S, Finnerty CC, Branski LK, Dibildox M, et al. (2013) Wound Coverage Technologies in Burn Care: Established Techniques. *J Burn Care Res* 34: 10.
26. Nunes JM, Santareno S, Guerreiro L, Margalho AF (2017) Lyell's Syndrome and Antimalarials: A Case Report and Clinical Review. *J Glob Infect Dis* 9: 23-30.
27. Lissia M, Mulas P, Bulla A, Rubino C (2010) Toxic epidermal necrolysis (Lyell's disease). *Burns* 36: 152-163.
28. Schneider JA, Cohen PR (2017) Stevens-Johnson Syndrome and Toxic Epidermal Necrolysis: A Concise Review with a Comprehensive Summary of Therapeutic Interventions Emphasizing Supportive Measures. *Adv Ther* 34: 1235–1244.
29. Abdo RJ (2016) Treatment of diabetic foot ulcers with dehydrated amniotic membrane allograft: a prospective case series. *J Wound Care* 25: S4-S9.
30. Mohammad J, Shenaq J, Rabinovsky E, Shenaq S (2000) Modulation of peripheral nerve regeneration: a tissue-engineering approach. The role of amnion tube nerve conduit across a 1-centimeter nerve gap. *Plast Reconstr Surg* 105: 660–666.
31. Miyamoto K, Hayashi K, Suzuki T, Ichihara S, Yamada T et al. (2004) Human placenta feeder layers support undifferentiated growth of primate embryonic stem cells. *Stem Cells* 22: 433–440.
32. Jin CZ, Park SR, Choi BH, Lee KY, Kang CK, et al. (2007) Human amniotic membrane as a delivery matrix for articular cartilage repair. *Tissue Eng* 13: 693-702.
33. Lafzi A, Abolfazli N, Faramarzi M, Eyvazi M, Eskandari A, et al. (2016) Clinical comparison of coronally-advanced flap plus amniotic membrane or subepithelial connective tissue in the treatment of Miller's class I and II gingival recessions: A split-mouth study. *J Dent Res Dent Clin Dent Prospects* 10: 162-168.
34. Kiany F, Moloudi F (2005) Amnion membrane as a novel barrier in the treatment of intrabony defects: a controlled clinical trial. *Int J Oral Maxillofac Implants* 30: 639-647.
35. Kim EY, Lee KB, Kim MK (2014) The potential of mesenchymal stem cells derived from amniotic membrane and amniotic fluid for neuronal regenerative therapy. *BMB Rep* 47: 135–140.
36. Akhter M, Ahmed N, Arefin MR, Sobhan MU, Molla MR, et al. (2016) Outcome of amniotic membrane as an interpositional arthroplasty of TMJ ankylosis. *Oral Maxillofac Surg* 20: 63-71.
37. Modaresifar K, Azizian S, Zolghadr M, Moravvej H, Ahmadiani A, et al. (2017) The effect of cryopreservation on anti-cancer activity of human amniotic membrane. *Cryobiology* 74: 61-67.
38. Leavitt T, Hu MS, Marshall CD, Barnes LA, Lorenz HP, et al. (2016) Scarless wound healing: finding the right cells and signals. *Cell Tissue Res* 365: 483–493.
39. DiDomenico LA, Orgill DP, Galiano RD, Serena TE, Carter MJ, et al. (2016) Aseptically Processed Placental Membrane Improves Healing of Diabetic Foot Ulcerations: Prospective, Randomized Clinical Trial. *Plast Reconstr Surg Glob Open* 4: e1095.
40. Hui AY, McCarty WJ, Masuda K, Firestein GS, Sah RL, et al. (2012) A systems biology approach to synovial joint lubrication in health, injury and disease. *Wiley Interdiscip Rev Syst Biol Med* 4: 15–37.
41. Burns C, Hall ST, Smith R, Blackwell C (2015) Cytokine levels in late pregnancy: Are female infants better protected against inflammation? *Front Immunol* 6: 318.
42. Shimberg M (1938) The use of amniotic-fluid concentrate in orthopaedic conditions. *J Bone Joint Surg Br* 20: 167–177.
43. Bhattacharya N (2011) Clinical use of amniotic fluid in osteoarthritis: a source of cell therapy. In: Bhattacharya N, Stubblefield P, editors. *Regenerative Medicine Using Pregnancy-Specific Biological Substances*. Springer, London, 395–403.
44. Bazrafshan A, Owji M, Yazdani M, Varedi M (2014) Activation of mitosis and angiogenesis in diabetes impaired wound healing by processed human amniotic fluid. *J Surg Res* 188: 545–552.
45. Ozgenel GY, Samli B, Ozcan M (2001) Effects of human amniotic fluid on peritendinous adhesion formation and tendon healing after flexor tendon surgery in rabbits. *J Hand Surg Am* 26: 332–339.