

Postpartum Pneumomediastinum and Subcutaneous Emphysema (Hamman's Syndrome)

Awatuf Elshirif*

Department of Obstetrics and Gynaecology, Kings College Hospital NHS Foundation Trust, UK

*Corresponding author: Awatuf Elshirif, Department of Obstetrics and Gynaecology, King's College Hospital NHS Foundation Trust, UK, Tel: 00447872606513; E-mail: awatuf.elshirif@nhs.net

Received date: 05 Jan, 2015; Accepted date: 11 Feb, 2015; Published date: 13 Feb, 2015

Copyright: © 2015 Elshirif A. This is an open-access article distributed under the terms of the Creative Commons Attribution License, which permits unrestricted use, distribution, and reproduction in any medium, provided the original author and source are credited.

Abstract

Spontaneous pneumomediastinum and subcutaneous emphysema (Hamman's syndrome) are rare but potentially dangerous complication of labour, it is usually self-limiting and without any complication or recurrence. Published reports indicate that subsequent pregnancies pose no additional risk for recurrence.

Keywords: Subcutaneous emphysema; Pneumomediastinum; Hamman's syndrome; Childbirth

Introduction

Hamman first described postpartum pneumomediastinum in association with subcutaneous emphysema [1,2]. This condition, also referred to as Hamman's syndrome, is rare, with only about 200 cases reported worldwide [3-5], with an estimated incidence of 1 in 100,000 vaginal deliveries [4]. Despite its daunting presentation, the condition is usually minimal and the course is self-limiting [5-7]. Subcutaneous emphysema in the neck has also been linked to vomiting during pregnancy [8-10].

Chest pain is the most common symptom of pneumomediastinum although the severity depends on the location and amount of air [1,2,7]. Additional symptoms may include dyspnoea, cough, and palpitations. A definitive diagnosis is made radiographically [5].

Case Report

A 27 year old Caucasian primigravida lady was admitted at 41 weeks of gestation to our birthing unit in early labour. She was non smoker, with a BMI (Body Mass Index) of 29 kg/m². She had no past medical or surgical history of note and had an uneventful antenatal course.

Sixteen hours after onset of labour, she progressed to full dilation, with vertex presentation, in the right occiput-posterior position. Her second stage of labour was prolonged to 3 hours. She used Nitrous oxide gas for pain control and had a spontaneous vaginal delivery of a healthy male baby weighing 4570 g with an episiotomy. The third stage of labour lasted five minutes and the episiotomy was subsequently repaired. The immediate postpartum period was unremarkable and she was clinically stable with a blood pressure 126/80 mm of Hg and pulse of 88/minute.

However, four hours following the delivery, she complained of chest heaviness, tightness and a swollen neck. On examination, her blood pressure was 110/60 mmHg, pulse was 80/minute, respiratory rate was 16/minute and Oxygen saturation was 97% on the air. On auscultation, chest was clear with bilateral air entry with equal

expansion. Palpation of neck and chest revealed subcutaneous crepitation and a diagnosis of subcutaneous emphysema was established. The chest X-ray was ordered which showed pneumomediastinum and subcutaneous emphysema of the neck but no pneumothorax (Figure 1a). Double contrast CT of the neck and chest (Figure 1b) revealed significant pneumomediastinum with possible interruption of the right posterolateral aspect of the trachea at the level of the second vertebral body with possibility of a tracheal rupture. It also showed substantial subcutaneous emphysema of the anterior chest wall extending to the root of the neck and extending superiorly to the level of the skull base. There was no evidence of pneumothorax.

She was monitored closely with conservative management (bed rest, analgesia, oxygen and antibiotics), which led to a gradual resolution of subcutaneous emphysema and pneumomediastinum. She was discharged on day 4 after delivery and a repeat chest X ray on day 7 showed complete resolution.

Discussion

Hamman's syndrome is a rare complication of labour and delivery. It usually occurs in the second stage of labour; nevertheless, it is often clinically apparent in postpartum phase.

The prolonged Valsalva manoeuvre (straining with the glottis closed) during the second stage of labour as well as the screaming leads to a rupture of marginally situated alveoli into the pulmonary interstitial space, with tracking of air along the bronchovascular connective tissue planes towards the hilum and mediastinum [7]. Subcutaneous emphysema results when air escapes from the mediastinum into the subcutaneous and deep tissues of the neck. When subcutaneous emphysema in the neck and pneumothorax coexist it is likely that both are secondary to mediastinal emphysema, with perforation of the mediastinal pleura resulting in the pneumothorax [7]. According to Macklin and Macklin [8] common presenting symptoms of pneumomediastinum include retrosternal chest pain, dyspnoea, pleurisy, facial and neck pain, odynophagia, or dysphagia (which can be secondary to pressurized air from alveolar rupture tracking between tissue planes). Chest pain in labour and pregnancy may be due to a number of causes. Since pneumomediastinum is extremely rare, it is essential to exclude

pulmonary embolism, amniotic-fluid embolism, myocardial infarction, pneumothorax, and aortic dissection before making this unusual diagnosis.

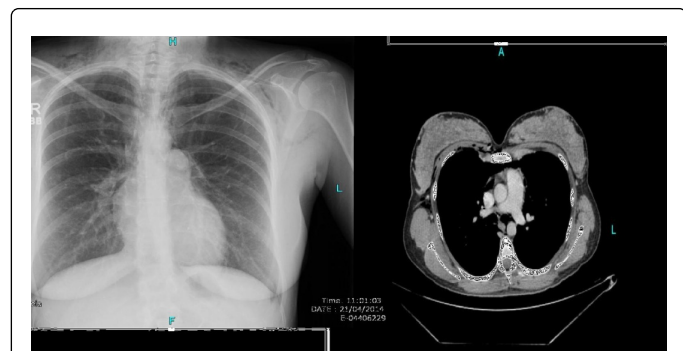


Figure 1: (a) showing pneumomediastinum and subcutaneous emphysema of the neck but no pneumothorax. (b) showing significant pneumomediastinum and substantial subcutaneous emphysema

A thorough history and clinical examination and chest radiograph is often enough to diagnose Spontaneous pneumomediastinum [6]. 30% of spontaneous pneumomediastinum cases may not be easily seen on routine chest X-ray. Double-contrast CT imaging may be helpful, particularly if the air-leak involves the posterior mediastinum [6,9].

Spontaneous pneumo mediastinum is often a benign and self-limiting condition. It is managed conservatively with bedrest, observation, and analgesia. Other complications such as tension pneumomediastinum and pneumothorax are rare. There is currently no reliable data to suggest the rate of recurrence of Spontaneous pneumomediastinum in pregnancy [9]. The use of nitrous oxide increases the risk of gas trapping and may increase the risk of pneumomediastinum [3]. In patients with a history of pneumomediastinum, it may therefore be prudent to avoid the use of nitrous oxide. While the second stage of labour is generally shorter for multiparous patients, epidural analgesia may be discussed as a method of avoiding premature or prolonged pushing in the late first or early second stages of labour. If spontaneous pneumomediastinum is recognized early, it is felt that delivery should be hastened (for

example, by Ventouse, forceps, or urgent cesarean section) to minimize prolonged or strenuous valsalva and progression of mediastinal emphysema.

Conclusion

Recognition of spontaneous pneumomediastinum and its potential consequences during labour and delivery requires vigilance. Supportive measures alone may be the only requirement for resolution. Recurrence of the condition is rare, but the appropriate management of subsequent pregnancies is unclear. Expectant management with epidural analgesia to minimize active pushing is suggested in a subsequent spontaneous vaginal delivery.

References

1. Kandiah S, Iswariah H, Elgey S (2013) Postpartum pneumomediastinum and subcutaneous emphysema: two case reports. *Case Rep Obstet Gynecol* 735154.
2. Kouki S, Fares AA (2013) Postpartum spontaneous pneumomediastinum 'Hamman's syndrome'. *BMJ Case Rep*.
3. Jayran-Nejad Y (1993) Subcutaneous emphysema in labour. *Anaesthesia* 48: 139-140.
4. Heffner JE, Sahn SA (1992) Pleural disease in pregnancy. *Clinics in Chest Medicine* 13: 667-678.
5. Seidl JJ, Brotzman GL (1994) Pneumomediastinum and subcutaneous emphysema following vaginal delivery: case report and review of the literature. *Journal of Family Practice* 39: 178-180.
6. Kaneki T, Kubo K, Kawashima A, Koizumi T, Sekiguchi M, et al. (2000) Spontaneous pneumomediastinum in 33 patients: Yield of chest computed tomography for the diagnosis of the mild type. *Respiration* 67: 408-411.
7. Hamman L (1945) Mediastinal emphysema. *JAMA* 128: 1-6.
8. Macklin MT, Macklin CC (1944) Malignant interstitial emphysema of the lungs and mediastinum as an important occult complication in many respiratory diseases and other conditions: an interpretation of the clinical literature in light of laboratory experiment. *Medicine* 23: 281-358.
9. Revicky V, Simpson P, Fraser D (2010) Postpartum pneumomediastinum: An uncommon cause for chest pain. *Obstetrics and Gynecology International*.
10. Woolford TJ, Birzgalis AR, Lundell C, Farrington WT (1993) Vomiting in pregnancy resulting in oesophageal perforation in a 15-year-old. *Journal of Laryngology and Otology* 107: 1059-1060.