

Patellar Subacute Hematogenous Osteomyelitis in Children Due To *K. Kingae*: A Report of Two Cases

Eleftheria Samara^{1*}, Christina Steiger¹, Raimonda Valaikaite¹, Vasiliki Spyropoulou¹, Amira Dhouib Chargui² and Dimitri Ceroni²

¹Department of Child and Adolescent Medicine, University Hospitals of Geneva, Switzerland

²Pediatric Radiologic Unit, University Hospitals of Geneva, Switzerland

*Corresponding author: Eleftheria Samara, Department of Child and Adolescent Medicine, University Hospitals of Geneva, Switzerland, Tel: +41(22) 382.47.91; E-mail: eleftheria.samara@hcuge.ch

Received date: August 10, 2016; Accepted date: December 29, 2016; Published date: January 05, 2017

Copyright: ©2017 Samara E, et al. This is an open-access article distributed under the terms of the Creative Commons Attribution License, which permits unrestricted use, distribution, and reproduction in any medium, provided the original author and source are credited.

Abstract

Isolated osteomyelitis of the patella is a rare condition mainly occurring in the pediatric population. Diagnosis is often delayed as clinical presentation manifests with vague anterior knee pain, sometimes with mild local signs of inflammation but frequently without any local signs at all. While falls on the knee can explain mild knee pain, erythema, swelling and persistent peripatellar pain should raise a high index of suspicion for local infection. We present two cases of subacute osteomyelitis of the patella in young children. In both cases bone lesions presented as an osteolytic lesion of the patella. After open biopsy of the lesion, bacteriological analysis confirmed infection with *Kingella kingae*.

Keywords: Osteomyelitis; *Kingella kingae*; Trauma; Bone edema; Intravenous antibiotics; Radiographic; PCR

Level of Evidence

Case reports, level IV.

Case Report 1

A 14-month-old Caucasian girl was admitted to the emergency department (ED) of our hospital due to persistent limping for more than 2 weeks. There was no history of trauma. A febrile episode (38.7°C) had occurred approximately 2 weeks before presentation at the ED, but as symptoms had decreased progressively no investigations into the cause of infection and no treatment had been undertaken. On admittance to our hospital, the child was afebrile and walked with a stiff knee. Clinical examination revealed right-sided knee pain, slight prepatellar edema, and a mild knee joint effusion. Laboratory results showed a white blood cell count of 17,000 cells/mm³, normal C-reactive protein (2 mg/dL) and erythrocyte sedimentation rate (11 mm/h), but a high platelet count (520.000cells/mm³). Conventional radiograph showed no significant abnormality. MRI demonstrated prepatellar soft tissue swelling, joint effusion, synovial enhancement and bone edema, all signs compatible with septic arthritis (Figure 1). Moreover, MRI revealed an osteolytic lesion located in the upper part of the right patella with anterior erosion of the cortical bone. The child underwent joint aspiration where a small quantity of mildly opaque liquid was extracted; the joint cavity was then thoroughly irrigated and the patient was immediately started on intravenous antibiotics (cefuroxime). A switch to oral antibiotics was undertaken after 3 days and treatment was continued for another 20 days. No pathogen was cultivated from the joint fluid, but *K. kingae* specific rtPCR gave a positive result. At the final clinical control, 12 months after surgery, the child did not complain about any pain and gait was normal. The clinical exam did not reveal any tenderness, swelling or erythema around the knee and the range of motion of the right knee joint was

normal. Radiographs showed a normal patella without pathological findings.

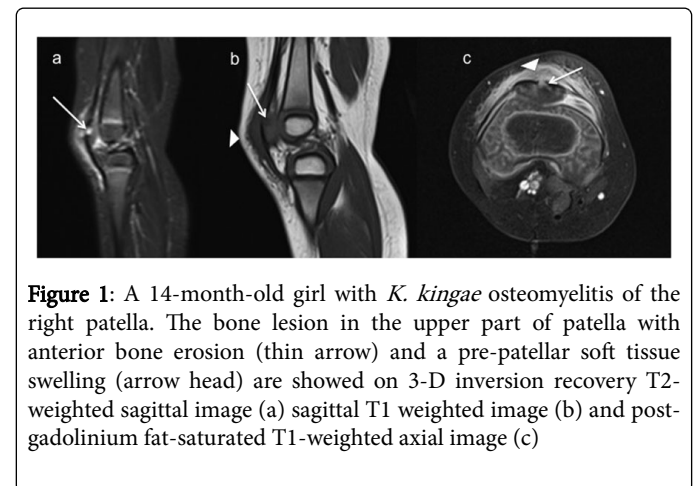


Figure 1: A 14-month-old girl with *K. kingae* osteomyelitis of the right patella. The bone lesion in the upper part of patella with anterior bone erosion (thin arrow) and a pre-patellar soft tissue swelling (arrow head) are showed on 3-D inversion recovery T2-weighted sagittal image (a) sagittal T1 weighted image (b) and post-gadolinium fat-saturated T1-weighted axial image (c)

Case Report 2

A 6-year-old girl was referred to our department because of persistent pain in her left knee which lasted for more than 3 weeks. There was no history of trauma and no signs of physical abuse. At the admission, the child was afebrile, and on examination, there was a slight prepatellar swelling but no intraarticular effusion. Her white blood cell count was 12.500 cells/mm³, the C reactive protein was 2 mg/dL, and ESR 11 mm/h. The plain radiograph showed a slightly irregular patellar ossification but did not reveal any other pathologic result. MRI showed a lytic lesion in the lateral part of the patella, with pre-patellar soft tissue swelling, but without evidence of septic arthritis (Figure 2). Open biopsy using a direct approach to the patella centered over the lytic lesion was performed. Through a window in the anterior surface of the patella, debridement and curettage of purulent material was carried out, leaving a limited bone defect (7-8 mm). Microbiologic

cultures of the obtained purulent material remained negative, but *K. kingae* presence was confirmed by specific rtPCR. The girl was immediately started on intravenous antibiotics (co-amoxicillin), and she was switched to oral antibiotics after 3 days. Treatment was continued for another 18 days. At the final follow-up 18 months postoperatively, clinical examination revealed a normal knee status with a normal range of motion. The girl had returned to all sports activities and reported no pain. Radiographic evaluation revealed a normal patellar bone growth and new bone formation replacing the previously visible bone defect.

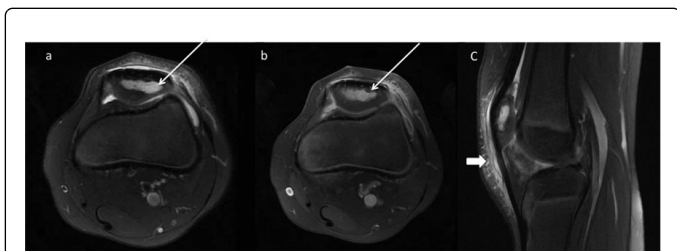


Figure 2: A 6-year-old girl with *K. kingae* osteomyelitis of the left patella. The bone lesion (thin arrow) and pre-patellar soft tissue swelling (thick arrow) are shown on a fat-saturated T2-weighted axial image (a) post-gadolinium fat-saturated T1-weighted axial image (b) and fat-saturated T2-weighted sagittal image (c).

Discussion

Osteomyelitis of the patella is a rare condition predominantly occurring in children [1-8]. Frequently the source of bacteremia is an occult infection and thus diagnosis of hematogenous osteomyelitis is often delayed [6,7,9]. Consequently treatment is delayed as well giving way to possible complications such as abscess formation, cartilage destruction and septic arthritis due to penetration of the patellar infection into the knee joint [10]. If acute osteomyelitis remains undiagnosed progressive transition in a chronic sequestering stage of the osteomyelitis can take place leading to distinct bony defects [10].

subacute osteomyelitis with radiographic evidence of lucent lesions or nidus is curettage, biopsy and culture followed by antibiotics [22-25]. Some authors have suggested that antibiotics alone may be adequate and that surgery should be considered only for "aggressive

According to King and Mayo, any bone infection lasting more than 2 weeks without acute symptomatology can be referred to as subacute osteomyelitis [18]. Subacute hematogenous osteomyelitis is most likely due to an atypical host-pathogen relationship that may comprise any combination of: increased host resistance; decreased virulence of the causative organism; and/or prior antibiotic exposure [13,14, 20,27,28]. Since the 1980s, the number of *K. kingae* osteoarticular infections (OAI) has markedly increased [22,23,29-33] and several current studies indicate that *K. kingae* is becoming a leading cause of bacterial osteoarticular infections in children aged from 6-48 months [23,30,31]. *K. kingae* has a naturally low virulence and OAIs caused by this pathogen are characterized by a mild-to-moderate clinical and biological inflammatory response [22,23,29,30,33,34]. Thus *K. kingae* is a pathogen likely to cause subacute OAI. The symptomatology found in the above reported cases also corresponds to that of a subacute hematogenous osteomyelitis further reinforcing our hypothesis. Improving recognition of infection due to *K. kingae* is thus the next problem to resolve and there is a need for new diagnostic tests to

improve their diagnosis. For example, a simple technique to detect *K. kingae* rtx toxin genes in the oropharynx might provide strong evidence that this microorganism is responsible for the OAI [22]. The positive predictive value of PCR detection in a pharyngeal sample is around 90%; however, the negative predictive value of this test is very high and failure to detect RTX gene sequences in the pharynx practically excludes the bacterium as the etiology of the OAI [22,34]. Such a non-invasive approach to diagnosis improves patient safety and comfort and reduces healthcare costs by reducing the need for invasive diagnostic procedures. A radiological paper has demonstrated also that magnetic resonance imaging was useful in differentiating OAI due to *K. kingae* from those due to gram-positive cocci. In this study, epiphyseal cartilaginous involvement and modest soft tissues and bone reactions were suggestive for AHO due to *K. kingae*. There is also the need to have a criterion for distinguishing quickly OAI due to *K. kingae* than those due to pyogenic pathogens. A model to allow the differentiation of *K. kingae* OAI from those due to typical pathogens in children aged less than 4 years, has been described and consists of the following four parameters: T° at admission $<38^{\circ}$; C-reactive protein <55 mg/L; WBC count $<14,000$ leucocytes/mm³, and band shift <150 forms/mm³ [10]. Even if this model is a subject of controversy, it underlines the need for prospective studies to better define the clinical presentation according to the children's age and causative organisms. In conclusion, persistent anterior knee pain without previous trauma should raise the suspicion of hematogenous osteomyelitis of the patella. It is important for pediatricians to remember the significant incidence of *K. kingae* infections in young infants and bear in mind that these infections can have a different clinical presentation to osteoarticular infections due to other microorganisms. We also think that other fastidious germs can be involved in osteoarticular infection in children and that further efforts should be made to develop new techniques to identify them.

References

1. Angella JJ (1960) Osteomyelitis of the patella. Am J Dis Child 113: 590-593.
2. Cahill BR (1978) Nontraumatic osteomyelitis of the patella. Clin Orthop Relat Res 132: 177-179.
3. Choi HR (2007) Patellar osteomyelitis presenting as prepatellar bursitis. Knee 14: 333-335.
4. Guerci A, Mainard D, Thiery D (1992) Acute hematogenous osteomyelitis of the patella revealed by a pathological fracture in multiple myeloma. J Intern Med 231: 87-88.
5. Kankate RK, Selvan TP (2000) Primary hematogenous osteomyelitis of the patella: a rare cause for anterior knee pain in an adult. Postgrad Med J 76: 707-709.
6. Roy DR (2001) Osteomyelitis of the patella. Clin Orthop Relat Res 389: 30-34.
7. Roy DR, Greene WB, Gamble JG (1991) Osteomyelitis of the patella in children. J Pediatr Orthop 11: 364-366.
8. Vaninbrouck J, Martens M, Verhelst M, Mulier JC (1976) Hematogenous osteomyelitis of the patella. Report of three cases. Acta Orthop Scand 47: 566-569.
9. de Gheldere A (2009) Hematogenous osteomyelitis of the patella in a child. Acta Orthop Belg 75: 554-556.
10. Kallfelz CWR, Kriewitz M, Stölben A, von Laer L (2015) Acute Hematogenous Osteomyelitis of the Patella in Childhood. Ann Orthop Rheumatol 3: 1046.
11. Ezra E, Cohen N, Segev E, Hayek S, Lokiec F, et al. (2002) Primary subacute epiphyseal osteomyelitis: role of conservative treatment. J Pediatr Orthop 22: 333-337.

12. Ezra E, Wientroub S (1997) Primary subacute haematogenous osteomyelitis of the tarsal bones in children. *J Bone Joint Surg* 79: 983-986.
13. Gillespie WJ, Moore TE, Mayo KM (1986) Subacute pyogenic osteomyelitis. *Orthopedics* 9: 1565-1570.
14. Gledhill RB (1973) Subacute osteomyelitis in children. *Clin Orthop Relat Res* 96: 57-69.
15. Hamdy RC, Lawton L, Carey T, Wiley J, Marton D (1996) Subacute hematogenous osteomyelitis: are biopsy and surgery always indicated?. *J Pediatr Orthop* 16: 220-223.
16. Harris NH, Kirkaldy-Willis WH (1965) Primary Subacute Pyogenic Osteomyelitis. *The J Bone Joint Surg Br* 47: 526-532.
17. Jones NS, Anderson DJ, Stiles PJ (1987) Osteomyelitis in a general hospital. A five-year study showing an increase in subacute osteomyelitis. *J Bone Joint Surg Br* 69: 779-783.
18. King DM, Mayo KM (1969) Subacute haematogenous osteomyelitis. *J Bone Joint Surg Br* 51: 458-463.
19. Kozlowski K (1980) Brodie's abscess in the first decade of life. Report of eleven cases. *Pediatr Radiol* 10: 33-37.
20. Roberts JM, Drummond DS, Breed AL, Chesney J (1982) Subacute hematogenous osteomyelitis in children: a retrospective study. *J Pediatr Orthop* 2: 249-254.
21. Season EH, Miller PR (1976) Multifocal subacute pyogenic osteomyelitis in a child. A case report. *Clin Orthop Relat Res* 116: 76-79.
22. Ceroni D, Cherkaoui A, Combescure C, Francois P, Kaelin A, et al. (2011) Differentiating osteoarticular infections caused by *Kingella kingae* from those due to typical pathogens in young children. *Pediatr Infect Dis J* 30: 906-909.
23. Ceroni D, Cherkaoui A, Ferey S, Kaelin A, Schrenzel J (2010) *Kingella kingae* osteoarticular infections in young children: clinical features and contribution of a new specific real-time PCR assay to the diagnosis. *J Pediatr Orthop* 30: 301-304.
24. Yagupsky P (2004) *Kingella kingae*: from medical rarity to an emerging paediatric pathogen. *Lancet Infect Dis* 4: 358-367.
25. Yagupsky P, Dagan R, Howard CW, Einhorn M, Kassis I, et al. (1992) High prevalence of *Kingella kingae* in joint fluid from children with septic arthritis revealed by the BACTEC blood culture system. *J Clin Microbiol* 30: 1278-1281.
26. Spyropoulou V, Dhoub Chargui A, Merlini L, Samara E, Valaikaite R, et al. (2016) Primary subacute hematogenous osteomyelitis in children: a clearer bacteriological etiology. *J Child Orthop* 10: 241-246.
27. Dormans JP, Drummond DS (1994) Pediatric Hematogenous Osteomyelitis: New Trends in Presentation, Diagnosis, and Treatment. *J Am Acad Orthop Surg* 2: 333-341.
28. Green NE, Beauchamp RD, Griffin PP (1981) Primary subacute epiphyseal osteomyelitis. *J Bone Joint Surg Am* 63: 107-114.
29. Chometon S, Benito Y, Chaker M, Boisset S, Ploton C, et al. (2007) Specific real-time polymerase chain reaction places *Kingella kingae* as the most common cause of osteoarticular infections in young children. *Pediatr Infect Dis J* 26: 377-381.
30. Ilharreborde B, Bidet P, Lorrot M, Even J, Mariani-Kurkdjian P, et al. (2009) New real-time PCR-based method for *Kingella kingae* DNA detection: application to samples collected from 89 children with acute arthritis. *J Clin Microbiol* 47: 1837-1841.
31. Moumile K, Mercck J, Glorion C, Berche P, Ferroni A (2003) Osteoarticular infections caused by *Kingella kingae* in children: contribution of polymerase chain reaction to the microbiologic diagnosis. *Pediatr Infect Dis J* 22: 837-839.
32. Rosey AL, Abachin E, Quesnes G, Cadilhac C, Pejin Z, et al. (2007) Development of a broad-range 16S rDNA real-time PCR for the diagnosis of septic arthritis in children. *J Microbiol Methods* 68: 88-93.
33. Verdier I, Gayet-Ageron A, Ploton C, Taylor P, Benito Y, et al. (2005) Contribution of a broad range polymerase chain reaction to the diagnosis of osteoarticular infections caused by *Kingella kingae*: description of twenty-four recent pediatric diagnoses. *Pediatr Infect Dis J* 24: 692-696.
34. Dubnov-Raz G, Scheuerman O, Chodick G, Finkelstein Y, Samra Z, et al. (2008) Invasive *Kingella kingae* infections in children: clinical and laboratory characteristics. *Pediatrics* 122: 1305-1309.