

OSAS Treatment with Mandibular Osteotomy Modified Associated with Virtually Planned Orthognathic Surgery

Francisco Bruno Nunes Nascimento Silva^{1*}, Lucas Cavalieri Pereira¹, Giulia Quarentei Barros Brancher¹, Gabriela Pedroso de Oliveira¹, Christian José de Oliveira Macedo¹, Luiz Roberto Cerezetti¹, Samuel Cavalieri Pereira²

¹Department of Oral and Maxillofacial Surgery, Piracicaba Cane Suppliers Hospital, Brazil; ²Plastic surgeon, Member of the Brazilian Society of Plastic Surgery, Brazil

ABSTRACT

Obstructive sleep apnea (OSA) is a common sleep disorder classically characterized by apneic events that lead to intermittent hypoxia and sleep fragmentation. Its consequences are serious, mainly in terms of quality of life and cardiovascular risk. Orthognathic surgery of the maxillomandibular advancement has increased in popularity as a treatment option for OSAS due to the increase in the entire velo-oro-hypopharyngeal air system. A modified osteotomy is indicated for patients with severe obstructive sleep apnea who already have a prominent profile. In these cases, it is necessary to advance the suprahyoid muscles without changing the facial profile. The genioglossus is crucial to maintaining a pharyngeal patent in the air due to the anterior traction of the tongue. The advancement of the genioglossus muscle has been reported as an option for the surgical treatment of obstructive sleep apnea syndrome, which through its traction can increase the retrolingual airway without altering facial or dental appearance. The present study aims to report a clinical case of a female patient (N.M.A.T.), 52 years old, presenting complaints of lack of concentration and fatigue on light effort, OSAS confirmed by polysomnography and snoring. On facial tomography, retrognathism and reduction of the upper airways were observed. Orthognathic surgery with counterclockwise rotation of the maxillary-mandibular complex, associated mandibular and maxillary advancement was the treatment of choice, associated with the advancement of the genioglossus muscle through modified osteotomy in the anterior portion of the mandible. The virtual planning was carried out for the case, with the preparation of pre and transoperative guides and with the purpose of visualizing the growth of the airways. The patient improved his facial profile and airways due to anterior muscle traction, evolving without complaints.

Keywords: Orthognathic Surgery; Apnea; Genioplasty; Retrognathia

INTRODUCTION

Obstructive sleep apnea (OSA) is a common sleep disorder classically characterized by apneic events that lead to intermittent hypoxia and sleep fragmentation [1]. There are two types of OSA: obstructive sleep apnea syndrome (OSAS) and central sleep apnea syndrome (CSAS). OSAS is a prevalent disorder in which there is snoring, repetitive apneic episodes and daytime sleepiness. Obesity and craniofacial anomalies (such as

retrognathism or micrognathism) are the main causes of upper airway obstruction, which can lead to apnea [2].

Patients with obstructive sleep apnea syndrome (OSAS) usually suffer from numerous harmful conditions, such as cardiac arrhythmias, cardiac arrest, sudden death, systemic inflammation, and endothelial dysfunction. Although the etiology and pathogenesis of OSAS are not fully understood, anatomic obstruction and increased resistance in the postero-superior airway are known to cause OSAS [3].

*Correspondence to: Francisco Bruno Nunes Nascimento Silva, Resident of the Residency Training Program at the Department of Oral and Maxillofacial Surgery of Piracicaba Cane Suppliers Hospital, Brazil, Tel: +5586981700105; E-mail: drbrunonunes@outlook.com

Received: February 29, 2020; Accepted: June 22, 2020; Published: June 29, 2020

Citation: Silva FBNN, Cavalieri Pereira L, Brancher GQB, Pedroso de Oliveira G, Macedo CJO, Cerezetti LR, et al. (2020) OSAS Treatment with Mandibular Osteotomy Modified Associated with Virtually Planned Orthognathic Surgery. J Sleep Disord Ther 9:310. doi: 10.35248/2167-0277.20.9.310.

Copyright: © 2020 Silva FBNN, et al. This is an open-access article distributed under the terms of the Creative Commons Attribution License, which permits unrestricted use, distribution, and reproduction in any medium, provided the original author and source are credited.

Continuous Positive Airway Pressure (CPAP) improves airflow and quality of life for patients. However, because of the cumbersome use of CPAP, patients often decline or do not adhere to this treatment. Intraoral device therapy is an effective alternative in mild to moderate OSAS cases. Most of the oral appliances used in clinical setting are mandibular advancement devices, keeping the mandible and its attached musculature in a prominent position. Maxillo-mandibular advancement surgery has increased in popularity due to the increase of the entire veloro-hypopharyngeal airway system, with 75% to 100% success in correcting OSAS [4,5].

The advancement of the genioglossus muscle was reported as an option for the surgical treatment of obstructive sleep apnea syndrome [6]. Genioglossus is crucial in maintaining an airborne pharyngeal patent due to anterior tongue traction. The advancement of the genioglossus muscle and the hyoid suspension are relatively conservative techniques that can enlarge the retrolingual airway without occlusion alteration, facial or dental aesthetics. These techniques are also associated with lower morbidity than procedures such as glossectomy and linguoplasty, which directly modify the base of the tongue [7].

CLINICAL CASE REPORT

The clinical case reported was a female patient (N.M.A.T.), 52 years old, leucoderma, who arrived at the Oral and Maxillofacial Department of Piracicaba Cane Suppliers Hospital presenting functional complaints of snoring, lack of concentration, fatigue at light exertion and excessive daytime sleep. In face tomography (Figures 1 and 2), retrognathism and reduced superior airway were observed. Associated with clinical and radiographic examination, Polysomnography concluded the diagnosis of Obstructive Sleep Apnea Syndrome (OSAS).

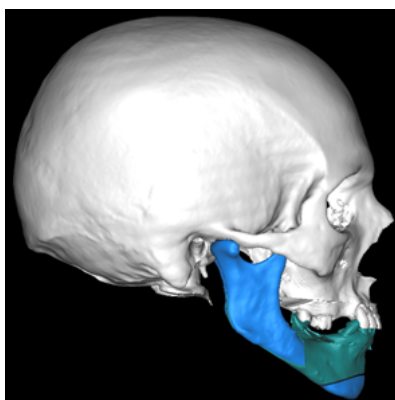


Figure 1: Preoperative CT with virtual osteotomy markings to be performed in Orthognathic surgery.

The planning of the surgery was performed virtually, associated to the preparation of customized preoperative guides, providing surgery with greater predictability (Figure 3).

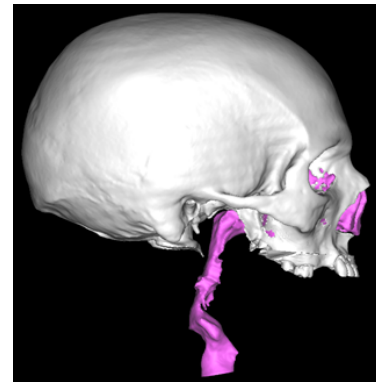


Figure 2: Preoperative CT showing preoperative airway.

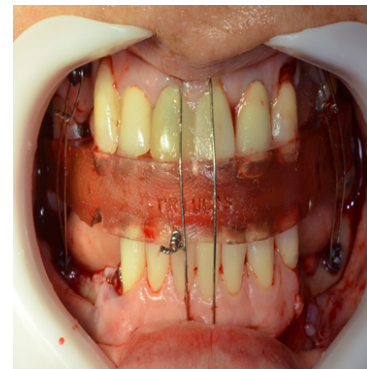


Figure 3: Preoperative occlusion with intermediate intermaxillary guide.

The patient had a profile with important mental projection, which required a change in the conventional planning of mandibular advancement. A modification was chosen, where an osteotomy was performed in the anterior region of the mandible, followed by joint bone traction to the adhered muscles, fixing it in a prominent position, however, without altering the mental projection of the same, providing an improvement in facial profile (Figure 4 to 7).

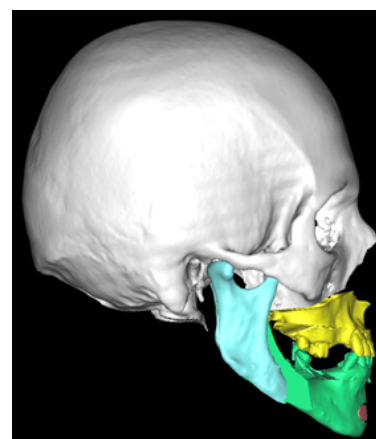


Figure 4: Virtual planning of bimaxillary advancement with modified osteotomy in mental region.

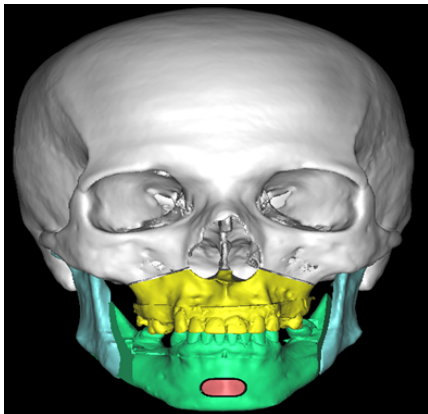


Figure 5: Virtual planning of bimaxillary advancement with modified osteotomy in mental region.

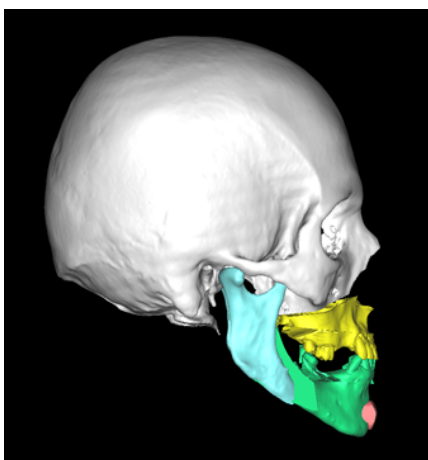


Figure 6: Virtual planning of bimaxillary advancement with rotation of modified osteotomy in mental region.

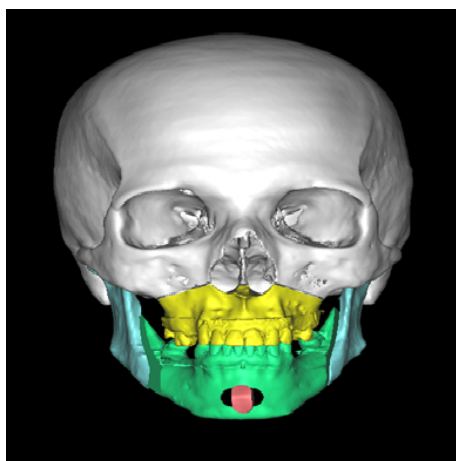


Figure 7: Virtual planning of bimaxillary advancement with rotation of modified osteotomy in mental region.

The surgery was performed under general anesthesia, without complications (Figure 8 to 14). In subsequent follow-up, the patient reports improvement in respiration and end of complaints of snoring, tiredness and daytime sleep. A harmonic facial profile was obtained and the patient was followed up without complaints (Figures 15 to 18).

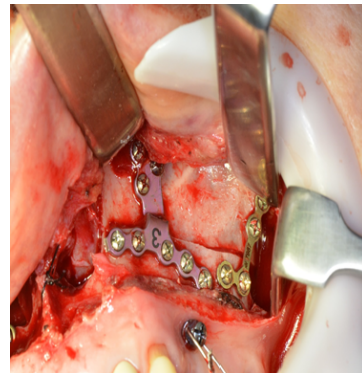


Figure 8: Fixation for left osteotomy Lefort I.

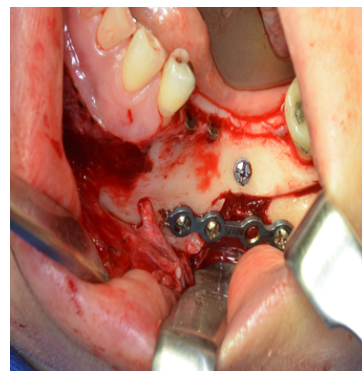


Figure 9: Fixation for sagittal osteotomy of the left mandibular ramus.

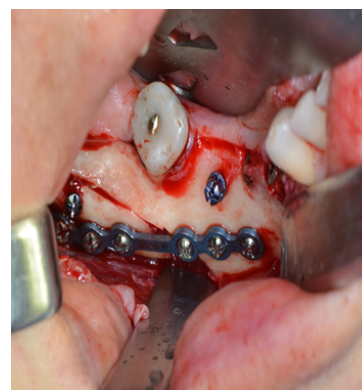

Figure 10: Fixation for sagittal osteotomy of the right mandibular ramus.

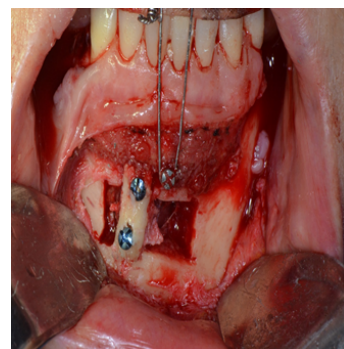


Figure 11: Fixation of the anterior bone block of the mental region in a new position.

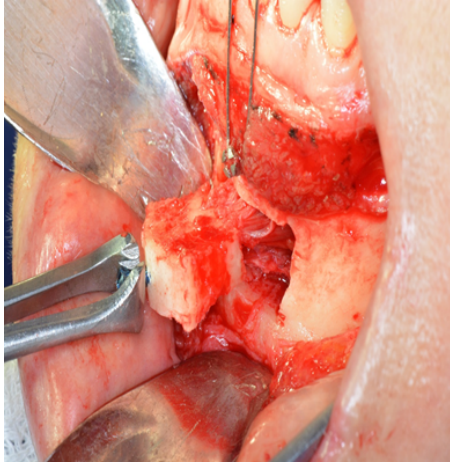


Figure 12: Traction of the anterior bone block of the mental region with the adhered Genioglossus muscle.

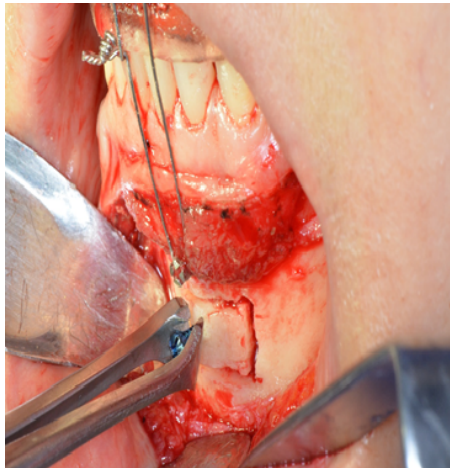


Figure 13: Traction of the anterior bone block of the mental region with the adhered Genioglossus muscle.

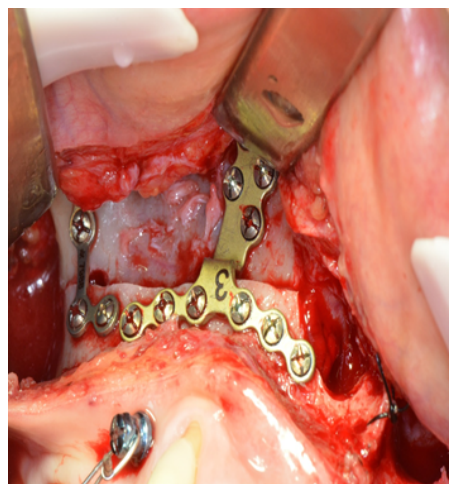


Figure 14: Fixation for right osteotomy Lefort I.



Figure 15: Preoperative.

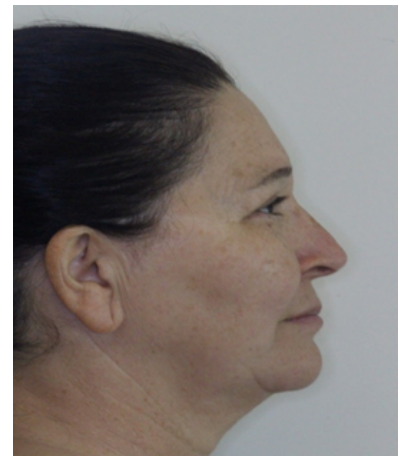

Figure 16: Preoperative.



Figure 17: Postoperative.

DISCUSSION

In 1969, tracheostomy was reported as an effective surgical modality in the treatment of OSAS, completely ignoring airway obstruction in the pharyngeal region. However, tracheostomy is associated with frequent complications such as infection, vocal problems, tracheal stenosis and negative psychosocial impact. Ikematsu, in 1964, proposed uvulopalatopharyngoplasty (UPPP) for the treatment of habitual snoring [8]. In 1979, Fujita et al.

described the initial results of UPPP in OSAS patients and quickly became the treatment of choice [9]. Subsequently, the high failure rates (approximately 50%) of UPPP led to the start of mass use of orthognathic surgery for the treatment of OSAS [7], whose treatment was chosen in this case report.

Dentofacial deformities are considered a major risk factor for obstructive sleep apnea-hypopnea syndrome (SAHSO) in non-obese patients and include mandibular and maxillary retrognathism, tongue retroposition, and an increase in the lower third of the face. Mandibular retrognathism may be one of the factors that reduce posterior air space and decrease the distance between the hyoid bone and the mandibular plane, promoting obstruction in the hypopharynx [10].

Surgical correction of obstructive sleep apnea syndrome (OSAS) involves the understanding of several parameters, of which the anatomical three-dimensional (3D) airway is important. Recent advances in upper airway visualization based on concomitant computed tomography (CBCT) and specific 3D manipulation programs have been of great help in understanding normal and abnormal airway conditions and their response to surgery [5]. In this case, by CT scan analysis, it was possible to clearly observe the upper airway obstruction present and the postoperative result obtained.

The use of nasopharyngolaryngoscopy can help to identify regions in the airway that may have influence on nocturnal obstruction (nose, retropalatal area and base of the tongue). In addition, it is useful to identify other causes of upper airway obstruction, such as tumors, cysts, lingual tonsils, and laryngeal pathology [5].

Orthognathic surgery is widely used to correct facial and maxillary discrepancies in which position, aesthetics or functional capacity are in disharmony [11]. Associated with orthognathic, nasal surgical procedures such as septoplasty and lower concha reduction can be performed in favor of increased airspace [5].

The upper airway can be opened by advancement mentoplasty, but this can compromise the facial aesthetics by superimposing the prominence of the chin. To overcome this difficulty, a modification of the osteotomy is an option, allowing a repositioning that allows the advancement of the genioglossus muscle, avoiding excessive projection of the chin, preserving a harmonic profile [12].

A modified osteotomy in ment is indicated for patients with severe obstructive sleep apnea who already have a prominent developing profile. In these cases, it is necessary to advance the genital muscles without altering the facial profile [13]. In patients with relatively harmonic profile, as in this case report, it is opted for modifications in the standard technique to avoid biprotusion.

Mezzanotte et al. compared genioglossus muscle tone during wakefulness in patients with normal OSAS and control [14]. They found activity in the basal portion of genioglossus in patients with OSAS and speculated that this neuromuscular compensation present during wakefulness in patients with apnea may be lost during sleep, leading to loss of tone and collapse of

the airways. With this knowledge, the elongation of the genioglossus muscle has a physiological basis and seems to be a useful treatment for this syndrome [6].

During normal breathing, contraction of the upper airway and diaphragmatic muscles act synchronously to maintain airway permeability, avoiding hypoxemia and hypercapnia. The genioglossus muscle is crucial in maintaining a pharyngeal patent. It serves as one of the main determinants of language position. Electromyogram (EMG) studies evaluating the genioglossus muscle in patients with OSAS versus control showed an increase in the tone of the muscle during inspiration while awake, avoiding airway occlusion. When sleeping this activity decreases and obstruction occurs [7].

CONCLUSION

The treatment of OSAS is important because of the complications that this syndrome can generate, from changes in the quality of life to the important cardiological/neurological alterations. Knowledge of the syndrome, relevance of anamnesis, clinical examination and attention to the patient's complaints guide the best treatment for the patient, promoting an ideal outcome with a good prognosis.

The virtual planning of the case promotes great surgical predictability, shortening of operative time, reduction of risks of accidents and complications, besides allowing an individualized treatment for each case. Orthognathic surgery is one of the forms of treatment of OSAS, presenting satisfactory results in the short, medium and long term.

REFERENCES

1. Framnes SN, Arble DM. The Bidirectional Relationship between Obstructive Sleep Apnea and Metabolic Disease. *Front Endocrinol (Lausanne)*. 2018; 9:440
2. Banno K, Kryger MH. Sleep apnea: Clinical investigations in humans. *Sleep Medicine*. 2007;8(4):400-426.
3. Kim S, Lee K, Bae SJ, Hahn JS. Promoters inducible by aromatic amino acids and γ -aminobutyrate (GABA) for metabolic engineering applications in *Saccharomyces cerevisiae*. *Appl Microbiol Biotechnol*. 2015;99(6):2705-2714.
4. Doff MHJ, Jansma J, Schepers RH, Hoekema A. Maxillomandibular Advancement Surgery as Alternative to Continuous Positive Airway Pressure in Morbidly Severe Obstructive Sleep Apnea: A Case Report. *Cranio*. 2013;31(4): 246-251.
5. Schendel S, Powell N, Jacobson R. Maxillary, Mandibular, and Chin Advancement: Treatment Planning Based on Airway Anatomy in Obstructive Sleep Apnea. *Journal of Oral and Maxillofacial Surgery*. 2011;69(3):663-676.
6. Rojas R, Chateau R, Gaete C, Muñoz C. Genioglossus muscle advancement and simultaneous sliding genioplasty in the management of sleep apnoea. *International Journal of Oral and Maxillofacial Surgery*. 2017;47(5):638-641.
7. Hendler B, Silverstein K, Giannakopoulos H. Mortised Genioplasty in the Treatment of Obstructive Sleep Apnea: An Historical Perspective and Modification of Design. *Sleep Breath*. 2001;5:173-180.
8. Ikematsu T. Study of snoring. 4th report. Therapy (in Japanese). *J Jpn Otol Rhinol Laryngol Soc*. 1964;64:434-435.

9. Fujita K. New orthodontic treatment with lingual bracket mushroom arch wire appliance. *American Journal of Orthodontics*. 1981;79(6):657-675.
10. Santos Junior JF. Mentoplastia para avanço do músculo genioglossos em pacientes com síndrome da apnéia-hipopnéia do sono obstrutiva e retrognatismo mandibular. *Rev Bras Otorrinolaringol*. 2007;73(4):480-486.
11. Tepecik T, Ertas Ü, Akgün M. Effects of bimaxillary orthognathic surgery on pharyngeal airway and respiratory function at sleep in patients with class III skeletal relationship. *J Craniomaxillofac Surg*. 2018;46(4):645-653.
12. Heggie AA, Portnof, JE, Kumar R. The rotational genioplasty: a modified technique for patients with obstructive sleep apnoea. *International Journal of Oral and Maxillofacial Surgery*. 2015;44(6):760-762.
13. Carneiro JT, de Souza Cruz EL, da Silva Tabosa AK, de Moraes PH. Trapezoidal mandibular osteotomy for augmentation of the airway in sleep apnoea. *British Journal of Oral and Maxillofacial Surgery*. 2017;55(8):849-850.
14. Mezzanotte WS, Tangel DJ, White DP. Influence of sleep onset on upper-airway muscle activity in apnea patients versus normal controls. *American Journal of Respiratory and Critical Care Medicine*. 1996;153(6):1880-1887.