

## Original Etiology of Acute and Febrile Neck Pain: Cervical Calcification of Ligamentum Flavum

Ines Mahmoud\*, Rawdha Tekaya, Olfa Saidane, Lilia Chaabouni and Rafik Zouari

9 Avril Boulevard, Charles Nicolle hospital, Department of Rheumatology, Tunis, Tunisie

### Abstract

Calcification of Ligamentum Flavum (CLF) is an uncommon disorder. We present a 56-year-old patient with an acute inflammatory, febrile neck pain and higher value of ESR mimicking spine infection. The imaging investigations conclude for the diagnosis of calcification of the ligamentum flavum. Our observation illustrate the difficulties to differentiate, clinically, infection and calcium pyrophosphate dihydrate deposition in the spine and emphasize the importance of the imaging step in the diagnosis approach. Finally, we draw attention to the efficacy of medical treatment in our case and we discuss the different therapies proposed in the literature.

**Keywords:** Ligamentum flavum; Calcium pyrophosphate dihydrate deposition; Cervical pain

### Introduction

Calcification of ligamentum flavum (CLF) is an uncommon disorder. This condition is probably underestimated and most reported cases were Japanese patients. A pub med search found only one Tunisian case report [1]. The most common presentation of CLF is subacute myelopathy due to spinal cord compression by the calcifications in the absence of precipitating factors. CLF in this case occurred in a Caucasian patient who presented misleading clinical symptoms.

### Case Report

A 56-year-old Tunisian woman was admitted with a history of 10 days acute inflammatory neck pain. She also complained of intermittent fever, chills and neck stiffness, without weight loss or anorexia. No history of any ORL, genital, urinary or respiratory infection was present.

At clinical examination, her temperature was 38.1°C. She had a painful stiff cervical spine when rotating with a markedly restricted neck motion. She had no sensory or motor deficit and no sphincteric involvement, but she had hyperreflexia of all four limbs. Laboratory investigations revealed normal haemogram (leukocytes: 7200) with a raised ESR to 118 mm in 1st hour and a moderate increase of CRP to 11.8 mg/l. Liver and renal function tests were normal and blood cultures were negatives.

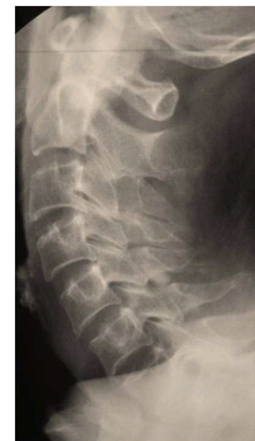The diagnosis of cervical spine infection was highly suspected. Radiographs of the cervical spine didn't show any involvement of the disk nor adjacent vertebrae, but disclosed an oval calcified mass in the interlaminar space C5 and C6 (Figure 1). Magnetic Resonance Imaging (MRI) revealed a low-intensity signal on T1 and T2-weighted sequences in the correspondent interlaminar space (Figure 2) without marrow nor vertebrae signal changes. Computed Tomography (CT) scan confirmed the presence of bilateral oval ligamentum flavum calcifications, localized from C5 to C6 (Figure 3). Plain radiographs of shoulders, wrists, knees and pelvis showed no other calcification. Additional blood analysis showed normal level of calcium, phosphate, vitamin D and parathyroid hormone.

The evolution was rapidly favorable with a colchicine therapy, with disappearance of fever, inflammatory syndrome (ESR decreased to 44mm) and regression of spinal stiffness. Control plain radiographs made two months after the start of the symptoms showed that the

calcifications had almost completely disappeared. Three years after symptom onset, the patient was asymptomatic and cervical radiographs showed no changes.

### Discussion

The present case indicates that CLF can mimic the clinical features of a spinal infection. In the literature, the diagnosis of acute and febrile neck pain due to CLF has been rarely reported [2]. It has been ascribed to a flare of inflammation at the calcified sites. Female over 60 years are particularly prone to this disease. In the early stage, patients complain of occipital headaches, neck pain, or sensory abnormalities in the upper and lower extremities with restricted cervical movements. Neurologically, sensory disturbance of the upper and lower extremities, gait disturbance and tetraparesis are generally present [3]. As in our



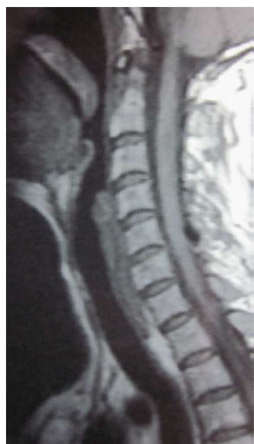**Figure 1:** Radiographs of the cervical spine showing calcification in the interlaminar space C5-C6.

\*Corresponding author: Ines Mahmoud, 9 Avril Boulevard, Charles Nicolle hospital, Department of Rheumatology, Tunis, Tunisie, E-mail: [nefmhd@yahoo.fr](mailto:nefmhd@yahoo.fr)

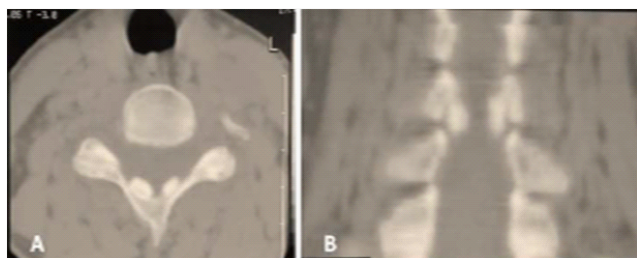
Received November 09, 2011; Accepted April 21, 2012; Published April 22, 2012

**Citation:** Mahmoud I, Tekaya R, Saidane O, Chaabouni L, Zouari R (2012) Original Etiology of Acute and Febrile Neck Pain: Cervical Calcification of Ligamentum Flavum. Orthop Muscul Syst 1:109. doi:10.4172/2161-0533.1000109

**Copyright:** © 2012 Mahmoud I, et al. This is an open-access article distributed under the terms of the Creative Commons Attribution License, which permits unrestricted use, distribution, and reproduction in any medium, provided the original author and source are credited.



**Figure 2:** spinal MRI with Sagittal image showing low-intensity signal on T1 weighted sequences in the inter-laminar space C5-C6.



**Figure 3:** transversal CT and Sagittal CT reconstruction of the cervical spine showing two calcifications in the postero-lateral side of the yellow ligament between C5 and C6.

observation, fever and increased inflammatory laboratory markers have been reported during acute inflammation of ligamentum flavum calcifications [4]. Although plain radiographs of the cervical spine provided the diagnosis in some cases, CT scan is the key diagnostic investigation. MRI is needed when neurologic symptoms are present.

The calcifications are seen as high-attenuation, oval, space-occupying lesions on either side of the midline of the neural arch, in the interval between the laminae of two adjacent vertebrae. They never extend to the posterior facet joints. Sagittal CT reconstructions ensure the diagnosis with 100% specificity. The location of the lesions between the laminae and the acute angles between each lesion and the supra and infrajacent laminae differentiate CLF from ossification of the ligamentum flavum, in which the angles are obtuse. It is important to differentiate ossification of ligamentum flavum from CLF, which is a different pathology also occurring in Japanese individuals [5].

The pathophysiology of CLF remains unclear. Alterations in the ligament matrix with metaplastic or degenerative processes may play a key role [6]. Histopathology of ligamentum flavum calcification shows pyrophosphate and/or hydroxyapatite crystal deposits confirmed by x-ray diffraction analysis [5,6] with the same chemical composition as calcific deposits that occur periarticularly near peripheral joints [7]. The crystalline nature of the disease is admitted in our case by the acute and febrile character of the symptomatology and by the rapid clinical improvement with disappearance of the calcification with colchicine therapy. A spontaneous resorption of ligamentum flavum calcification is reported, authors hypothesize that the calcification resorption was

either caused directly by inflammation, or by a non-inflammatory process with concomitant release of calcium crystals that lead to an acute inflammatory response leading to disappearance of symptoms [4].

Generally, treatment of neurologic symptoms of ligamentum flavum calcifications consists of a surgical laminectomy. Endoscopic surgery can be proposed to treat cervical myelopathy with minimal soft tissue invasion [8]. Asymptomatic calcifications require no intervention [4].

## Conclusion

The ligamentum flavum calcifications should be considered in the differential diagnosis of acute and febrile neck pain. CT is important to confirm the diagnosis. Further, before surgical treatment is considered, in absence of neurological deficits, a medical symptomatic treatment with a closer supervision of symptoms could be proposed first.

## References

1. Guesmi H, Lamouchi T, Mlaiki A, Ksira I, Tlili K et al. (2005) Calcification of the cervical ligamentum flavum. Case report and review of the literature. *Neurochirurgie* 51: 591-594.
2. Sekijima Y, Yoshida T, Ikeda S (2010) CPPD crystal deposition disease of the cervical spine: A common cause of acute neck pain encountered in the neurology department. *J Neuro Sci* 296: 79-82.
3. Yamagami T, Kawano N, Nakano H (2000) Calcification of the cervical ligamentum flavum - case report. *Neurol Med chir (Tokyo)* 40: 234-238.
4. Saliou G, Théaudin M, Grados F, Clavel G, Lehmann P, et al. (2008) Cervicobrachial neuralgia caused by spontaneous resorption of ligamentum flavum calcification. *Rheumatology* 47: 106-107.
5. Cabre P, Pascal-Moussellard H, Kaidomar S, Bucki B, Bardin T, et al. (2001) Six cases of cervical ligamentum flavum calcification in Blacks in the French West Indies. *Joint Bone Spine* 68:158-165.
6. Muthukumar N, Karuppaswamy U (2003) Tumoral calcium pyrophosphate dihydrate deposition disease of the ligamentum flavum. *Neurosurgery* 53: 103-109.
7. Canhao H, Fonseca JE, Leandro MJ, Romeu JC, Pimentão JB, et al. (2001) Cross-sectional study of 50 patients with calcium pyrophosphate dihydrate crystal arthropathy. *Clin Rheumatol* 20: 119-122.
8. Yabuki S, Kikuchi S (2008) Endoscopic surgery for cervical myelopathy due to calcification of the ligamentum flavum. *J Spinal Disord Tech* 21: 518-523.