

Optimal Timing for the Initiation of Enteral Feeding in Neonates with Gastroschisis, Depending on Non-Invasive Doppler Ultrasound Evaluation of Hemodynamics in the Bowel Wall Arteries

OV Teplyakova^{1*}, EA Filippova², YL Podurovskaya², AV Pyregov², VV Zubkov², AA Burov², EI Dorofeeva² and MI Pykov³

¹Resuscitation and Intensive Care Department, Research Centre for Obstetrics, Gynecology and Perinatology, Ministry of Health of the Russian Federation, Moscow, Russia

²Research Centre of Obstetrics, Gynaecology, and Perinatology, Named after Academician V.I. Kulakov, Ministry of Health of the Russian Federation (MOH), Moscow, Russia

³Russian Medical Academy of Postgraduate Education, MOH, Moscow, Russia

*Corresponding author: Teplyakova OV, Surgery, Resuscitation and Intensive Care Department, Research Centre for Obstetrics, Gynecology and Perinatology, Ministry of Health of the Russian Federation, 117997, Moscow, Russia, Tel: +7(909)9943848/+7(495)6806936; E-mail: olga.v.teplyakova@gmail.com

Received date: December 21, 2016; Accepted date: January 28, 2017; Published date: January 31, 2017

Copyright: © 2017 Teplyakova OV, et al. This is an open-access article distributed under the terms of the Creative Commons Attribution License, which permits unrestricted use, distribution, and reproduction in any medium, provided the original author and source are credited.

Abstract

Purpose: The objective of the study is to assess the clinical relevance of ultrasonography evaluation of hemodynamics in the bowel wall arteries for determining the optimal time of the initiation of enteral feeding in neonates with gastroschisis.

Patients and methods: The sample consisted of 28 newborns with gastroschisis. Doppler ultrasonography was used to evaluate hemodynamic patterns in the bowel wall arteries in the pre- and postop periods to determine the optimal time for the initiation of enteral nutrition. Swelling of the bowel wall and indefinite differentiation into layers were observed during the first 2-3 days upon gastroschisis surgery. The blood flow in the intestinal wall arteries was varying in different quadrants, demonstrating a mosaic pattern. Hyperemia, i.e. a dramatic blood flow increase, was documented. The peripheral resistance dropped with RI equal to 0.49-0.54, but there were also areas with definite RI increases up to 0.85. By days 5-6 of life, the intestinal wall still remained moderately thickened. The resistive index (RI) values for the intestinal wall arteries were approaching the norm, ranging from 0.58 to 0.72. By days 7-9 after birth, the bowel loops remained slightly thickened, but already gained a clear differentiation into layers. The peripheral resistance indices were within the normal limits, ranging from 0.62 to 0.67.

Results: In our study RI values based on Doppler evaluation of the intestinal wall hemodynamics were within 0.62-0.67.

Conclusions: The hemodynamic parameters were consistent with clinical characteristics of the normal passage of food through the digestive tract. Thus, a physician can rely on both clinical signs and ultrasonography data while monitoring the bowel function during pre- and postoperative periods to decide on the optimal time for the initiation of enteral feeding.

Keywords: Gastroschisis; Ultrasonography; Hemodynamics in the bowel wall arteries; Resistive index

Abbreviations and Acronyms: RI: Resistive Index.

Introduction

Gastroschisis is a malformation of the anterior abdominal wall with abdominal organs freely protruding due to a periomphalic full-thickness soft tissue defect (Figure 1). The number of newborns with gastroschisis is increasingly growing worldwide, varying from 1 per 1,500 to 1 per 5,000 live births.

Surgical correction techniques are robust and reliable, but perioperative management of gastroschisis cases remains challenging. Gastroschisis accounts for a large share of all surgically correctable congenital defects in neonatal surgery (Figure 2).

The objective of this study is to assess the relevance of ultrasound evaluation of microhemodynamics in the small bowel wall arteries for optimizing the time for the initiation of enteral nutrition in neonates with gastroschisis.

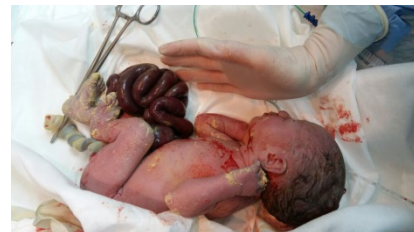

Figure 1: Newborn baby with gastroschisis.

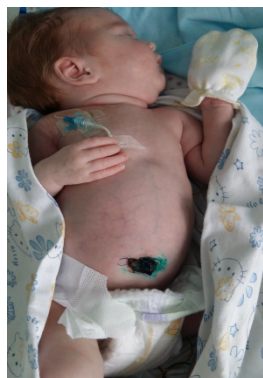

Figure 2: Newborn baby with gastroschisis at the age of 9 days

Background

According to available research data, gastroschisis is the most common congenital ventral wall defect [1-4]. Its average incidence of 1 per 5,000 live births increases 3-fold in young mothers aged less than 20 years: up to 1 case per 1,500 live births [5-8]. According to Castilla et al. in Mexico, its prevalence is higher than in Slovakia, and it tends to be higher in warm climates [8]. The number of newborns with gastroschisis is increasing worldwide [7-12], and gastroschisis accounts for a great share of all surgically correctable congenital defects in neonatal surgery.

Wide use of prenatal ultrasonography enables to detect or suspect fetal gastroschisis starting from 12-17 weeks of gestation. Several studies showed quite high accuracy of prenatal ultrasonography diagnosis of gastroschisis, reaching 90% [12-15]. However, despite early prenatal detection and preparedness of health personnel to handle such cases, the mortality among neonates with gastroschisis varies between 6.5% and 45% in some African and European countries, and reaches up to 95% in some regions, while in the world's reference hospitals, the mortality does not exceed 3-10% [8,16-24].

The greatest reduction in the mortality of neonates with gastroschisis is seen when surgical correction is provided in the same health facilities, i.e. in the maternity hospitals, without transportation to other health centres.

Gastroschisis case management is a challenge for neonatology, including neonatal surgery, resuscitation and intensive care. The growing gastrischisis rates have prompted the development of reliable and effective surgical correction techniques. Meanwhile, there is no uniform treatment protocol for newborns with gastroschisis in the perioperative period [25-27]. Specific challenges exist in pre-op management. In the post-op period, the most important task is to identify the optimal time for the initiation of enteral feeding.

Methods

Patient selection

This study included 28 children with diagnosed gastroschisis, admitted from December 2011 to June 2015 to the Surgical Intensive Care Department of the Research Centre of Obstetrics, Gynecology and Perinatology under the Ministry of Health of the Russian

Federation. This number of patients reflects our hospital specialization in the treatment of children with gastroschisis. Pregnant women with prenatally diagnosed gastroschisis of fetus were admitted to our Center from all over Russia. All the children were diagnosed as gastroschisis cases prenatally at 13-14 weeks of gestation and were born through operative delivery. The Apgar score was 6.7 ± 1.3 points at 1 minute and 7.7 ± 1.3 points at 5 minutes. The sample included 15 boys and 13 girls. The gestational age was 37.5 ± 2.2 weeks. Their mean birth weight and length were $2,735 \pm 137$ g and 48.2 ± 2.3 cm respectively.

The following exclusion criteria were used in this study: Presence of such co-morbidities as intestinal atresia, sepsis, severe birth asphyxia, intraventricular hemorrhage of grade 3-4, or preceding mechanical ventilation, or preceding secondary plastic of the anterior abdominal wall due to the presence of abdomino-visceral disproportion. In all the cases, the parents gave their prior informed consent for ultrasonography examination of the neonates.

Clinical tests and examinations

All the neonates were subjected to thorough clinical and laboratory examinations and tests, including physical examination, monitoring of vital signs, blood count, urinalysis, blood chemistry, coagulation panel, ultrasonography examination of the abdominal cavity and retroperitoneal space.

Siemens ACUSON S2000 (Siemens, Germany, USA) with a 7-14 MHz linear transducer was used for ultrasound examinations. To measure intestinal loops and such parameters as the diameter of the bowel, wall thickness, wall differentiation into layers, presence of peristalsis, intraluminal content and free fluid in the inter-loops spaces, the gray-scale B-mode was used. Color Doppler flow imaging & mapping and pulsed wave Doppler were used for the evaluation of the bowel wall vessels. Maximum systolic velocity, blood flow volume (BFV) and resistive index (RI) were calculated based on the Doppler curve from the bowel wall vessels, vessels of mesenteric root and superior mesenteric artery.

No specific pharmaceuticals were used to prepare patients for ultrasonography examinations. All the neonates were breathing spontaneously after birth. The daily volume of preoperative infusion therapy was 150 ml/kg. A standard anesthesia (general intravenous anesthesia) was used during the surgery; surgical correction was provided within the first 3-4 h after birth in all the neonates. Parenteral nutrition was initiated on the first post-operative day and was followed with its expansion to the total parenteral nutrition (TPN) on post-operative days 4-5. Decompression of the stomach through a nasogastric tube on average lasted for 7 ± 1.3 days after surgery; the gastric volume reached 52 ± 6.2 ml per day. We do not use X-rays in children with gastroschisis because of its low informativeness to make a decision about the beginning of enteral feeding.

Results and Discussion

All the neonates with gastroschisis had incomplete intestinal rotation due to missing typical phases of intestinal rotation and fixation during the prenatal development, occurring outside the abdominal cavity of the fetus, as well as due to the absence of ligament of Treitz's, when the intestine and colon have a common mesentery on a narrow basis.

The malrotation is usually aggravated by compromised blood supply due to impaired vascular anatomy. In a healthy neonate, the superior

mesenteric artery (SMA) forms a 40-50 degree angle with the abdominal aorta and travels in a straight-line manner (Figure 3). In gastroschisis cases, the SMA is not only tortuous, but arises from the abdominal aorta at an angle of 80-90 degrees (Figure 4). No doubt, such anatomical features impair the blood flow in the main trunk and in the branches, thus, habitual hemodynamic standards are not applicable to cases with abnormal vascular anatomy. Nevertheless, in gastroschisis cases, SMA hemodynamics was not significantly different from normal parameters, or significantly fluctuating-starting from the first hours of life and in the long-term, in contrast to hemodynamics in small arteries of the intestinal wall.

neonatal practice [30-32]. In all reported studies, the authors evaluated the vascular reserve of large vessels, regretting that a direct assessment of small arteries was not possible without the use of a contrast medium [33,34]. Available publications also provide some information about dopplerographic criteria for evaluation of the intestinal wall in children with Crohn's disease [35-37]. However, the above-mentioned abnormal behavior of SMA in gastroschisis cases and specifics of hemodynamic patterns in neonates make all published data inapplicable to the current study.

However, in neonates with gastroschisis and bowel paresis, both Trans and intra-abdominal examinations are feasible with due regard to the structural defects of the abdominal wall. Such examinations usually provide identical data with a minimal bias.

The early postoperative period provides the best acoustic environment for US B-mode examination and detailed dopplerographic assessment (Figure 5), when peristalsis is partially or totally suppressed, intestinal wall is thickened, intraluminal gas-if present-is found in minimal amounts and free fluid is seen in the abdominal cavity.

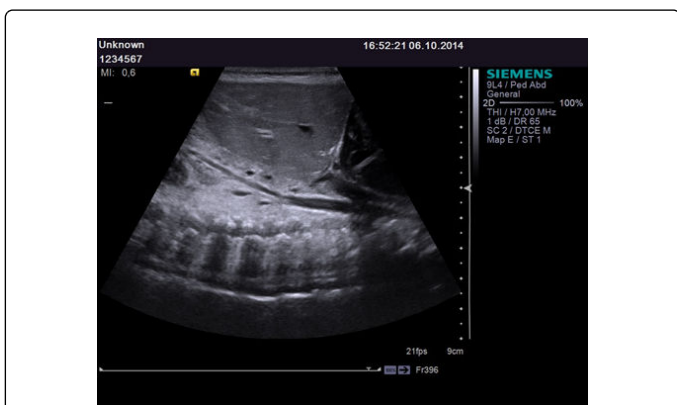


Figure 3: SMA trajectory echogram of a healthy neonate. Transabdominal examination, using a linear 14 MHz transducer. Longitudinal scanning detected the superior mesenteric artery, arising from the abdominal aorta in a typical location at 45-60° angle with a straight linear trajectory.

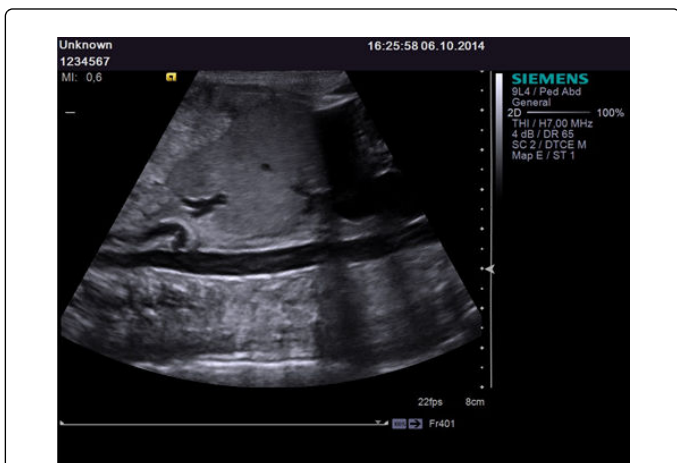


Figure 4: SMA trajectory echogram of a neonate with gastroschisis. In gastroschisis cases with incomplete intestinal rotation, longitudinal scanning detected higher origination of the superior mesenteric artery from the abdominal aorta at 80-90° angles with a coiled course.

Attempts to assess intra-op bowel wall micro-hemodynamics are reported in adult population and adolescents after failures with trans-abdominal approaches [28,29]. In addition, such measurements usually require using a contrast substance (dye), which is unacceptable in

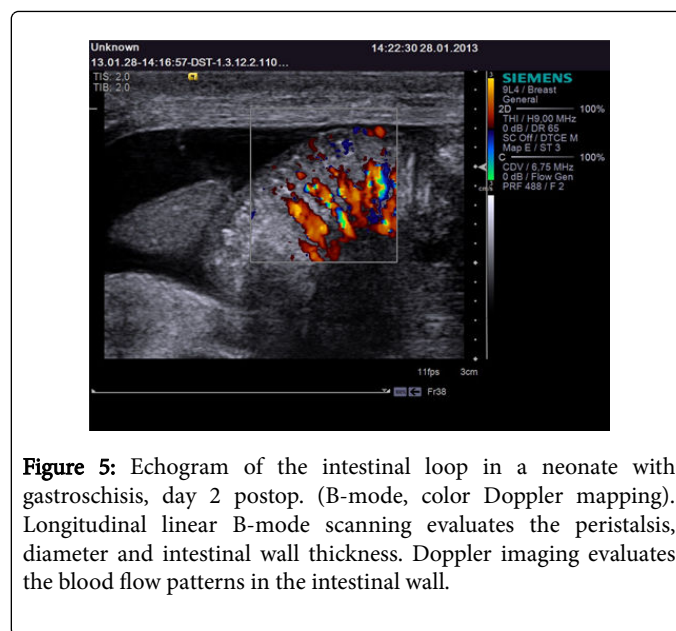


Figure 5: Echogram of the intestinal loop in a neonate with gastroschisis, day 2 postop. (B-mode, color Doppler mapping). Longitudinal linear B-mode scanning evaluates the peristalsis, diameter and intestinal wall thickness. Doppler imaging evaluates the blood flow patterns in the intestinal wall.

On the first 2-3 days after the operation, the bowel wall is swollen and thickened and differentiation into layers is unreadable in a newborn with gastroschisis. The bowel loops are deflated and sticking together or filled with a thick hypoechoic chyme and minor amount of intraluminal gas. The peristalsis is dramatically reduced or even not observed in some areas.

A considerable amount of free fluid is accumulated in all sloping areas of the abdominal cavity and in the inter-loop spaces. The blood flow in the intestinal wall is varying by quadrants, showing a mosaic pattern, and pronounced hyperemia (engorgement) of the bowel wall vessels.

The peripheral resistance parameters drop to 0.49-0.54 RI values, but there are also areas with noticeable RI increase up to 0.85 (Figure 6). At this stage, it is crucial to explore all segments of the bowel to ensure that no ischemic areas with a sharp decline or even absence of the blood flow should be missed.

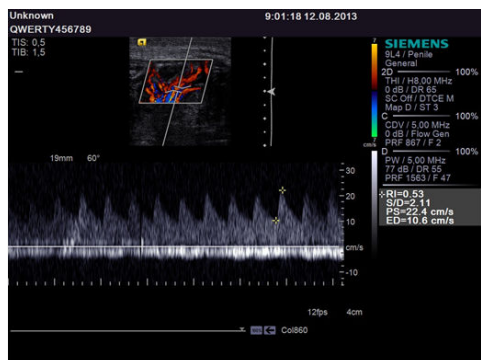


Figure 6: Echogram of the intestinal loop in a neonate, day 2 postop (pulsed-wave Doppler scanning). Evaluation of peripheral resistance in the bowel wall vessels.

By days 5-6 after birth, the intestinal wall remains moderately thickened. The bowel loops look common, not distended. The intraluminal content is thick with moderate amount of gas.

Peristalsis is evident in all the segments. Small amounts of free fluid are still visible in the inter-loops spaces. The RI in bowel wall vessels is approaching the normal values, ranging between 0.58-0.72 (Figure 7).

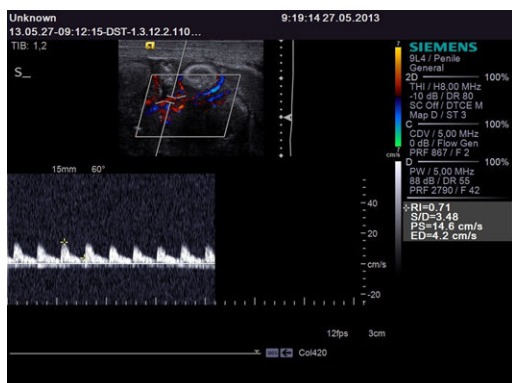


Figure 7: Echogram of the intestinal loop in a neonate, day 5 postop (pulsed-wave Doppler scanning). RI is approaching the normal values.

By days 7-9 after birth, the bowel loops are slightly thickened, with clear differentiation into layers. Peristalsis is present in all the segments.

The amount of intraluminal gas increased, interfering seriously with the assessment of the blood flow in the intestinal wall.

Traces of free liquid are seen in inter-loops spaces. Indicators of peripheral resistance are within normal ranges 0.62-0.67 (Figure 8) [37].

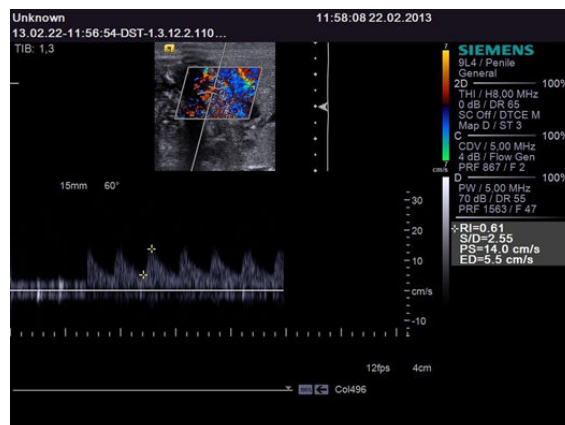


Figure 8: Echogram of the intestinal loop in a neonate, day 7 postop (pulsed-wave Doppler scanning).

Conclusions

Some issues remain unresolved in the nursing of newborns with gastroschisis despite the availability of well-established surgical correction techniques for this congenital malformation. Better outcomes are seen in settings where surgery is available in the maternity home, without the need to move the patient to another hospital, and with after-surgery monitoring provided before the patient is discharged.

Timely initiation of enteral nutrition is of great importance because favorable clinical outcomes and prospects for further adaptation of neonates with operated gastroschisis are largely dependent on adequate and timely enteral feeding.

The results of our study are consistent with reported data from Sjekavica et al. and Esteban et al. investigating the intestinal wall microhemodynamics in Crohn's disease [28,36,37]. The reported RI values based on Doppler evaluation of the intestinal wall hemodynamics during remission and in the control group were within 0.65-0.67 in these two studies. In our study, this range is somewhat broader: 0.62-0.67, which could be attributed to the functioning of such fetal communications in the neonatal period as the patent ductus arteriosus and ductus venosus Arantii. The results enable us to conclude that normalization of the intestinal wall blood flow should be viewed as the signal to initiate enteral feeding to avoid inappropriate burdens on the digestive tract. In our sample, enteral feeding was initiated in all the patients, on the average, in 8-9 days after surgery.

The hemodynamic parameters are consistent with the clinical characteristics, testifying to the normal passage of food through the digestive tract. Thus, a physician can rely on both clinical signs and ultrasonography data while monitoring the bowel function during pre- and postoperative periods to identify the optimal time for the initiation of enteral feeding.

Consent

The patients' parents gave their written informed consent for publication of this study and any accompanying images. A copy of the written consent is available for review by the Editor of this Journal.

Competing Interests

The authors declare that they have no competing interests.

Authors' Contributions

E.A. Filippova conceived the study and initiated its publication, performed abdominal ultrasonography and Doppler imaging in the neonates with gastroschisis at all the stages of the treatment, and provided pictures for the paper from her own archive.

O.V. Teplyakova and A.A. Burov were responsible for therapeutic management and stabilization of all the newborns with gastroschisis at the delivery room, for peri-op management and anesthetic support.

O.V. Teplyakova designed the study, coordinated it, and was responsible for statistical data processing and preparation of the text.

Yu.L. Podurovskaya and E.I. Dorofeeva provided the surgical treatment of the neonates with gastroschisis as well as nursing care upon completion of the intensive care. They participated in formatting the study design.

A.V. Pyregov led the work, supervised the study and revised the paper.

V.V. Zubkov led the work and supervised the study.

M.I. Pykov supervised the analysis.

All the authors read and approved the final version of the article.

References

- Molik KA, Gingalewski CA, West KW, Rescorla FJ, Scherer LR, et al. (2001) Gastroschisis: a plea for risk categorization. *J Pediatr Surg* 36: 51-55.
- Skarsgard E, Claydon J, Bouchard S, Kim PC, Lee SK, et al. (2008) Canadian Pediatric Surgical Network: a population-based pediatric surgery network and database for analyzing surgical birth defects. The first 100 cases of gastroschisis. *J Pediatr Surg* 43: 30-34.
- Vu LT, Nobuhara KK, Laurent C, Shaw GM (2008) Increasing prevalence of gastroschisis: population-based study in California. *J Pediatr* 152: 807-811.
- Keys C, Drewett M, Burge DM (2008) Gastroschisis: the cost of an epidemic. *J Pediatr Surg* 43: 654-657.
- Baer RJ, Chambers CD, Jones KL, Shew SB, MacKenzie TC, et al. (2015) Maternal factors associated with the occurrence of gastroschisis. *Am J Med Genet A* 167: 1534-1541.
- Loane M, Dolk H, Bradbury I, EUROCAT Working Group (2007) Increasing prevalence of gastroschisis in Europe 1980-2002: a phenomenon restricted to younger mothers? *Paediatr Perinat Epidemiol* 21: 363-369.
- Grant NH, Dorling J, Thornton JG (2013) Elective preterm birth for fetal gastroschisis. *Cochrane Database Syst Rev* : CD009394.
- Castilla E, Mastroiacovo P, Oriol IM (2008) Gastroschisis: international epidemiology and public health perspectives. *Am J Med Genet C Semin Med Genet* 148C: 162-179.
- Tarca E, Ciongradi I, Aprodu SG (2015) Birth Weight, Compromised Bowel and Sepsis are the Main Variables Significantly Influencing Outcome in Gastroschisis. *Chirurgia (Bucur)* 110: 151-156.
- Kilby MD (2006) The incidence of gastroschisis. *BMJ* 332: 250-251.
- Di Tanna GL, Rosano A, Mastroiacovo P (2002) Prevalence of gastroschisis at birth: retrospective study. *BMJ* 325: 1389-1390.
- Salihu HMI, Pierre-Louis BJ, Druschel CM, Kirby RS (2003) Omphalocele and gastroschisis in the State of New York, 1992-1999. *Birth Defects Res A Clin Mol Teratol* 67: 630-636.
- Garne E, Loane M, Dolk H, De Vigan C, Scarano G, et al. (2005) Prenatal diagnosis of severe structural congenital malformations in Europe. *Ultrasound Obstet Gynecol* 25: 6-11.
- Holland AJ, Walker K, Badawi N (2010) Gastroschisis: an update. *Pediatr Surg Int* 26: 871-878.
- Pakdaman R, Woodward PJ, Kennedy A (2015) Complex abdominal wall defects: appearances at prenatal imaging. *Radiographics* 35: 636-649.
- Bradnock TJ, Marven S, Owen A, Johnson P, Kurinczuk JJ (2011) Gastroschisis: one year outcomes from national cohort study. *BMJ* 343: d6749.
- Baerg J, Kaban G, Tonita J, Pahwa P, Reid D (2003) Gastroschisis: A sixteen-year review. *J Pediatr Surg* 38: 771-774.
- Gamba P, Midrio P2 (2014) Abdominal wall defects: prenatal diagnosis, newborn management, and long-term outcomes. *Semin Pediatr Surg* 23: 283-290.
- Apfeld J, Wren S, Macheke N, Mbuwayesango B, Bruzoni M, et al. (2015) Infant, maternal, and geographic factors influencing gastroschisis related mortality in Zimbabwe. *Surgery* 158: 1475-1480.
- Carvalho N, Helfer T, Serni P, Terasaka O, Boute T, et al. (2015) Postnatal outcomes of infants with gastroschisis: a 5-year follow-up in a tertiary referral center in Brazil. *J Matern Fetal Neonatal Med* 9: 1-5.
- Wright NJ, Zani A, Ade-Ajayi N (2015) Epidemiology, management and outcome of gastroschisis in Sub-Saharan Africa: Results of an international survey. *Afr J Paediatr Surg* 12: 1-6.
- Nembhard WN, Waller DK, Sever LE, Canfield MA (2001) Patterns of first-year survival among infants with selected congenital anomalies in Texas, 1995-1997. *Teratology* 64: 267-275.
- Sekabira J, Hadley GP (2009) Gastroschisis: a third world perspective. *Pediatr Surg Int* 25: 327-329.
- Feldkamp M, Carey J, Sadler T (2007) Development of gastroschisis: Review of hypotheses, a novel hypothesis, and implications for research Feldkamp. *American Journal of Medical Genetics Part A* 143A: 639-652.
- Abdullah F, Arnold MA, Nabaweesi R, Fischer AC, Colombani PM, et al. (2007) Gastroschisis in the United States 1988-2003: analysis and risk categorization of 4344 patients. *J Perinatol* 27: 50-55.
- Aldrink J, Caniano D, Nwomeh B (2012) Variability in gastroschisis management: a survey of North American pediatric surgery training programs. *J Surg Res* 176: 159-163.
- Lusk L, Brown E, Overcash R, Grogan T, Keller R, et al. (2014) University of California Fetal Consortium. Multi-institutional practice patterns and outcomes in uncomplicated gastroschisis: a report from the University of California Fetal Consortium (UCfC). *J Pediatr Surg* 49: 1782-1786.
- Esteban JM, Maldonado L, Sanchiz V, Minguez M, Benages A (2001) Activity of Crohn's disease assessed by colour Doppler ultrasound analysis of the affected loops. *Eur Radiol* 11: 1423-1428.
- Yekeler E, Danalioglu A, Movasseghi B, Yilmaz S, Karaca C, et al. (2005) Crohn disease activity evaluated by Doppler ultrasonography of the superior mesenteric artery and the affected small-bowel segments. *J Ultrasound Med* 24: 59-65.
- De Pascale A, Garofalo G, Perna M, Priola S, Fava C (2006) Contrast-enhanced ultrasonography in Crohn's disease. *Radiol Med* 111: 539-550.
- Rapaccini GL, Pompili M, Orefice R, Covino M, Riccardi L, et al. (2004) Contrast-enhanced power doppler of the intestinal wall in the evaluation of patients with Crohn disease. *Scand J Gastroenterol* 39: 188-194.
- Piscaglia F, Nolsoe C, Dietrich C, Cosgrove D, Gilja O, et al. (2011) The EFSUMB guidelines and recommendations on the clinical practice of contrast-enhanced ultrasound (CEUS): Update 2011 on nonhepatic applications. *Ultraschall in Med* 33: 33-59.
- Huang BY, Warshauer DM (2003) Adult intussusception: diagnosis and clinical relevance. *Radiol Clin North Am* 41: 1137-1151.
- Boyle MJ, Arkell LJ, Williams JT (1993) Ultrasonic diagnosis of adult intussusception. *Am J Gastroenterol* 88: 617-618.
- Abuhamad A, Mari G, Cortina R, Croitoru D, Evans A (1997) Superior mesenteric artery Doppler velocimetry and ultrasonographic assessment

Citation: Teplyakova OV, Filippova EA, Filippova YL, Pyregov AV, Zubkov VV, et al. (2017) Optimal Timing for the Initiation of Enteral Feeding in Neonates with Gastroschisis, Depending on Non-Invasive Doppler Ultrasound Evaluation of Hemodynamics in the Bowel Wall Arteries. *J Anesth Clin Res* 8: 701. doi:[10.4172/2155-6148.1000701](https://doi.org/10.4172/2155-6148.1000701)

-
- of fetal bowel in gastroschisis: a prospective longitudinal study. *Am J Obstet Gynecol* 176: 985-990.
36. Sjekavica I, Barbaric-Babic V, Šunjara V, Kralik M, Senecic-Cala I, et al. (2013) Resistance index in mural arteries of thickened bowel wall: predictive value for Crohn disease activity assessment in pediatric patients. *Wien Klin Wochenschr* 125: 254-260.
37. Sjekavica I, Barbaric-Babic V, Kralik M, Krznaric Z, Stern-Padovan R (2009) High resolution B-mode and Doppler ultrasound in diagnostic evaluation of Crohn's disease. *Lijec Vjesn* 131: 18-21.