

Non-Wolf Parkinson White (WPW) Preexcitation Syndrome

Fayez A Bokhari*

King Fahd Armed Forces Hospital, Jeddah, Saudi Arabia

Abstract

Mahaim (M) accessory pathway (AP) is an endocardia atrioventricular (AV) node-like structures that connect the atrium to the ventricle. M fibers were first described as accessory connections taking off from the fascicular system to the right ventricle called fasciculoventricular (FV) or from the AV node to the right ventricle called nodoventricular fibers (NV) or connecting the AV node to the fascicles called nodo-fascicular (NF). However, the majority, if not all, of Mahaim AP are atriofascicular connecting the atrium to the fascicular system. We describe two cases with non-WPW accessory pathways and their successful ablation along with a literature review.

Keywords: Mahaim; Accessory pathway; Atriofascicular; Mapping; Ablation; WPW

Introduction

The objective of this review article is to describe the electro physiologic features, diagnosis and treatment of Mahaim accessory pathway. Mahaim (M) accessory pathway (AP) is a rare endocardial atrioventricular (AV) node-like structures that connect the atrium (usually the right anterolateral or posterolateral atrium at the tricuspid annulus) to the ventricle (usually the distal right bundle branch) via a long and electrically insulated tract. Earlier studies suggested that these fibers arise from the AV node and insert into or near the right bundle branch. M fibers were first described as accessory connections taking off from the fascicular system to the right ventricle called fasciculoventricular (FV) or from the AV node to the right ventricle called nodoventricular fibers (NV) or connecting the AV node to the fascicles called nodo-fascicular (NF). However, more recent observations [1-4] have suggested that the majority, if not all, of Mahaim AP are atriofascicular connecting the atrium to the fascicular system.

Gallagher et al. [5] wrote more than 30 years ago that “the role of Mahaim fibers in the genesis of cardiac arrhythmias in man has been controversial since they were first described” in the late 1930’s by Dr. Ivan Mahaim [6]. Anderson et al. [7] proposed 2 varieties of NV fibers, one that arises from the transitional zone of the AV junction and the other which arises from the deep, compact nodal portion of the AV junction. An important observation was made in 1978 by Becker et al. [8] who found an accessory node associated with a bundle of specialized fibers measuring 1 cm and coursing through the right ventricle, mimicking a second AV conduction system located on the lateral tricuspid annulus. Others subsequently verified intraoperatively and learned by ablation that patients with clinical features thought to be typical of nodoventricular Mahaim conduction, had atriofascicular pathways linking the atrium at the annular antero or postero-lateral tricuspid ring to the distal conduction system of the right ventricle [9-13]. On the basis of evidence to date [1], it is not possible to be definitive about the existence of nodofascicular or nodoventricular fibers. However, it is appropriate to say that the great majority of patients presenting with decremental pathways (AV interval prolongs with faster atrial pacing) with a long conduction time (long AV interval) and relatively short VA interval have atriofascicular AP with Mahaim properties. Unlike Mahaim AP the A to V interval is usually very short in true AV accessory pathway during antidromic tachycardia.

Diagnostic features of Mahaim Fibers [1-4, 11-24]

The first case is a 35 year-old man who has had frequent highly

symptomatic palpitations associated with shortness of breath. His initial ECG is normal. The second case is 20 year old woman with one documented episode of wide complex regular tachycardia with LBBB morphology similar to the induced tachycardia in (Figure 1) that required electrical cardio version who was referred for an electrophysiological study and ablation. ECG in sinus rhythm is also normal. Both patients underwent successful radiofrequency ablation with no recurrence for more than two years. Essential diagnostic features are summarized as follows:

Preexcitation on the routine 12-lead ECG is absent to minimal with QRS duration 110-120 milliseconds with slight slurring of the initial forces suggestive of delta wave. PR interval is either normal or short. Sometimes the only clue is absence of septal Q wave in leads V5 or V6 [18]. Variable preexcitation is seen with atriofascicular fibers (because of fusion of impulses going down AV node and Mahaim fibers) but not with Fasciculoventricular (FV) Fibers (i.e. the QRS width is constant in FV Fibers). FV pathways are rare and best described by Gallagher et al. [5] with the following characteristics: significant decrement with faster pacing is not observed, the His-ventricular interval is short and constant, there is little or no variance in a minimally pre-excited pattern and the pathway does not participate actively in clinical tachycardia, and should be left alone.

The preexcited pattern elicited by pacing or during pre-excited antegrade AVRT tachycardia (Figure 1) has left bundle branch block morphology and generally a leftward axis indicating an insertion in the inferior posterior septal part of RV at or near the right ventricle apex. The reciprocating tachycardia has the same left bundle branch block preexcitation morphology. The right bundle branch or RV local electrogram precedes His bundle activation during antegrade pre-excitation. During antidromic tachycardia adenosine causes prolongation of conduction over the pathway and eventual block, terminating tachycardia (Figure 2). Adenosine 12 mg IV twice should be

*Corresponding author: Dr. Fayez A Bokhari, MD, King Fahd Armed Forces Hospital, Jeddah, Saudi Arabia, Tel: +966 535663111 E-mail: fayezabokhari@yahoo.com

Received July 28, 2015; Accepted August 17, 2015; Published August 26, 2015

Citation: Bokhari FA (2015) Non-Wolf Parkinson White (WPW) Preexcitation Syndrome. Angiol 3: 152. doi:10.4172/2329-9495.1000152

Copyright: © 2015 Bokhari FA. This is an open-access article distributed under the terms of the Creative Commons Attribution License, which permits unrestricted use, distribution, and reproduction in any medium, provided the original author and source are credited.

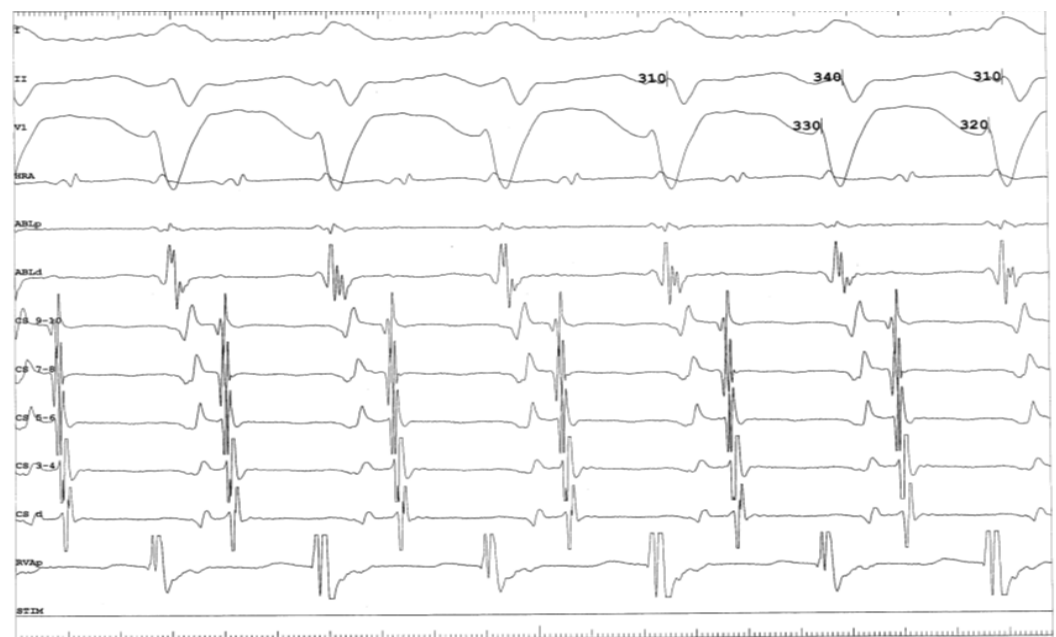


Figure 1: AVRT tachycardia with long AV (PR) with antegrade conduction over the AP and relatively short VA with nodal retrograde activation in a patient with Mahaim accessory Pathway. Ablation catheter positioned at His.

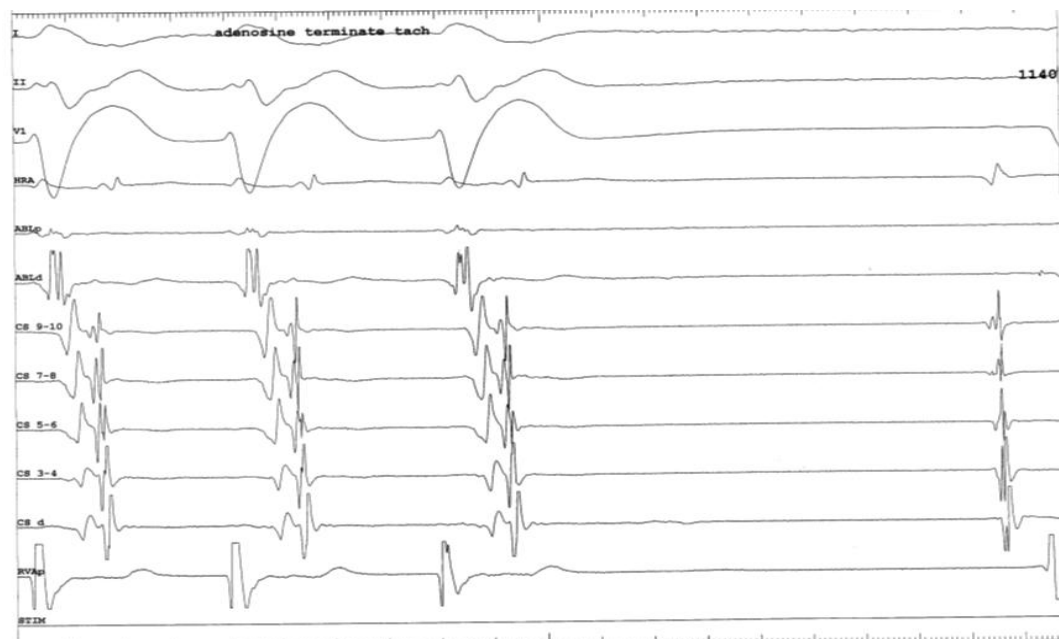
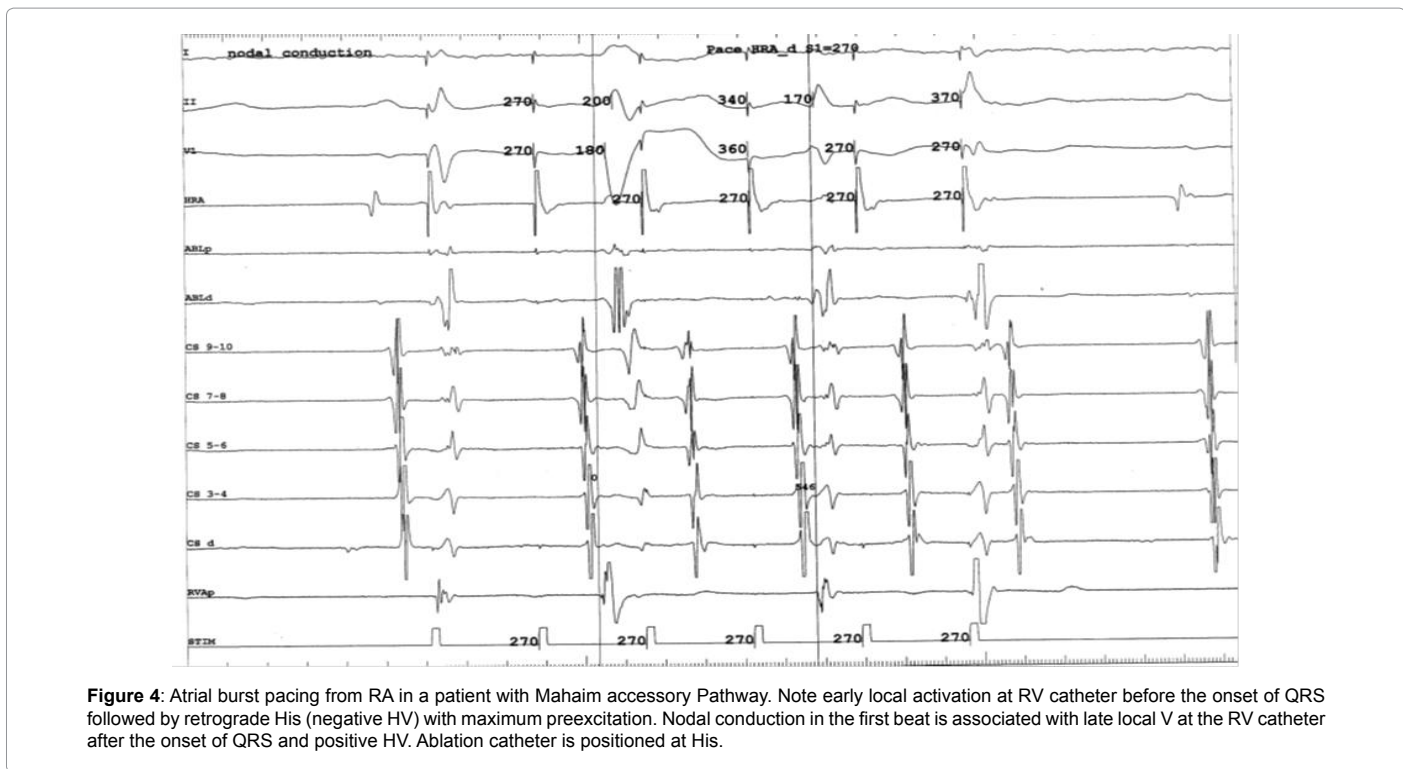
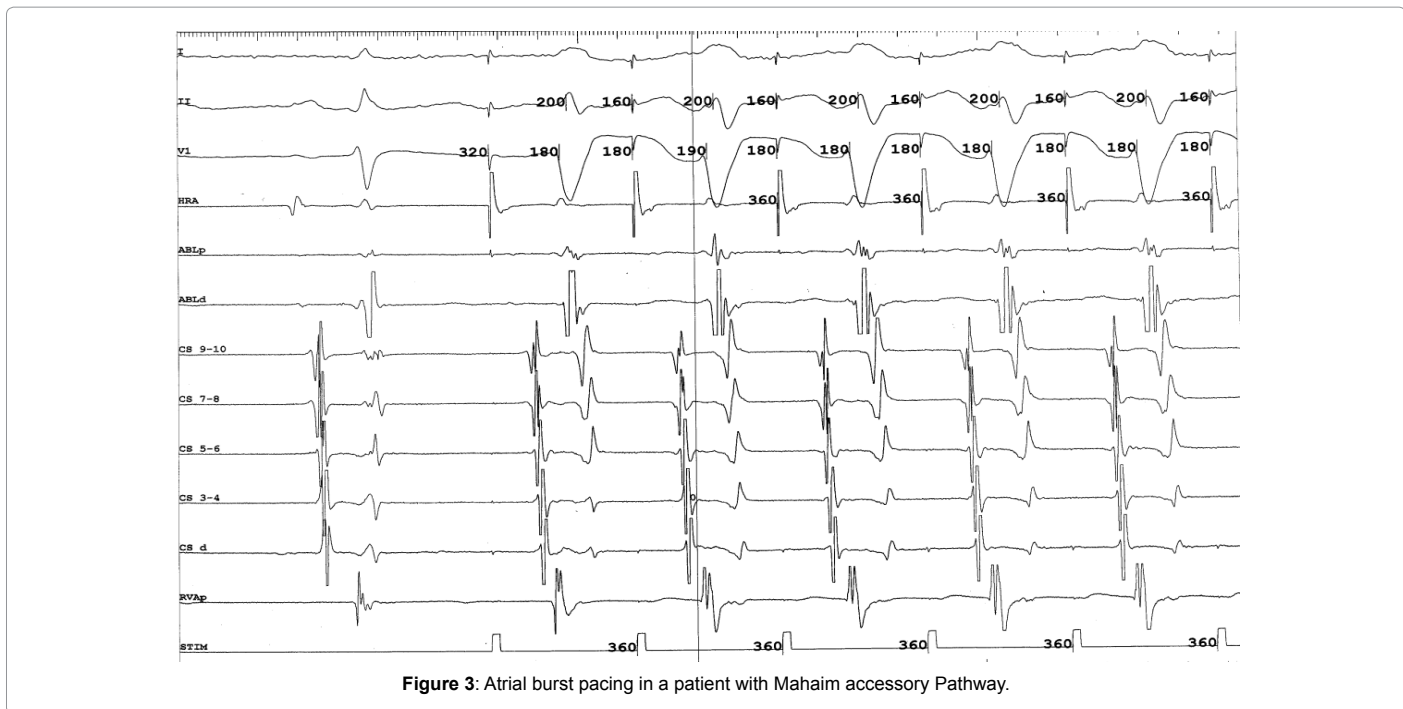


Figure 2: Adenosine 12 mg IV terminates tachycardia by blocking the AP in a patient with Mahaim accessory Pathway.

given during wide complex regular tachycardia in order to differentiate VT from latent Mahaim tachycardia which does not cause preexcitation during SR or with atrial pacing but supports antegrade AV reentry tachycardia; PAC after septal A technique which will be explained later is also helpful in this situation.

The pathway exhibits rate-dependent or “decremental” conduction with prolongation of the A-to-V interval with faster atrial extrastimuli or incremental atrial pacing. Pacing from right atrial sites with progressively

faster coupling intervals (burst or programmed) provides more preexcitation (variable fusion) with advancement of the His signal toward the QRS or even after the onset of QRS (Figures 3-6). This variable fusion is not seen in FV fibers during SR or during atrial pacing (ie faster burst A pacing increases AH but HV and QRS width stay constant; Pacing from different sites from the atrium either close or far from the AP or even from the His location gives you the same degree of preexcitation with FV Fibers). Pacing from his location in atriofascicular fiber results in loss of pre-excitation and pacing from different locations results in variable degree of pre-excitation.



Retrograde conduction over the pathway is usually (may be always) absent. It conducts retrogradely over RBBB, then activate his and AV node retrogradely (retrograde His sometimes can be seen during tachycardia in the his region) (Figure 7).

The most commonly observed clinical tachycardia - which can be induced reliably using atrial pacing- is an antidromic AV reentrant tachycardia proceeding antegradely over the atriofascicular pathway (with long AV

and retrogradely over the normal AV conduction system (short VA) . During fully preexcited QRS complexes, the local ventricular potential at the tricuspid annulus or His (retrograde activation) come after the onset of the QRS complex. The RV local electrogram comes before the onset of QRS (Figures 4 and 8) and before his electrogram consistent with earliest local ventricular activation occurring at the apical region of the right ventricular free wall.

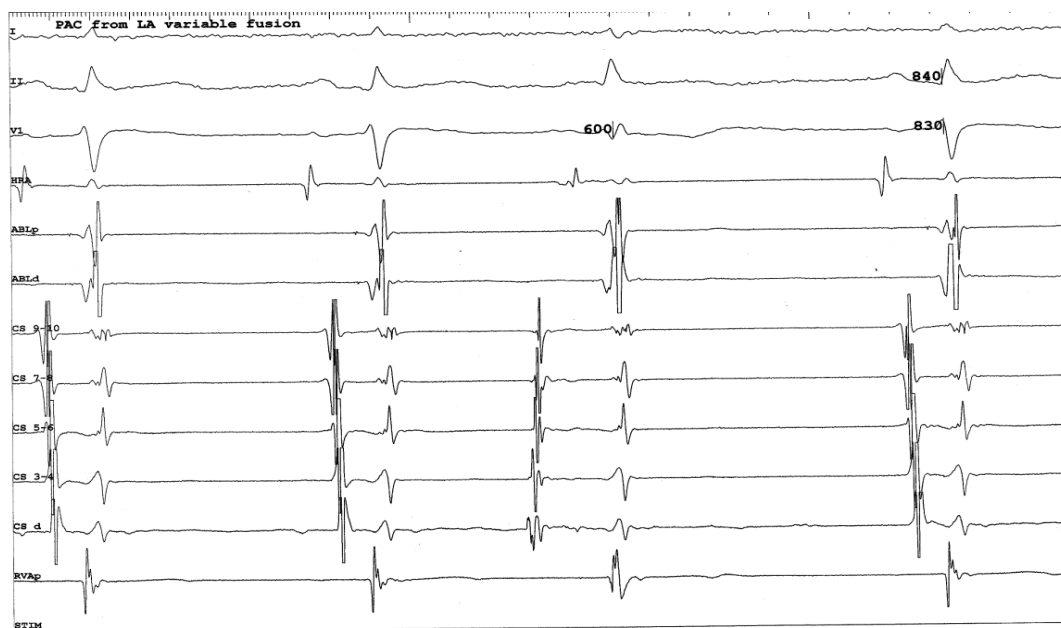


Figure 5: Variable preexcitation during sinus rhythm in a patient with Mahaim atriofascicular accessory Pathway. Note less preexcitation from LA PAC.

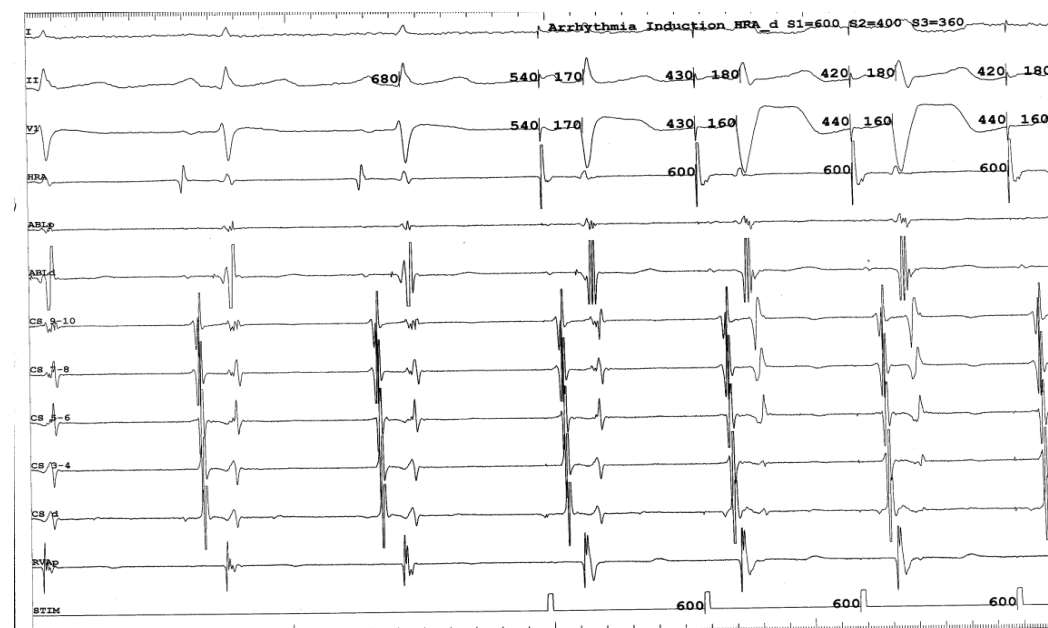


Figure 6: Atrial burst pacing in a patient with Mahaim atriofascicular accessory Pathway. Note variable fusion with advancement of the His signal after the QRS. Ablation catheter is positioned at His.

The final step before ablation is to assess the role of the accessory pathway in the tachycardia circuit (i.e. whether active or bystander). It can be done by delivering single lateral right atrial extra stimuli (PAC) after the septal A during pre-excited AVRT tachycardia, timed not to affect the AV node region: Advancement of the next V with shorter next VV without affecting the activation sequence establishes the diagnosis of an extranodal accessory pathway and the active participation of Mahaim fiber in the tachycardia circuit (Figure 9). Mc Clelland et al. could successfully advance QRS activation with late right atrial extra

stimuli in 22 of 23 patients with atriofascicular tachycardia. Right atrial extra stimuli -PAC- after the septal (His) A or on His when His is refractory (PAC did not penetrate the AV node) advances the timing of the next V (without changing QRS morphology or ventricular or retrograde activation sequence) indicating active participation of the atriofascicular Mahaim pathway in the tachycardia circuit. Another maneuver proving AP participation in AVRT is by producing catheter-induced RBBB. RBBB lengthens the circuit path, with an increase in ventriculoatrial time. Preexcited A-V nodal reentry as well as antidromic

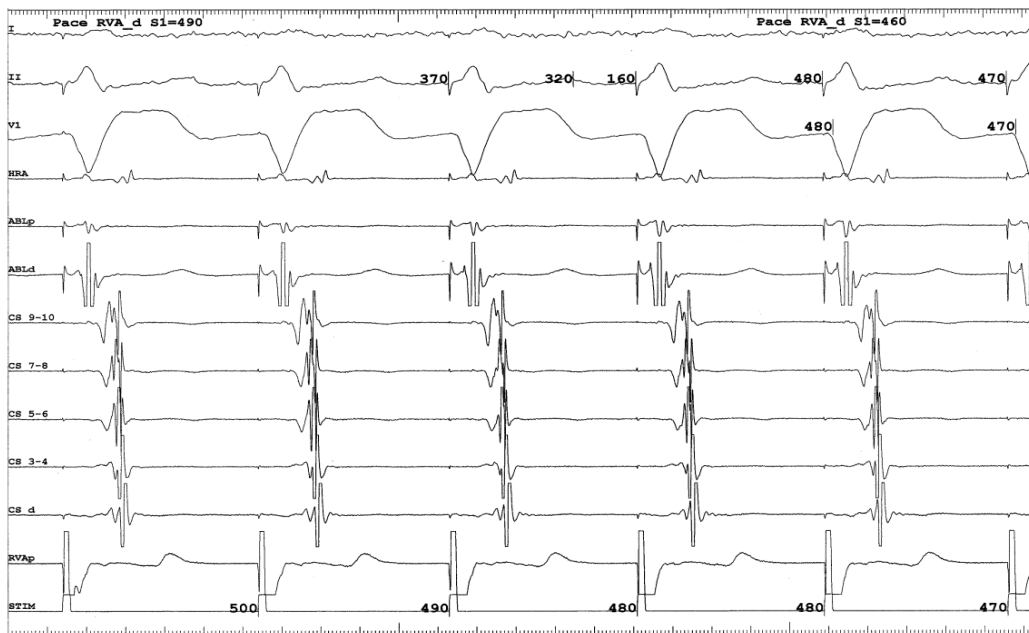


Figure 7: Ventricular pacing in a patient with Mahaim accessory Pathway. Nodal retrograde conduction seen.

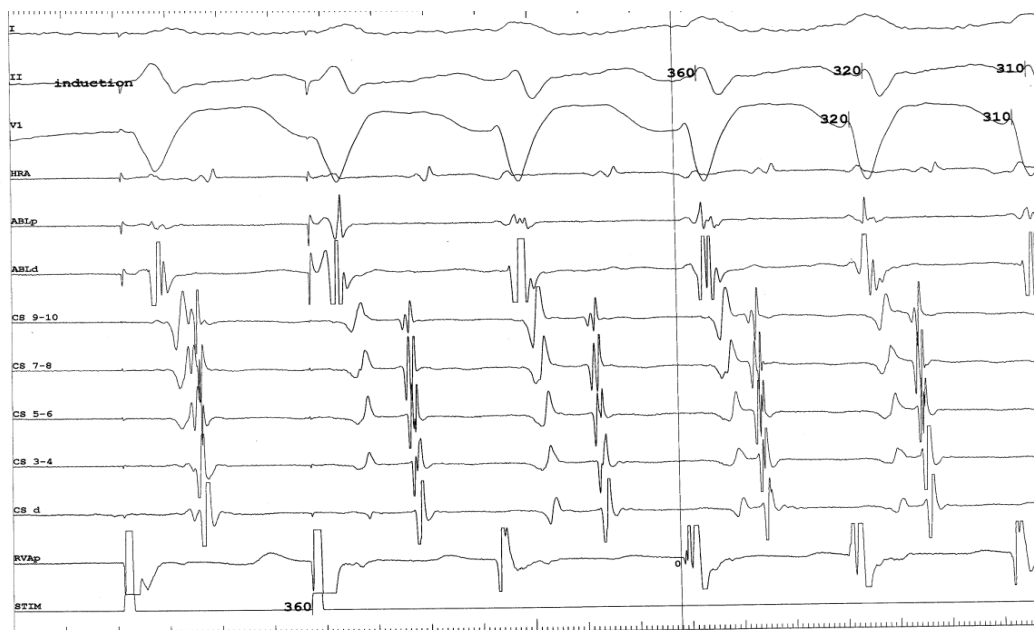


Figure 8: Antidromic tachycardia started after programmed atrial Pacing in a patient with Mahaim accessory Pathway Note early local RV signal before the beginning of the QRS.

tachycardia with retrograde conduction through another AP would not be affected.

Ablation techniques

Ablation of Mahaim AP is usually difficult and may take several hours because of the difficulty in finding the Mahaim potential and the fact that it cannot be mapped easily using the conventional techniques. Retrograde activation is nodal and therefore mapping during ventricular pacing is not useful.

Associated typical or atypical AV node reentry and other accessory AV pathways are observed relatively frequently. Slow pathway or midseptal ablation around CS (targeting probable midseptal NV AP) may be considered [4] in patients with dual AV Node physiology if no Mahaim potential can be found at the tricuspid annulus or after failed attempts to ablate at the tricuspid annulus. Possible clues [4] as to the presence of a true nodoventricular fiber arising from the slow septal AV Node area was the inability of a premature atrial stimulus to advance the ventricle and the presence of dual A-V nodal pathways.

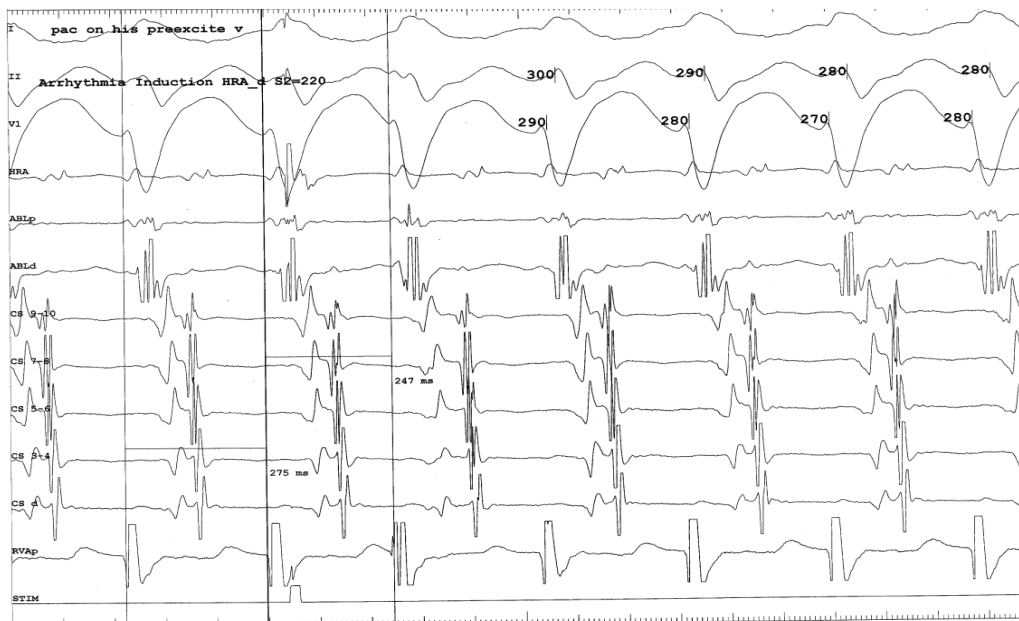
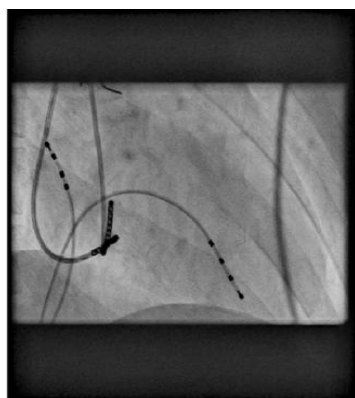
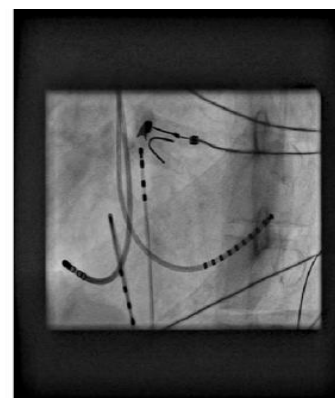


Figure 9: Right atrial extrastimuli induced after the septal atrial electrogram advances the next preexcited ventricular electrogram and subsequent atrial electrogram with the same retrograde activation sequence in a patient with Mahaim AP.



xxx: 2036454847
7/21/99
M
1/15/2012 12:38:53 PM
BOKHARI Fayerz "Dr"
King Fahad Armed Forces Hospital

A: RAD: 34.3, CRAN: 0.0
Scene: 1 of 18
Frame: 2 of 2



xxx: 2036454847
7/21/99
M
1/15/2012 12:38:53 PM
BOKHARI Fayerz "Dr"
King Fahad Armed Forces Hospital

B: LAO: 44.5, CRAN: 0.4
Scene: 1 of 18
Frame: 2 of 2

Figure 10: X-ray in the RAO and LAO views demonstrating ablation catheter inserted via the right internal jugular vein and positioned at the lateral tricuspid annulus beneath leaflets during Mahaim Atriofascicular ablation. Other catheters placed in the high right atrium, RV Apex and coronary sinus.

The original observation of McClelland et al. [2] that an AP potential similar to a his potential can be recorded at the tricuspid AV ring provides the best "target" for ablation. This atriofascicular Mahaim potential can invariably be located at the tricuspid ring even if preexcitation is not evident on the surface ECG. Mahaim accessory pathway discrete high frequency potential (similar to his electrogram) can be recorded in the anterolateral, lateral or posterolateral tricuspid annulus during sinus rhythm or during tachycardia with A- AP potential-V signals separated by isoelectric intervals of 60-80 ms each). These pathways could be ablated at any point along their length but were generally ablated more readily at the AV ring near their origin where Mahaim potential could be seen. Halo catheter positioned along the ventricular aspect (A: V ratio less than 1) of the tricuspid annulus with tip in coronary sinus

can be used to find the Mahaim potential. Then the ablation catheter is used for further detailed mapping. Radiofrequency ablation is applied during right atrial pacing or antidromic AV reentrant tachycardia to verify the loss of AP conduction or preexcitation online. The most stable ablation position is obtained via the right internal jugular or right subclavian venous approach (Figure 10) targeting the lateral tricuspid annulus just beneath the tricuspid leaflets. However the femoral approach (Figure 11) can be also used preferably with a long SL or SR sheath. Atrial pace mapping at the tricuspid ring targeting the shortest A to delta is also difficult and not accurate [1]. Ablating the AV node will result in fully preexcited decremental rhythm but without tachycardia. Cappato et al. [3] emphasize a unique mode of mapping in which a deliberate attempt is made to obtund conduction




Figure 11: X-ray in the RAO and LAO views demonstrating ablation catheter inserted via right femoral vein and positioned at the lateral tricuspid annulus during Mahaim atriofascicular ablation. Other catheters placed in the high right atrium, RV Apex and coronary sinus.

over the pathway by catheter manipulation (“bump mapping”) to verify the successful ablation site. Targeting the earliest V at the apical part of RV during maximum preexcitation is difficult but could be done using 3D mapping technology. Right ventricular mapping and ablation—especially using the 3D mapping technology—during fully Preexcited complexes (atrial pacing or antidromic AV reentrant tachycardia) can identify the site of earliest right ventricular activation at the apical third of the right ventricle with activation at or before the onset of the QRS on the surface ECG. The earliest ventricular potential is preceded by a distinct high frequency Mahaim or RBB potential similar to the one recorded at the tricuspid annulus. At progressively more apical sites, the AP potential was recorded later, whereas the local ventricular signal was recorded earlier. RBBB either transient or permanent by ablation increases the VA (due to transeptal activation of LBB then retrograde His activation) and therefore increase the tachycardia cycle length. Ablation of the distal septal right bundle branch will not eliminate AP conduction and, may increase episodes of AV reentrant tachycardia by prolonging the VA conduction time and makes tachycardia incessant; therefore ablation at the earliest ventricular signal is not a good idea.

Conclusion

Mahaim fiber is a rare special endocardial accessory pathway and can present as non-Wolf Parkinson White (WPW) preexcitation syndrome. Mahaim Fibers lack the usual characteristics of WPW and require a special consideration for diagnosis and treatment.

References

1. Klein GJ, Guiraudon G, Guiraudon C, Yee R (1994) The nodoventricular Mahaim pathway: an endangered concept? *Circulation* 90: 636-638.
2. McClelland JH, Wang X, Beckman KJ, Hazlitt HA, Prior MI, et al. (1994) Radiofrequency catheter ablation of right atriofascicular (Mahaim) accessory pathways guided by accessory pathway activation potentials. *Circulation* 89: 2655-2666.
3. Cappato R, Schluter M, Mont L, Kuck KH (1994) Anatomic electrical and mechanical factors affecting bipolar endocardial electrograms: impact on catheter ablation of manifest left free-wall accessory pathways. *Circulation* 90:282-290.
4. Grogan HR, Lee RJ, Kwasman M, Epstein LM, Schamp DJ, et al. (1994) Radiofrequency catheter ablation of atriofascicular and nodoventricular Mahaim tracts. *Circulation* 90: 272-281.

5. Gallagher JJ, Smith WM, Kasell JH, Benson DW Jr, Sterba R, et al. (1981) Role of Mahaim fibers in cardiac arrhythmias in man. *Circulation* 64: 176-189.
6. Mahaim I, Benatt (1938) Nouvelles recherches sur les connexions superiors de la branche gauche du faisceau de His-Tawara avec cloison interventriculaire. *Cardiologia* 1:61-120.
7. Anderson RH, Becker AE, Brechenmacher C, Davies MJ, Rossi L (1975) Ventricular preexcitation. A proposed nomenclature for its substrates. *Eur J Cardiol* 3: 27-36.
8. Becker AE, Anderson RH, Path MRC (1978) The anatomical substrates of Wolff-Parkinson-White syndrome: a clinic-pathologic correlation in seven patients. *Circulation* 57:870-879.
9. Gillette PC, Garsoh A, Cooley DA, McNamara DG (1982) Prolonged and decremental antegrade conduction properties in right anterior accessory connections: wide QRS antidromic tachycardia of left bundle branch block pattern without Wolff-Parkinson-White configuration in sinus rhythm. *Am Heart J* 103:66-74.
10. Ross DL, Johnson DC, Koo CC, Mortensen PP, Cooper MJ et al. (1987) Surgical treatment of supraventricular tachycardia without the WPW syndrome: current indications, techniques and results. *Cardiac Arrhythmias: Where to Go From Here?* Mount Kisco, NY: Futura Publishing Co 216: 591-603.
11. Klein GJ, Guiraudon GM, Kerr CR, Sharma AD, Yee R (1988) “Nodoventricular” accessory pathway:evidence for a distinct accessory atrioventricular pathway with atrioventricular node-like properties. *J Am Coll Cardiol* 11: 1035-1040.
12. Leitch JW, Klein GJ, Yee R, Murdock CJ (1990) New concepts on nodoventricular accessory pathways. *J Cardiovasc Electrophysiol* 1:220-230.
13. Murdock CJ, Leitch JW, Klein GJ, Guiraudon GM, Yee R, et al. (1991) Epicardial mapping in patients with “nodoventricular” accessory pathways. *Am J Cardiol* 68: 208-214.
14. Porkolab FL, Alpert BL, Scheinman MM (1999) Failure of right atrial premature beats to reset atriofascicular tachycardia. *Pacing Clin Electrophysiol* 22: 528-530.
15. Peinado R, Merino JL, Ramirez (2001) Decremental atriofascicular accessory pathway with bidirectional conduction: delineation of atrial and ventricular insertion by radiofrequency current application. *J Cardiovasc Electrophysiol* 12:489-492.
16. Anaclerio M, Luzzi G, Forleo C (1999) Radiofrequency catheter ablation of a bidirectional decremental accessory atrioventricular pathway in the coronary sinus. *Cardiologia* 44:89-95.
17. Belhassen B, Glick A (2002) QRS complexes with a left bundle branch block morphology during adenosine triphosphate test: what is the diagnosis? *J Cardiovasc Electrophysiol* 13: 519-520.
18. Bardy GH, Fedor JM, German LD, Packer DL, Gallagher JJ (1984) Surface

-
- electrocardiographic clues suggesting presence of a nodofascicular Mahaim fiber. *J Am Coll Cardiol* 3: 1161-1168.
19. Haïssaguerre M, Cauchemez B, Marcus F, Le Métayer P, Lauribe P, et al. (1995) Characteristics of the ventricular insertion sites of accessory pathways with anterograde decremental conduction properties. *Circulation* 91: 1077-1085.
20. Heald SC, Davies DW, Ward DE, Garratt CJ, Rowland E (1995) Radiofrequency catheter ablation of Mahaim tachycardia by targeting Mahaim potentials at the tricuspid annulus. *Br Heart J* 73: 250-257.
21. Davidson NC, Morton JB, Sanders P (2002) Latent Mahaim fiber as a cause of antidromic reciprocating tachycardia: recognition and successful radiofrequency ablation. *J Cardiovasc Electrophysiol* 13:74-78.
22. Rodriguez LM, Smeets JL, de Chillou C, Metzger J, Schläpfer J, et al. (1993) The 12-lead electrocardiogram in midseptal, anteroseptal, posteroseptal and right free wall accessory pathways. *Am J Cardiol* 72: 1274-1280.
23. Tchou P, Lehmann MH, Jazayeri M, Akhtar M (1988) Atriofascicular connection or a nodoventricular Mahaim fiber? Electrophysiologic elucidation of the pathway and associated reentrant circuit. *Circulation* 77: 837-848.