

## Non Infectious Cavitory Lung Lesions in a Patient with Adult Onset Still's Disease: A Case Report

Mitchell S<sup>\*</sup> and Helen R

Department of Internal Medicine, University Hospital, New York, USA

**Corresponding author:** Mitchell S, Department of Internal Medicine, University Hospital, New York, USA, Tel: 8184216483; E-mail: mstotland17@gmail.com

**Received date:** November 03, 2016; **Accepted date:** December 13, 2016; **Published date:** December 20, 2016

**Copyright:** ©2016 Mitchell S, et al. This is an open-access article distributed under the terms of the Creative Commons Attribution License, which permits unrestricted use, distribution, and reproduction in any medium, provided the original author and source are credited.

### Abstract

Acute Onset Still's Disease (AOSD) is a disease of immunologic and hematologic dysfunction, whereby a percentage of cases develop further into Macrophage Activating Syndrome (MAS). This patient is a 35 year old Caucasian male with Acute Onset Still's Disease without MAS was hospitalized for multiple cavitory lung lesions. Lesions included a larger estimated 2.5 cm x 2.5 cm cavitory lesion in the Right Middle Lobe and smaller estimated 1.3 x 1.4 cm and 1.8 x 1.2 cm lesions in the Left Lower Lobe of the lungs. The larger lesion was seen on chest X-ray a further detailed on a chest CT scan, which revealed the remaining two smaller pulmonary lesions. The patient experienced undulating fevers as high as 101°F. The patient was put on isolation and received serial blood cultures, sputum cultures, acid fast stains of sputum, urine cultures, viral film array serology all resulting in negative results. Over seven acid fast bacilli stains of sputum were negative in the setting of multiple cavitory lung lesions with high suspicion of active Tuberculosis. The patient received immediate broad spectrum antibiotic and antifungal intravenous antibiotics without relief in fever or symptoms. The patient received a full body Indium scan and MRI of the brain looking for a source of possible infection and further classification of his disease; both of which were negative. The blood and sputum fungal and bacterial cultures were negative. Serial chest CT and chest X-ray demonstrated slightly smaller cavitory lung lesions with thinner walls. The suspicion of Tuberculosis remained high and a lung biopsy was obtained of the large cavitory lesion in the Left Middle Lobe, which did not demonstrate acid fast staining on three separate samples. This patient was concluded to have noninfectious cavitory lung lesions and discharged home with close follow up. He is the first patient reported with AOSD Disease without MAS hospitalized for undulating fevers and multiple cavitory lung lesions without evidence of Tuberculosis of active infection.

**Keywords:** Acute onset still's disease; Hematologic dysfunction; Macrophage activating syndrome; MRI; Cavitory lung lesions; Tuberculosis; Broad spectrum antibiotic; Leukocytosis

**Abbreviations:** AOSD: Acute Onset Still's Disease; MAS: Macrophage Activating Syndrome; AOS: Acute Onset Still's Disease

### Introduction

Acute Onset Still's Disease (AOSD) is a disease of immunologic and hematologic dysfunction of white blood cells attacking host cells. This is a rare systemic inflammatory disease whereby characteristic features consist of high spiking fevers over 39 degrees celsius, joint pain and a popular light reddish/orange cutaneous rash and leukocytosis. Individuals with this disease frequently have elevated ferritin levels. AOSD is generally a diagnosis of exclusion; individuals with this disease are worked up and ruled out for many other disease processes before reaching this diagnosis. About 1/100,000 individuals have this disease in the United States. Severe complications can include serositis, pericarditis and hepatomegaly and severe leukocytosis causing organ ischemia.

Some cases of AOSD can develop further into Macrophage Activating Syndrome (MAS) that can be life threatening whereby a massive increase and activation of macrophages and T lymphocytes occur in addition to circulation cytokines such as GM-CSF and interferon gamma. In contrast to a rheumatoid flare the ESR rate is decreased to normal in MAS [1,2].

Treatment consists of immune modulating agents and steroids, drugs that target interleukin 1, TNF alpha and DNA modulating agents such as methotrexate, entanercept, anikara and cyclophosphamide in addition to others are used [3,4].

This treatment of suppressing the immune system systemically disposes individuals with AOSD to systemic and local infections. Particularly worrisome is causing infection or reactivation with Tuberculosis among many other rare or common while being treated with these agents [5]. Therefore it is imperative to have close observation of patients with AOSD on immune modulating agents to examine and treat for any infection and counterbalance the immune modulating therapy under guidance of an experienced physician.

### Case Report

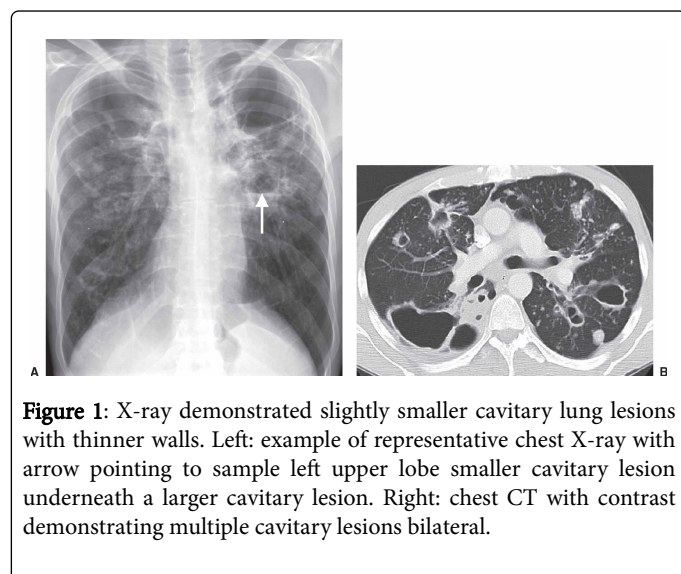
This patient is a 35 year old Caucasian male with Acute Onset Still's Disease without MAS was hospitalized for recurrent high grade fevers at home. He has a known diagnosis of AOSD. The patient reported sweating, fevers, slight nausea, a dry cough and feeling of fatigue and sick. He denied any vomiting, diarrhea, constipation, local limb pain or infection sight, shortness of breath, chest pain or focal neurologic signs. He denied any recent travel or exposure to sick contacts. The patient reported being natively born to the USA with no prior exposure or known contacts with Tuberculosis. The patient tried over the counter Tylenol which did not help his symptoms; after 3 days of fevers he came to the local Emergency Room for workup and treatment.

On physical exam the patient had a temperature of 101°F with normal other vital signs [6,7]. His physical exam was relatively unremarkable other than feel of warmth and discomfort with mild abdominal discomfort on palpation he was not in acute distress or dyspnic.

The patient's labs were remarkable for a significantly elevated WBC, Ferritin with normal renal function, hepatic enzymes, coagulation studies, electrolytes and ECG. The patient's chest X-ray showed mild bilateral infiltrates and a Right sided cavitory lung lesion. The patient had sputum cultures, urine cultures, blood cultures drawn and went for a lung and mediastinal CT scan in the ED [8-10]. The patient was admitted to the inpatient medicine service with Infectious Disease, and Rheumatologist consultations.

CT of the chest demonstrated an approximate 2.5 cm x 2.5 cm cavitory lesion in the Right Middle Lobe and smaller estimated 1.3 x 1.4 cm and 1.8 x 1.2 cm lesions in the Left Lower Lobe of the lungs with mild bilateral pleural effusions. The patient was put on isolation and acid fast stains of sputum, urine cultures, film array all resulted in negative results [11-13]. Over seven acid fast bacilli stains of sputum were negative in the setting of multiple cavitory lung lesions with high suspicion of active Tuberculosis. The patient received immediate broad spectrum antibiotic and antifungal intravenous antibiotics without relief in fever or symptoms including inhaled Tobramycin, IV Vancomycin and IV Meropenem. The patient also was started in IV methyl prednisone that was later switched to oral prednisone.

The patient persisted in his fevers on the general medical floor for about a week in duration. In the presence of these cavitory lung lesions infection was highly suspected. A Right arm PICC line was placed and the patient received a full body Indium scan and MRI of the brain looking for a source of possible infection and further classification of his disease; both of which were negative [14]. The blood and sputum fungal and bacterial cultures were negative. Serial chest CT and chest X-ray demonstrated slightly smaller cavitory lung lesions with thinner walls (Figures 1A and 1B).



**Figure 1:** X-ray demonstrated slightly smaller cavitory lung lesions with thinner walls. Left: example of representative chest X-ray with arrow pointing to sample left upper lobe smaller cavitory lesion underneath a larger cavitory lesion. Right: chest CT with contrast demonstrating multiple cavitory lesions bilateral.

The suspicion of Tuberculosis remained high and a biopsy was obtained of the large cavitory lesion in the Left Middle Lobe to finally rule out Tuberculosis. This biopsy was negative for acid fast staining on three separate samples. This patient was concluded to have noninfectious

cavitory lung lesions. Over the course of his hospital stay his fevers were less frequent; he was discharged home with close follow up.

## Discussion

The cause of AOSD is unknown with theories that it is related to other systemic autoimmune disease processes such as Systemic Lupus Erythematosus and Rheumatoid Arthritis where there are genetic and non-genetic components contributing to the disease.

The risk of infection remains high while treated on immune modulating agents and systemic steroids. There is a constant balance between over suppressing the immune system and under suppressing the immune system. Over suppressing the immune system subsequently better controls the AOSD, but predisposes the patient to systemic and local infection [15,16]. Under suppressing the immune system prevents many infectious from occurring by humoral and innate immunity, however allows for the patients autoimmune process to flare, and thus leads to more symptoms associated with the disease. It is imperative for the patient to be under guidance of a Rheumatologist or another physician with experience with managing this disorder in order to appropriately treat the patient.

Cavitory lung lesions are most concerning for active Tuberculosis, which in this case the patient was thought to be manifesting. Due to the high contagiousness of the disease and lethal ramifications, it is imperative for patients with suspicion of Tuberculosis to be on strict contact respiratory isolation and hospital staff and patient visitors must be appropriately educated and adherent to isolation protocols to prevent spread of infection. In this case the multiple cavitory lung lesions are uncharacteristic of Tuberculosis and likely can represent additional diagnoses of cavitory pneumonia, abscess, fungal cavitations and malignancy [17]. This patient had frequent high fevers over 39 degrees celsius and leukocytosis, thus concerning for acute bacterial of fungal infection. Viral infectious typically do not cause high fevers and cavitory lung lesions, but several viral serologies were drawn and negative in addition to a negative film array to rule out influenza and common viral infections as the source of the patient's symptoms. The patient had a course of 1 week approximately of IV Vancomycin, Meropenem and Inhaled Tobramycin without change in his symptoms. This in addition to multiple negative blood, urine and sputum cultures disfavors infectious etiology. However, due to the concern of resistance of infection to antibiotics a further workup was indicated in this patient including an additional CT chest and full body indium scan. Additionally, a brain MRI was recommended and performed due to possible risk of CNS involvement of Tuberculosis or other etiology, which was negative. This was further reassuring of the patient's stability and further disfavoring infectious etiology of the cavitory lung lesions.

The repeat CT scan demonstrated smaller size of the cavitory lung lesion with thinner walls, which is uncharacteristic of Tuberculosis. The patient further improved in symptoms; it was not clear if this was attributed to the antibiotic coverage or the natural course of AOSD, however due to the negative workup of infectious etiology it is likely that the patient's improvement in symptoms was due to the natural course of the disease while on prednisone [18,19]. With the multiple negative acid fast stains and cultures of sputum to rule out Tuberculosis, the house Pulmonologist was not comfortable discharging the patient until definitively Tuberculosis was ruled out. Thus, a lung biopsy via flexible bronchoscopy was performed and pathology revealed negative acid fast staining for Tuberculosis. The acid fast stains of sputum can be falsely negative as frequent sputum

samples can be inadequate or improperly managed. Subsequently, the lung biopsy tissue is more sensitive and specific for diagnosis pulmonary tuberculosis more accurately. This patient was also put on IV methyl prednisone that was tapered to oral prednisone. This was appropriate management to provide coverage for possible severe infection with broad spectrum antibiotics and simultaneously treat with steroids for control of an AOSD flare.

This case was the first reported of multiple cavitory lung lesions in a patient with AOSD ruled out for active infection and Tuberculosis. The patient improved symptomatically off antibiotics with prednisone and was decided to discharge him home with close follow up while continuing prednisone. This patient will need close attention under physician specialist to ensure adequate treatment of his AOSD. Additionally, it is important to recognize that this patient is still at risk for Tuberculosis and further systemic and local infections despite his negative workup for infectious etiology from this hospital admission. Thus, if future episodes of high fever and symptoms of infection occur, it is imperative to treat each episode individually and not disregard active infection or Tuberculosis, as this patient is still of higher risk for these infections due to his autoimmune state and further with treatment of immune suppressing agents. The final diagnosis at the end of this patient's hospitalization was noninfectious cavitory lung lesions likely related to the patient's AOSD.

## Conclusion

High fevers and cavitory lung lesions on imaging in a patient with AOSD must be worked up and ruled out for active infection and Tuberculosis. Further, empiric treatment and medical care is imperative during episodes. The guidance of physicians is imperative for a patient with systemic autoimmune disorders undergoing immune modulating treatment.

## References

1. Akkara Veetil BM, Yee AH, Warrington KJ, Aksamit AJ Jr, Mason TG (2012) Aseptic meningitis in adult onset Still's disease. *Rheumatol Int* 32: 4031-4034.
2. Agarwal S (2011) A rare trigger for macrophage activation syndrome. *Rheumatol Int* 31: 405-407.
3. Giampietro C, Fautrel B (2012) Anti-Interleukin-1 Agents in Adult Onset Still's Disease. *Int J Inflamm* (317820).
4. Cush JJ, Medsger TA Jr, Christy WC, Herbert DC, Cooperstein LA (1987) Adult-onset Still's disease. Clinical course and outcome. *Arthritis Rheum* 30: 186-194.
5. Debi U, Ravisanakar V, Prasad KK, Sinha SK, Sharma AK (2014) Abdominal tuberculosis of the gastrointestinal tract: Revisited. *World J Gastroenterol* 20: 14831-41840.
6. Giovanna, Valesini Guido (2012) IL-18 Serum Level in Adult Onset Still's Disease: A Marker of Disease Activity. *Int J Inflamm* 1-6.
7. Efthimiou P, Kontzias A, Ward CM, Ogden NS (2007) Adult-onset Still's disease: can recent advances in our understanding of its pathogenesis lead to targeted therapy?. *Nat Clin Pract Rheumatol* 3: 328-335.
8. Grom AA, Mellins ED (2010) Macrophage activation syndrome: advances towards understanding pathogenesis. *Curr Opin Rheumatol* 22: 561-566.
9. Kumar V, Abbas AK, Fausto N, Mitchell RN (2007) Robbins Basic Pathology. Saunders Elsevier 516-522.
10. Lawn SD, Zumla AI (2011) Tuberculosis. *Lancet* 378: 57-72.
11. Luthi F, Zufferey P, Hofer MF, So AK (2002) Adolescent-onset Still's disease": characteristics and outcome in comparison with adult-onset Still's disease. *Clin Exp Rheumatol* 20: 427-430.
12. Owlia MB, Mehrpoor G (2009) Adult - onset Still's disease: A review. *Indian J Med Sci* 63: 207-221.
13. Malaviya AN, Kotwal PP (2003) Arthritis associated with tuberculosis. *Best Pract Res Clin Rheumatol* 17: 319-343.
14. Manoj EM, Srigrishna R, Ragunathan MK (2012) Hepatic tuberculosis presenting with extreme hyperferritinemia masquerading as adult-onset Still's disease: A case report. *J Med Case Rep* 6:195.
15. Nordström D, Knight A, Luukkainen R, van Vollenhoven R (2012) Beneficial effect of interleukin 1 inhibition with anakinra in adult-onset Still's disease. An open, randomized, multicenter study. *J Rheumatol* 39: 2008-2011.
16. Rosário C, Zandman-Goddard G, Meyron-Holtz EG, D'Cruz DP, Shoenfeld Y (2013) The hyperferritinemic syndrome: Macrophage activation syndrome, Still's disease, septic shock and catastrophic antiphospholipid syndrome. *BMC Med* 11: 185.
17. Sugiura T, Kawaguchi Y, Harigai M, Terajima-Ichida H, Kitamura Y, et al. (2002) Association between adult-onset Still's disease and interleukin-18 gene polymorphisms. *Genes Immun* 3: 394-399.
18. Visser A, van de Vyver A (2011) Severe hyperferritinemia in Mycobacteria tuberculosis infection. *Clin Infect Dis* 52: 273-274.
19. Yamaguchi M, Ohta A, Tsunematsu T, Kasukawa R, Mizushima Y, et al. (1992) Preliminary criteria for classification of adult Still's disease. *J Rheumatol* 19: 424-430.