

New Evaluation Method to Assess the Improvement of Glabellar Lines and Crow's Feet Lines with Onabotulinum Toxin A

Maurizio Cavallini¹ and Marco Francesco Papagni^{2*}

¹Department of Plastic Surgery, AICPRE Fellow (Italian Association of Aesthetic Plastic Surgery), Italy

²Department of Plastic Surgery, Centro Diagnostico Italiano (C.D.I.), Italy

*Corresponding author: Marco Francesco Papagni, Department of Plastic Surgery, Centro Diagnostico Italiano (C.D.I.), Saint Bon 20 Milan, Italy, Tel: +393336115959; E-mail: dottmarcopapagni@gmail.com

Received date: March 30, 2016; Accepted date: May 09, 2016; Published date: May 11, 2016

Copyright: © 2016 Cavallini M, et al. This is an open-access article distributed under the terms of the Creative Commons Attribution License, which permits unrestricted use, distribution, and reproduction in any medium, provided the original author and source are credited.

Abstract

Background: Treatment with Onabotulinum toxin A for the improvement of glabellar lines and crow's feet represents one of the most requested and performed procedures in the field of aesthetic medicine. The efficacy of Onabotulinumtoxin A for the treatment of glabellar lines and crow's feet have been widely reported. Although, the assessment of the grade of efficacy is actually based on clinical evaluation scales by an healthcare professional, giving space to a wide interpretative subjectivity which depends on different factors including a personal experience and a subjective aesthetic judgment.

Objectives: This study aims to provide a digital evaluation tool in order to assess an objective measure of the degree of improvement for the areas treated with Onabotulinum toxin A, using a digital analysis of the images from the treated areas in order to exclude the subjective component during the evaluation.

Methods: A total of 20 women with moderate-to-severe CFL and GL (maximum contraction) were enrolled in the study. Each woman received a total of 44 U of Onabotulinum toxin A (20 U and 24 U for the treatment of glabellar lines and crow's feet, respectively). Images from the treated areas were collected using Antera 3D® device at baseline, 4 weeks and 4 months after treatment, at both rest and maximum muscles contraction.

Results: Improvements for both glabellar lines and crow's feet lines were detected with Digital Analysis of the Cutaneous Surface, further confirming the efficacy of Onabotulinum toxin A.

Conclusion: The digital evaluation tool proposed in this study is an objective and easy to use method for the assessment of glabellar lines and crow's feet lines improvements after the treatment with Onabotulinum toxin A.

Keywords: Onabotulinum toxin A; Antera 3D®; Glabellar lines; Crow's feet lines improvements

with objectivity, evaluating the same areas of the skin at baseline and after treatments with Onabotulinum toxin A.

Introduction

Onabotulinum toxin A (BoNT-A) inhibits neural conduction by interfering with the release of acetylcholine. After binding selectively to presynaptic receptors, Onabotulinum toxin A enters the cell and cleaves a membrane protein causing acetylcholine exocytosis [1]. The use of Onabotulinum toxin A for aesthetic purposes was introduced by Carruthers in 1992 for glabellar frown lines [2], and after ten years, in 2002, the Food and Drug Administration (FDA) approved its application for aesthetic intervention.

Although Onabotulinum toxin A it's a widely used treatment method and a lot of data from published studies support its clinical efficacy, few of them are based on clinical evaluation tools able to exclude the subjective component of measurements [3-15]. Then, an objective and quantitative scale is still needed for the evaluation of lines severity, skin texture improvement and for the monitoring of the effectiveness of Onabotulinum toxin A treatment. Here in this study, we propose a digital evaluation tool able to detect lines improvements

Materials and Methods

This is a prospective, single group, not randomized and open label observational study conducted between September 2014 and June 2015 in Milan, Italy. Twenty healthy Caucasian females, with median age of 54 years (range: 35-76) were eligible for the study. Exclusion criteria were age <18 years, treatment of glabellar lines and crow's feet lines with absorbable fillers in the last 6 months previous the study, botulinum toxin treatment or laser treatment in the upper face in the previous 6 months, blepharoplasty and face lifting in the last 1 year, pregnancy and nursing, and immunological disorders.

Subjects were at least 18 years of age who met severity criteria for both CFL and GL (moderate-to-severe bilaterally symmetrical CFL at maximum smile and moderate-to-severe GL at maximum frown) requiring treatment.

Baseline CFL and GL severity determination was based on investigator ratings using the Facial Wrinkle Scale (FWS; 0=none, 1=mild, 2=moderate, and 3=severe). Each patient provided a written informed consent. This study complied with the ethical rules

recommended by 2008 Declaration of Helsinki. Authors ensure adherence to the principles of good clinical practices (GCPs), including adequate human subject protection (HSP).

Onabotulinum toxin A (Vistabex®, Allergan®, Inc.) was reconstituted with 1.25 ml of saline solution and each patient received a total of 44 U

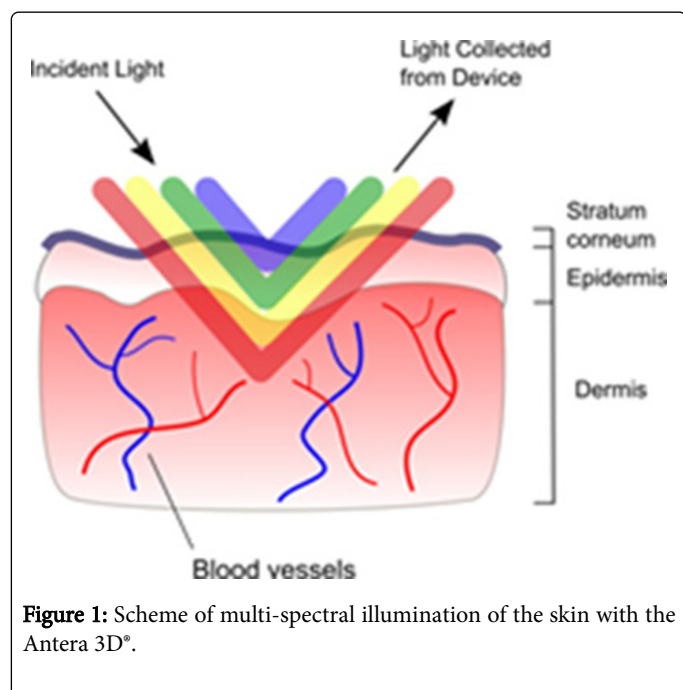
(20 U and 24 U for the treatment of glabellar lines and crow's feet lines, respectively). Information on injection procedures are reported in Table 1.

	Area of treatment	
	Glabellar lines	Crow's feet
Sites of injection (n, location)	5 sites of injections:- 1 median position for the treatment of procerus muscle-2 for each side of the corrugator muscle	3 sites of injection for each side, 1.5 cm from the lateral cantus: - 1 site in the projection of the horizontal line starting from the lateral cantus, - 2sites, 1 cm above and 1 cm below the horizontal line respectively.
Injection technique	- perpendicular to skin surface-deep at medial point, superficial at lateral point	- perpendicular to skin surface - superficial
Injected dose	20 U, 4 U each site of injection	24 U, 4 U each site of injection

Table 1: Injection procedures for the treatment of glabellar lines and crow's feet.

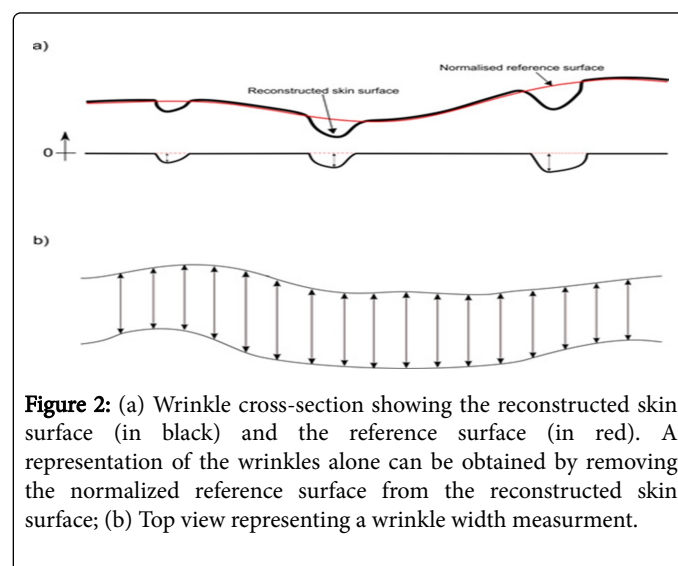
Measurement

All the patients enrolled in the present study were evaluated by a special software, Digital Analysis of the Cutaneous Surface [14-20], performed by Antera 3D® device (Antera3D®, Miravex Limited, Dublin, Ireland) as previously reported [14]. The assessment tool is provided by a digital camera (Antera 3D®) 56 x 56 mm amplitude, placed on the area of the skin where measurements are performed. This method relies on multi-directional illumination and computer-aided reconstruction of the skin surface, illuminating the surface from different angles and using the differences between these images to reconstruct the surface in three dimensions. The skin topography and chromophore concentration are derived from the spatial and spectral analysis of the acquired image data, obtained by illuminating the skin with light emitting diodes (LEDs) of different wavelengths shining from different directions (Figure 1).



The reconstruction of the skin surface was achieved using a technique based on Shape from Shading (SFS) [B.K. Horn, *The Psychology of Computer Vision*, P.H. Winston ed., New York, 1975], extensively modified in order to eliminate skin glare and improve the accuracy of measured data [PCT patent application PCT/EP2010/001168, Irish Patent No. S85695]. The reconstructed surface is then used for quantitative skin analysis, such as depth and width of wrinkles and skin roughness.

For wrinkles assessment, a filter was applied to the reconstructed 3D skin surface, in order to discriminate between wrinkles-related curves (i.e. sharp, fine skin indentations) and the standardized reference surface, the skin as it would be in the absence of wrinkles. The standardized reference shape was then removed to obtain wrinkles representation only (Figure 2).



Wrinkles were assessed for both depth and width. Wrinkle depth was defined as the average of the maximum depths of each cross-section along the strip selection's centerline. Wrinkle's width was defined as the average width of each cross-section along the strip selection's centerline. The overall size of wrinkles was proportional to the average cross-section area along the strip selection centerline.

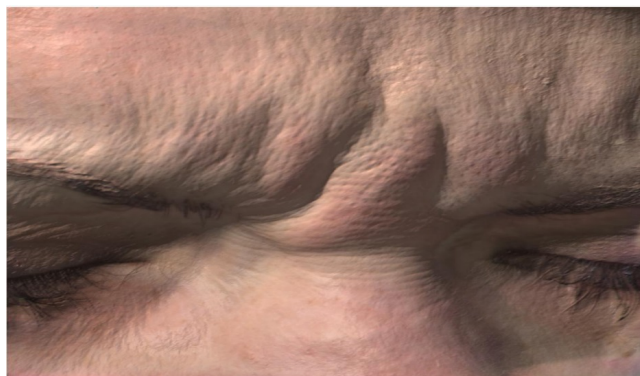

Figure 3: Case (A) Caucasian Female, 36 years old. Antera 3D® Digital Image of Glabella in maximal frown. Preoperative.

For glabellar lines analysis, the most depth and/or more representative wrinkle was selected. For crow's feet, the most representative wrinkle from the upper area, delimited by the lateral canthal muscle, eyebrow's tail extremities and the external canthus, was assessed.

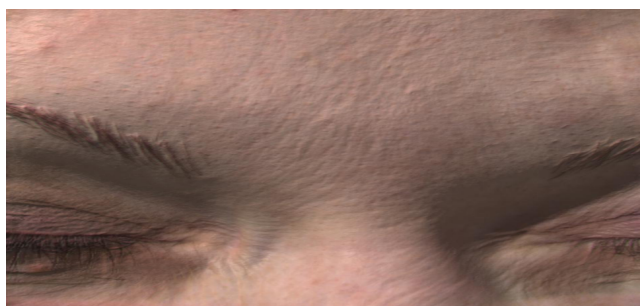

Figure 4: Case (A) Caucasian Female, 36 years old. Antera 3D® Digital Image of Glabella in maximal frown. Postoperative 1 month later.

Methods

Antera 3D® digital images and photographs were performed at 3 different times, at rest and at maximum muscular activity of glabellar (maximal frown) (Figures 3-5) and periocular areas (maximum smile and contraction of orbicularis oculi muscle) (Figures 6-8). In particular, two images were taken both frontal (at rest and maximum muscular activity) for the glabellar area, right and left profiles for the periocular area, at rest and maximum muscular activity respectively as recommended by the international guidelines [18].

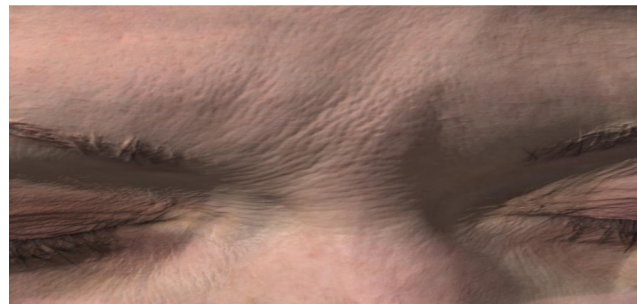

Figure 5: Case (A) Caucasian Female, 36 years old. Antera 3D® Digital Image of Glabella in maximal frown. Postoperative 4 month later.

Furthermore, a clinical evaluation was also performed using the Facial Wrinkle Scale (FWS), which assess wrinkles severity in 4 degrees : 0 (none), 1 (mild), 2 (moderate), and 3 (severe). All the pictures were captured with predefined reference anatomic points in standardize reproducible method for each measurement in each patient, using the software graduate visual scale of the digital camera. Collection and statistical analysis of data obtained was then processed by both study clinician and a second expert.

At the first visit, all the clinical information about side effects, adverse events and/or any other information were noted on a register at baseline, 4 weeks and 4 months after treatment.




Figure 6: Case (B) Caucasian Female, 46 years old. Antera 3D® Digital Image of periocular area in maximal contraction. Preoperative.

The primary endpoint was glabellar lines and crow's feet improvements after the treatment with Onabotulinum toxin A. Duration and safety of the treatment represented the secondary endpoints. Patient satisfaction was not an outcome measured in this study.



Figure 7: Case (B) Caucasian Female, 46 years old. Antera 3D® Digital Image of periocular area in maximal contraction. Postoperative 1 month later.

Wrinkles were assessed as follows

For glabellar area, the deepest and/or most significant line was selected and analyzed for both the global improvement of the wrinkle by the length/width ratio (percentage of improvement/100%) and wrinkle depth improvement (millimeters, mm) measured by Antera 3D® software (Figures 9-11)

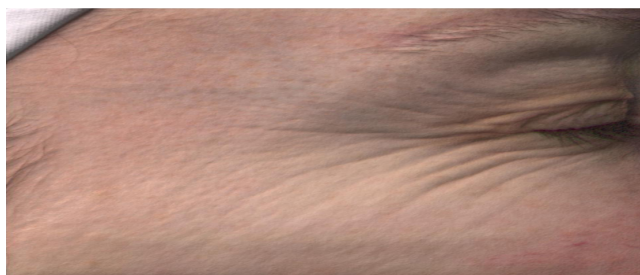

Figure 8: Case (B) Caucasian Female, 46 years old. Antera 3D® Digital Image of periocular area in maximal contraction. Postoperative 4 month later.

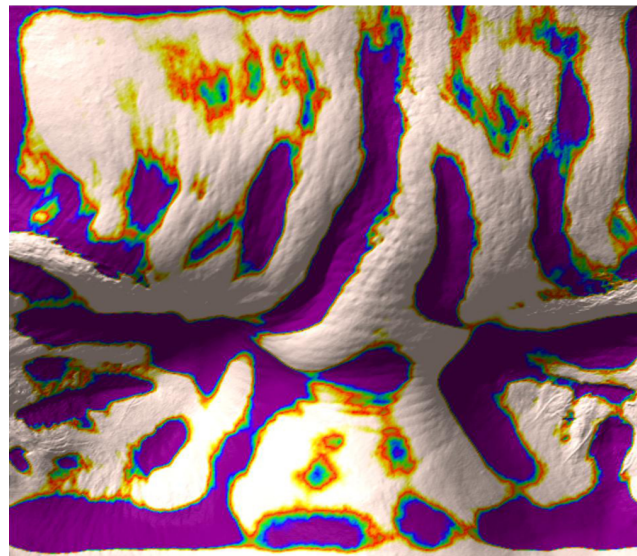


Figure 9: Case (A) Caucasian Female, 36 years old Antera 3D® Software analyzed image of glabellar lines in maximal frown. Preoperative.

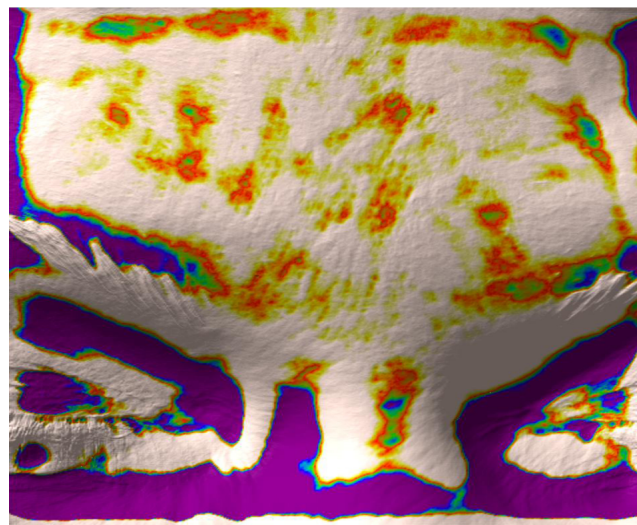


Figure 10: Case (A) Caucasian Female, 36 years old Antera 3D® Software analyzed image of glabellar lines in maximal frown. Postoperative 1 month later.

For crow's feet, the most representative wrinkle from the upper area, delimited by the lateral canthus, eyebrow's tail extremities and the external canthus, was assessed (Figures 12-14).

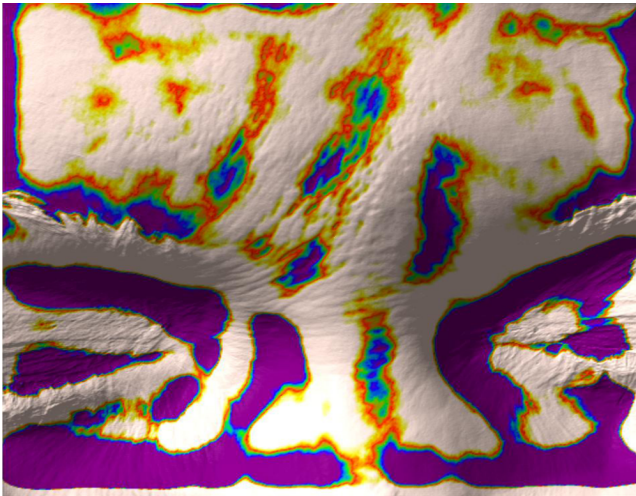


Figure 11: Case (A) Caucasian Female, 36 years old Antera 3D® Software analyzed image of glabellar lines in maximal frown. Postoperative 4 month later.




Figure 12: Case (B) Caucasian Female, 46 years old. Antera 3D® Software analyzed image of periocular lines in maximal frown. Preoperative.




Figure 13: Case (B) Caucasian Female, 46 years old. Antera 3D® Software analysed image of periocular lines in maximal frown. Postoperative 1 month later.


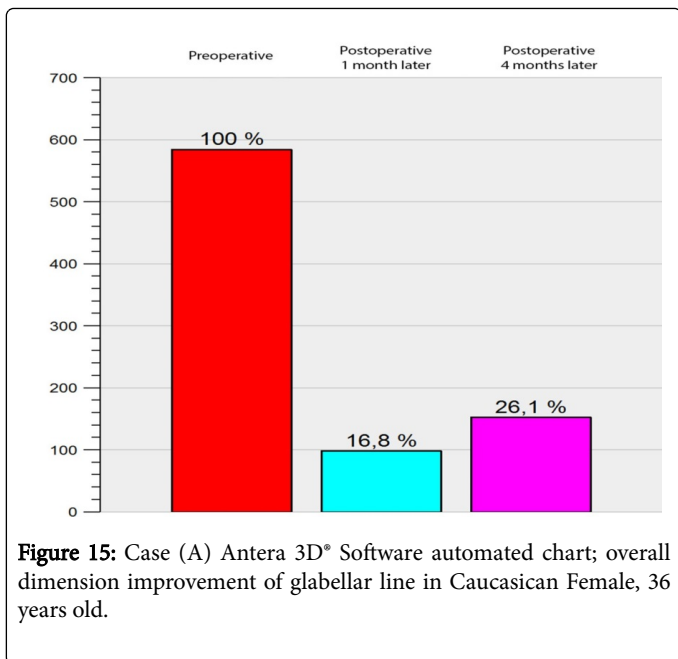
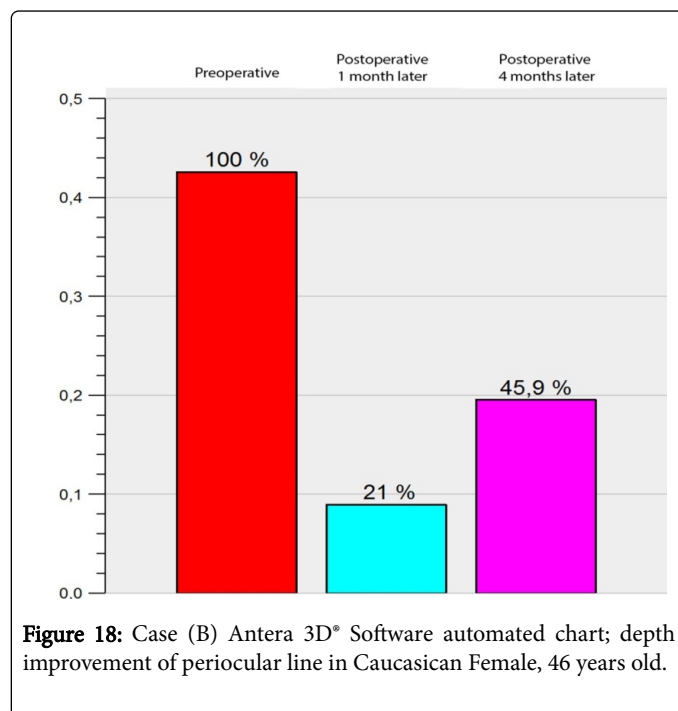
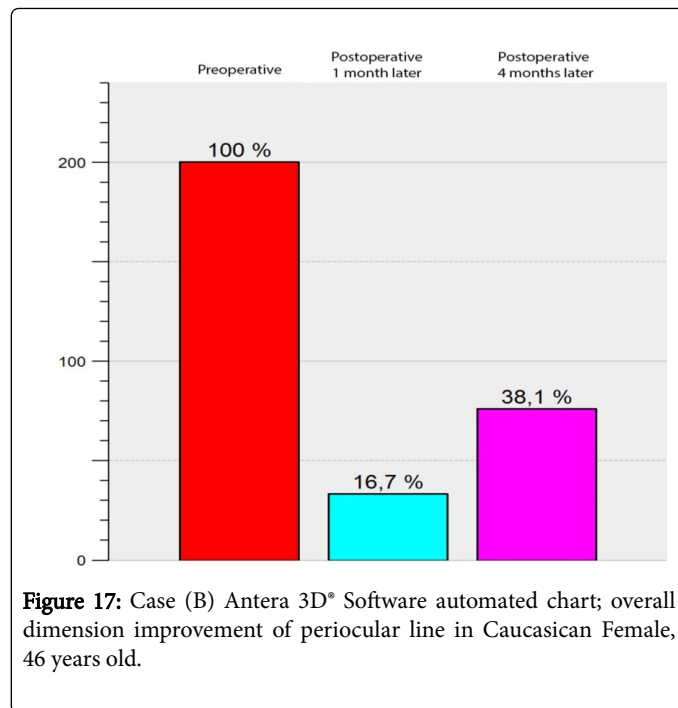
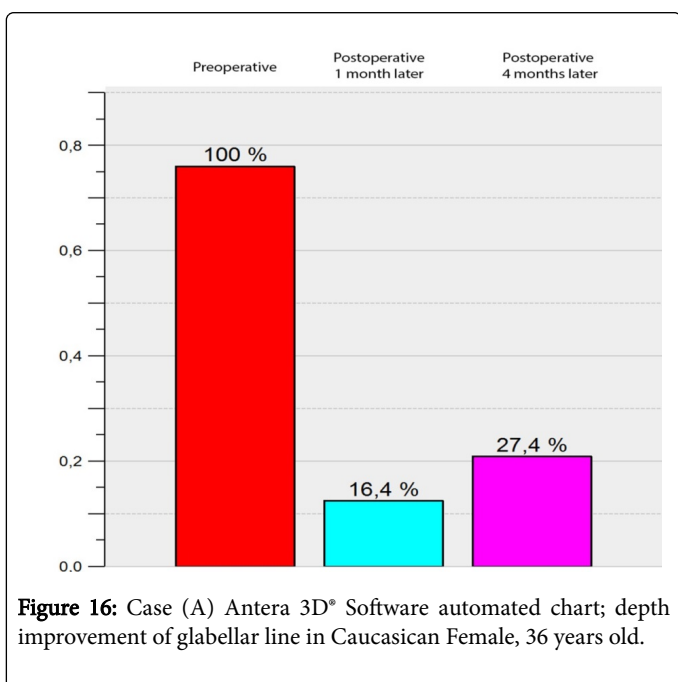


Figure 14: Case (B) Caucasian Female, 46 years old. Antera 3D® Software analysed image of periocular lines in maximal frown. Postoperative 4 month later.



These criteria were chosen to exclude wrinkles resulting from the activity of muscles other than the orbital, or from the combination of more than a muscle as happen for zygomatic muscles. We found the method described as the only one suitable for analysis, since any different method/area selected for the comparison between pre- and post-treatment could include the zygomatic muscles action that interfere with the orbicularis contraction and CFL formations. The power of our method is represented by the fact we can be sure that we are analyzing only the contraction of the orbicularis muscle, which is the target of Onabotulinum toxin A treatment (Figures 15-18).



Results

For glabellar area, the improvement from baseline of the deepest wrinkle was, for the 75% of patients, a value ranging from 45% to 88.6% at 4 weeks, and for the 33% of patient, a value ranging from 44.7% to 61.8% at 4 months after treatment with Onabotulinumtoxin A. Wrinkle depth improved from 0.589 mm at baseline, to 0.248 mm after 4 weeks and 0.416 mm after 4 months from treatment injections.

During the assessment of crow's feet improvements, changes in wrinkles position were considered because of their affection on the

treatment of this area with Onabotulinumtoxin A. The improvement of the most representative wrinkle was, for the 85% of patients, a value ranging from 44.5% to 83.3% at 4 weeks and, for the 30% of patients, a value ranging from 31.1% to 61.9% at 4 months after treatment with Onabotulinumtoxin A. Wrinkle depth improved from 0.37 mm before treatment, to 0.15 mm at 4 weeks and 0.3 mm at 4 months after treatment injections.

As for the evaluation of GL on the FWS, 100% of patients had an improvement of at least 2 grades after 4 weeks and 95% of patient still

had an improvement of at least 1 grade after 4 months (investigator assessment).

Concerning the analysis of CFL on the FWS, 90% of patients had an improvement of at least 2 grades after 4 weeks at least 1 grade after 4 months (investigator assessment). Two examples are reported in Table 2.

	GL FWS grades (Δ) improvement 4 weeks	GL Antera improvement weeks	% 4	GL FWS grades (Δ) improvement 4 months	GL Antera improvement months	% 4	CFL FWS grades (Δ) improvement 4 weeks	CFL Antera improvement weeks	% 4	CFL FWS grades (Δ) improvement 4 months	CFL Antera improvement 4 months	% 4
Patient 1	3	73.7		2	61.8		2	75.7		1	31.1	
Patient 2	3	67.8		3	37.1		2	53.8		1	21.5	

Patient 1 had an improvement of 3 grades on the FWS for GL after 4 weeks (the patient had a score of 3 at baseline and a score of 0 after 4 weeks) and 73.7% of improvement was detected by Antera 3D[®]; after 4 months the improvement of GL on the FWS was 2 grades and 61.8% as detected by Antera 3D[®]. As for CFL, patient 1 had an improvement of 2 grades on the FWS for CFL after 4 weeks (the patient had a score of 3=severe at baseline and a score of 1= mild after 4 weeks) and 75.7% of improvement was detected by Antera 3D[®]; after 4 months the improvement of CFL on the FWS was 1 grade and 31.1% as detected by Antera 3D[®]. Patient 2 had an improvement of 3 grades on the FWS for GL after 4 weeks (the patient had a score of 3 at baseline and a score of 0 after 4 weeks) and 67.8% of improvement was detected by Antera 3D[®]; after 4 months the improvement of GL on the FWS was still 3 grades and 37.1% as detected by Antera 3D[®]. As for CFL, patient 2 had an improvement of 2 grades on the FWS for CFL after 4 weeks (the patient had a score of 3=severe at baseline and a score of 1= mild after 4 weeks) and 53.8% of improvement was detected by Antera 3D[®]; after 4 months the improvement of CFL on the FWS was 1 grade and 31.1% as detected by Antera 3D[®].

Table 2: Results obtained for two patients with both FWS and Antera 3D[®] evaluations.

No serious adverse events were observed during the study treatment. Headache was referred by 3 patients (15%) few hours after being treated with Onabotulinumtoxin A, resolved 12-48 hours from its occurrence and without any treatment need. Two patients (10%) reported bruising at the periocular area, and 1 patient (5%) referred eyelid heaviness which resolved spontaneously 2 weeks after Onabotulinum toxin A injection.

Discussion

Although Onabotulinum toxin A effectiveness for wrinkles aesthetic treatment of is proved and undisputed, the evaluations scales used to assess wrinkles improvements are still debated. These scales are based on different scoring (from 0 to 5 for glabellar lines, and from 0 to 4 for crow's feet) [8] and have a subjective component, living space to individual interpretations by clinician and, in double blind studies, by patient.

Previous studies tried to establish objectives methods to quantify wrinkles improvements after treatment with Onabotulinum toxin A. Heckman et al. [11] established objective parameters to measure the efficacy of Onabotulinum toxin A for correction of hyperkinetic facial lines, which were reproducible and based on serial digital photographs used to measure brows mobility and brow to brow distance.

The Antera 3D[®] Software (Digital Analysis of the Cutaneous Surface) digital tool usefulness has been recently described to evaluate wrinkles severity and texture analysis [14]. In the study, The Antera 3D[®] Software provided an objective, direct, fast, and reproducible method to measure OnabotulinumtoxinA treatment for rhytides. With Antera 3D[®] Software the operator is able to select the investigated area, which is automatically recognized by the software during the subsequent acquisitions. An algorithm is then used to analyze skin

surface and measure parameter changes from baseline, without any subjective evaluation.

In this paper, we applied the Antera 3D[®] Software digital tool for the quantitative assessment of glabellar lines and crow's feet improvements after Onabotulinumtoxin A treatment.

Onabotulinum toxin A was administered following guidelines recommendations, based on FDA, EMA, AIFA and the summary of product characteristics.

Treatment efficacy was evaluated numerically, therefore objectively, based on depth changes of the most representative wrinkle from both glabellar and crow's feet areas. The most representative wrinkle has the highest aesthetic impact and is the most difficult to treat, then reflecting properly treatment success after Onabotulinum toxin A injections. Specifically, for the periocular area we selected the upper wrinkle, delimited by the lateral canthus, eyebrow's tail extremities and the external canthus, which derives from the orbital muscle activity. This method excluded measurements of zygomatic muscles, which are involved at maximum of smile extension and eye wink during photographs acquisition and their activity is subjectively different between patients. Moreover, periocular area dynamics change after treatment, included wrinkle position and the area selected by the investigator during the next assessments. All together, these criteria represent an objective evaluation of wrinkle improvements over a treatment cycle with Onabotulinum toxin A. Wrinkles improvement was assessed by wrinkles depth/length ratio, where depth decreases and length increases as a consequence of treatment efficacy. All data obtained with Antera 3D[®] Software indicated a significant improvement of glabellar lines and crow's feet after treatment with Onabotulinum toxin A, confirming its clinical effectiveness for aesthetic use. Glabellar lines improved up to 88.6% and 73.9% respectively after 4 weeks and 4 months from treatment. For crow's feet, wrinkles improved up to 83.3% and 61.9% after 4 weeks and 4 months from the first Onabotulinum toxin A injection.

We observed, in the group of patients, a large distribution of the improvement percentages. In this study we had used a standard treatment protocol based on the guidelines recommended in the S.P.C. However, the glabellar and periocular area have a most variable muscular contraction patterns in the population. To obtain better results in these areas, as described by De Almeida et al. [20] for the glabellar lines, the injection points should be adapted to the specific contraction patterns in each patient.

A comparison between FWS evaluation and Antera 3D® results has been reported in Table 2, which report data for two patients enrolled in the study. It seems that approximatively 1 grade on the FWS correspond to 25 percentage points of Antera 3D® Software results. The Table 2 clearly shows two important points: first, the "correspondence" FWS/Antera 3D® Software is not always respected (patient 2, GL improvement after 4 months), underlying the subjective bias of the FWS. Second, FWS is just a 4 grades scale, while Antera 3D® Software uses a 100 point scale, allowing a more precise evaluation of lines.

The presence of few and transient side effects during the treatment period, confirmed the safety of Onabotulinum toxin A previously described [18].

In this work, no self-assessment was conducted by patients. Although, we believe that this innovative method could be a valid tool to involve patients during the treatment period, as photographs and measurements show the objective improvement of wrinkle at any time of the treatment period. Furthermore, the objectivity of this tool could help on comparing with more precision the treatment efficacy of the different toxin formulation available for aesthetic use.

Conclusion

Images acquired with Antera 3D® device and analyzed by the special software is a valid and alternative method to assess wrinkles severity as well as their improvement after Onabotulinumtoxin A treatment. Authors find that this fast, objective, reproducible and self-consistent evaluation method could be a very useful tool to be used for both in the clinical practice during dialog with patient and in clinical trials.

Efficacy and safety observed in this study represent a further confirmation of the positive experience of Onabotulinumtoxin A in the aesthetic use.

Acknowledgement

This research received a financial support from Allergan, Inc. Allerga, Inc. didn't have any active role in this study; only authors provide to organize the study, to execute the treatments, to analyze and interpret data, to write and submit the report [Grant number 4301148828].

References

1. Carruthers A, Kane MA, Flynn TC, Huang P, Kim SD, et al. (2013) The convergence of medicine and neurotoxins: a focus on botulinum toxin type A and its application in aesthetic medicine--a global, evidence-based

2. Carruthers JD, Carruthers JA (1992) Treatment of glabellar frown lines with C. botulinum-A exotoxin. *J Dermatol Surg Oncol* 18: 17-21.
3. Allergan I (2010) Botox Cosmetic (Onabotulinum toxin A) [full prescribing information. CA
4. Cosmetic Surgery National Data Bank Statistics (2013) American Society for Aesthetic Plastic Surgery : 7-9.
5. Maas C, Kane MA, Bucay VW, Allen S, Applebaum DJ, et al. (2012) Current aesthetic use of abobotulinumtoxinA in clinical practice: an evidence-based consensus review. *Aesthet Surg J* 32: 8S-29S.
6. Honeck P, Weiss C, Sterry W, Rzany B (2003) Reproducibility of a four-point clinical severity score for glabellar frown lines. *Br J Dermatol* 149: 306-310.
7. Carruthers A, Carruthers J, Hardas B, Kaur M, Goertelmeyer R, et al. (2008) A validated grading scale for forehead lines. *Dermatol Surg* 2: S155-S160.
8. Carruthers A, Carruthers J, Hardas B, Kaur M, Goertelmeyer R, et al. (2008) A validated grading scale for crow's feet. *Dermatol Surg* 2: S173-S178.
9. Alam M, DesJardin J, Arndt KA, Dover JS, Hodapp RM, et al. (2006) A quality rating scale for aesthetic surgical procedures. *J Am Acad Dermatol* 54: 272-281.
10. Conkling N, Bishawi M, Phillips BT, Bui DT, Khan SU, et al. (2012) Subjective rating of cosmetic treatment with botulinum toxin type A: do existing measures demonstrate interobserver validity? *Ann Plast Surg* 69: 350-355.
11. Heckmann M, Schön-Hupka G (2001) Quantification of the efficacy of botulinum toxin type A by digital image analysis. *J Am Acad Dermatol* 45: 508-514.
12. Horn BK (1975) *The Psychology of Computer Vision*. New York: P.H. Winston ed.
13. Goodman GJ, Roberts S (2012) "Home of Younger Skin" (HOYS) program: Defining the change in apparent skin age after facial treatment with botulinum toxin and dermal fillers. *Clin Cosmet Investig Dermatol* 5: 93-99.
14. Cavallini M (2015) Preliminary Report on an Objective, Fast, and Reproducible Method to Measure the Effectiveness of Botulinum Toxin Type A. *Aesthet Surg J* 35: 715-720.
15. Jiang LI, Stephens TJ, Goodman R (2013) SWIRL, a clinically validated, objective, and quantitative method for facial wrinkle assessment. *Skin Res Technol* 19: 492-498.
16. Grove GL, Grove MJ, Leyden JJ (1989) Optical profilometry: an objective method for quantification of facial wrinkles. *J Am Acad Dermatol* 21: 631-637.
17. Cavallini M, Cirillo P, Fundarò SP, Quartucci S, Sciuto C, et al. (2014) Safety of botulinum toxin A in aesthetic treatments: a systematic review of clinical studies. *Dermatol Surg* 40: 525-536.
18. Kohl E, Meierhöfer J, Koller M, Zeman F, Groesser L, et al. (2015) Fractional carbon dioxide laser resurfacing of rhytides and photoaged skin--a prospective clinical study on patient expectation and satisfaction. *Lasers Surg Med* 47: 111-119.
19. Tretti Clementoni M, Lavagno R (2015) A novel 1565 nm non-ablative fractional device for stretch marks: A preliminary report. *J Cosmet Laser Ther* 17: 148-155.
20. de Almeida AR, da Costa Marques ER, Banegas R, Kadunc BV (2012) Glabellar contraction patterns: a tool to optimize Botulinum Toxin Treatment. *Dermatol Surg* 38: 1506-1515.