

## Neoplastic Skin Complications in Transplant Patients: Experience of an Italian Multidisciplinary Transplant Unit

Marconi B<sup>#</sup>, Ricotti F<sup>#</sup>, Giannoni M, Campanati A<sup>\*</sup> and Offidani A

Department of Clinical and Molecular medicine, Dermatology Unit, Polytechnic University of Marche, Italy

<sup>#</sup>The authors equally contributed to the manuscript

<sup>\*</sup>Corresponding author: Dr. Campanati Anna, Dermatology Unit, Department of Clinical and Molecular Sciences, Polytechnic Marche University; Tel: +390715965358; E-mail: anna.campanati@gmail.com

Received date: Apr 29, 2015, Accepted date: June 15, 2015, Published date: June 22, 2015

Copyright: © 2015 Marconi B, et al. This is an open-access article distributed under the terms of the Creative Commons Attribution License, which permits unrestricted use, distribution, and reproduction in any medium, provided the original author and source are credited.

### Abstract

Transplant patients need to be strictly followed, since the immunosuppressive therapies they usually receive can increase the risk of skin complications. This study aims to evaluate the prevalence of neoplastic skin complications in transplant patients. We analyzed 256 liver or kidney transplant patients. The follow-up mean period was  $7 \pm 3.5$  years. The 18.36% of patients developed neoplastic complications, among these 9.37% actinic keratoses, 8.20% non-melanoma skin cancer, and 0.78% cutaneous melanoma.

Among patients who developed non melanoma skin cancer, 61.90% had basal cell carcinoma, 23.81% squamous cell carcinoma, 52% Kaposi's sarcoma and 4.76%, Malherbe's epithelioma. Was also evaluated the prevalence of cutaneous neoplastic complications according the immunosuppressive regimen received by patients as follows: cyclosporine, tacrolimus, steroids, mycophenolate mofetil or everolimus, in single, double or triple therapy. This study demonstrated the increased risk of skin cancer in transplant patients during the first 7 years of follow-up and made the dermatologists aware about the need of a regular cutaneous follow up for this subset of patients.

**Keywords:** Transplant patients; Immunosuppressive therapy; Skin cancer

### Introduction

Patients who have undergone an organ transplant need to be treated with immunosuppressive therapy lifelong to prevent the rejection by immune system [1]. These drugs act by inhibiting the production and the proliferation of cytokines, the differentiation and cellular activation.

The anti-rejection drugs used in these patients can be divided into three groups: calcineurin inhibitors (cyclosporine and tacrolimus) [2], no calcineurin inhibitors (mycophenolate mofetil and everolimus) [3,4] and systemic steroids. These drugs may expose the patients to skin complications as precancerous and neoplastic lesions in the long run [5,6]. Others important factors influencing the development of these cutaneous complications are age, sex, smoke, photo type, sun exposure, viral infection and genetic predisposition [5,6].

The aim of this retrospective study is to give our experience in the field of dermatological assistance of transplant patients during the first seven years of follow-up. Particularly we focused on the onset of the following neoplastic lesions: actinic keratosis (AK), melanoma (MM) and non-melanoma skin cancer (NMSC) as basal cell carcinoma (BCC), squamous cell carcinoma (SCC), Kaposi's Sarcoma and Malherbe's epithelioma. Although actinic keratoses were historically considered pre-neoplastic lesions, recent acquisitions have advanced the idea that they are in-situ malignant lesions, so we included them among skin cancers [7,8].

### Materials and Methods

#### Population

This study was conducted on a total sample of 256 patients from the "Multidisciplinary Group of Transplants liver-kidney-pancreas" of United Hospitals of Ancona, composed by: general surgeons, gastroenterologists, nephrologists, dermatologists, infectivologists, in the period between January 2005 and November 2014. Data for analysis were collected retrospectively.

We analyzed 154 liver transplanted recipients and 102 kidney transplant patients. This population ranged between 18 and 80 years old, with a mean age of  $56.09 \pm 10.33$ ; all patients were Caucasians and they received immunosuppressive therapy.

#### Study Protocol

All useful information were got through clinical and dermoscopic examination of the skin and mucosae: the follow-up started at the 3<sup>rd</sup> month after the transplantation, and every patient was evaluated at 6<sup>th</sup> and at 12<sup>th</sup> month for the first year, and then every year for 7 consecutive years from the transplantation.

During the first examination, was filled a folder collecting data about:

- general data (age, sex);
- transplanted organs (type and year of transplantation);
- personal anamnesis (phototype, smoking, history of sun exposure, previous sunburns,
- family history of skin cancer, splanchnic or haematological tumours and viral infection );

- the on-going immunosuppressive regimen (kind and number of drugs).

The folder was updated about therapy changes and new clinical notice at each follow-up visit. Sun exposure was classified into low, medium and high, depending on the sun exposure hours. The total amount of sun exposure received both on working days and spare time was evaluated. The patients referring daily solar exposure less than 2 hours were considered to have low exposure; those from 2 to 5 hours as medium exposure and those who reported more than 5 hours as high exposure [9].

Skin biopsies or radical excisions were performed when necessary.

The primary outcome was to evaluate the prevalence of neoplastic skin lesions in patients treated with immunosuppressive regimen according to the drug received (cyclosporine, tacrolimus, corticosteroid, mycophenolate mofetil, everolimus) and the regimen established (single, double, triple, and quadruple therapy).

### Statistical analysis

Data obtained were examined through the Graphpad software (version 5.03, el Camino Real, San Diego, CA). Results were expressed as ordinal data were analyzed using the Fisher's exact test, a pvalue <0.05 was considered significant.

## Results

### Clinical evaluations

Among the 256 included patients, 183 were males (71.5%) and 73 females (28.5%). One hundred and two (39.84%) subjects had undergone kidney, and 154 (60.16%) liver transplant. Four patients had phototype I (1.57%), 67 phototype II (26.17%), 149 phototype III (58.20%), 33 phototype IV (12.89%) and 3 phototype V (1.17%). Six patients (2.34%) reported a family history of skin cancer, whereas in 89 patients (34.76%) was found at least one case of splanchnic or haematological tumour in their family. One hundred and fifty patients (58.59%) were smokers. Thirty-two (46.38%) patients reported history of viral infection.

About sun exposure, in the analyzed groups of patients, 172 (67.18%) had low, 54 (21.09%) medium and 30 (11.72%) high exposure during work, whereas 99 patients (38.67%) had low, 130 (50.78%) had medium and 27 (10.55%) had high exposure during spare time. Fifty-two patients (20.31%) had a history of sunburns, and among them, 3 (5.77%) had more than once. Patients were matched for phototype and sun exposure. No correlation was established between skin tumours and total amount of sun exposure or history of viral infection.

### Therapy received

All patients received different immunosuppressive systemic therapy in particular:

- 51 (19.92%) cyclosporine;
- 112 (43.75%) corticosteroids;
- 166 (64.84%) tacrolimus;
- 164 (64.06%) mycophenolate mofetil;
- 111 (43.35%) everolimus;
- 6 (2.34%) sirolimus

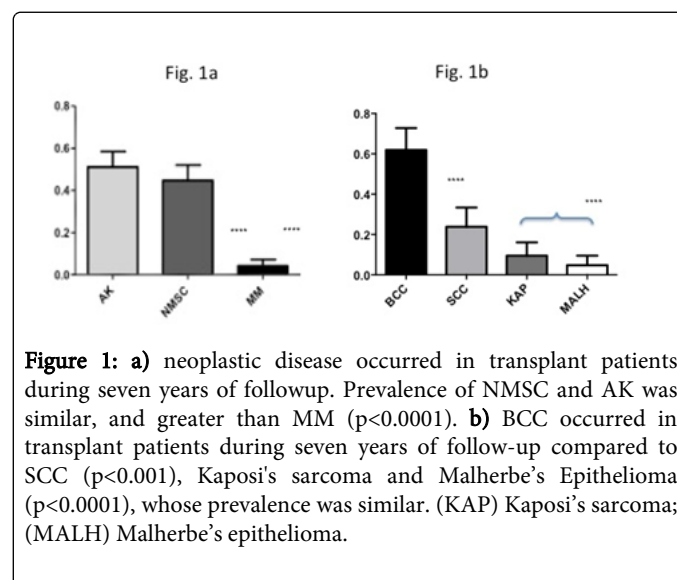
therapeutic regimen was classified as follows:

- 16 (6.25%) mono therapy;
- 133 (51.95%) dual therapy;
- 103 (40.24%) triple therapy;
- 4 (1.56%) quadruple therapy

### Neoplastic complications

Forty-seven patients out of 256 (18.36%) showed neoplastic complications: 24 (9.37%) presented AK, 21 (8.20%) NMSC and 2 (0.78%) MM. We compared the prevalence between AK, NMSC and MM and between different kinds of NMSC. In our population the prevalence of NMSC (8.20%) and AK (9.37%) was similar, and greater than MM (0.78%) ( $p < 0.0001$ ) (Figure 1a).

Of the twenty-one patients who developed NMSC 13 had basal cell carcinoma (61.90%), 5 had squamous cell carcinoma (23.81%), 2 had Kaposi's sarcoma (9.52%), and 1 had Malherbe's epithelioma (4.76%) (Figure 1b). In our series of patients, a statistically significant increase in the prevalence of BCC compared to SCC ( $p < 0.001$ ), and all other NMSC ( $p < 0.0001$ ), has been detected (Figure 1b).



**Figure 1:** a) neoplastic disease occurred in transplant patients during seven years of followup. Prevalence of NMSC and AK was similar, and greater than MM ( $p < 0.0001$ ). b) BCC occurred in transplant patients during seven years of follow-up compared to SCC ( $p < 0.001$ ), Kaposi's sarcoma and Malherbe's Epithelioma ( $p < 0.0001$ ), whose prevalence was similar. (KAP) Kaposi's sarcoma; (MALH) Malherbe's epithelioma.

### Therapy regimen

Was evaluated the prevalence of complications according to the immunosuppressive regimen as follows: cyclosporine, tacrolimus, steroids, mycophenolate mofetil or everolimus in single, dual, triple and quadruple therapy.

Sixteen of 256 (6.25%) patients had received monotherapy, the other 240 multipharmacological therapy: 133 of 240 (55.42%) received two drugs, 103 (40.24%) three drugs and 4 (1.56%) four drugs. Multidrug approach was based on corticosteroids and/or cyclosporine associated with one or more drug among tacrolimus, mycophenolate mofetil or everolimus.

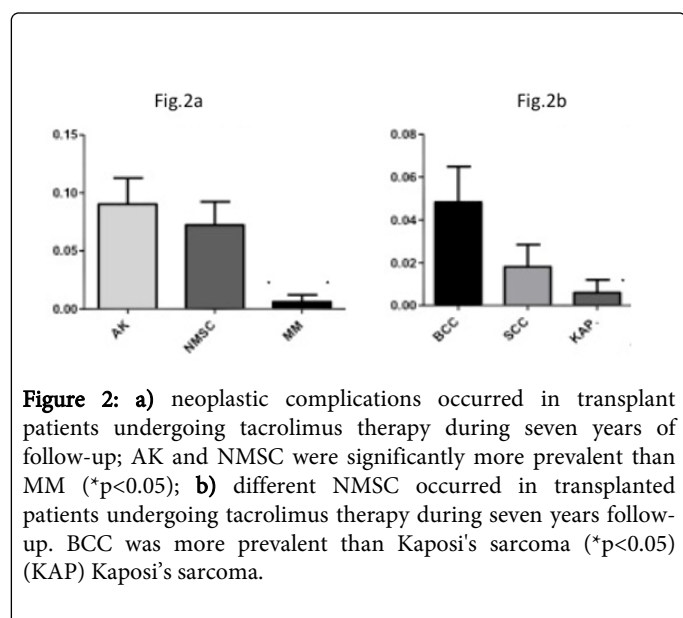
### Cyclosporine

Fifty-one patients (21.87%) were undergone to immunosuppressive regimen with cyclosporine. No significant difference was detected among neoplastic complications: 13.72% developed NMSC (7 cases),

1.96 % MM (1 case) and 11.76% AK (6 cases). Among NMSC, 4 cases of BCC (7.84%), 2 cases of SCC (3.92%), and 1 case of Malherbe's epithelioma (1.96%) and no case of Kaposi's sarcoma were detected, without any significant difference.

### Tacrolimus

One hundred and sixty-six patients (64.84%) had received immunosuppressive therapy with tacrolimus. In this population the prevalence of NMSC was 7.23% (12 cases), of MM 0.60% (1 case) and of AK 9.04% (5 cases). AK and NMSC were the most common neoplastic complications and they were significantly more prevalent ( $p < 0.05$ ) than MM (Figure 2a). The prevalence of BCC in this group was 4.82% (8 cases), SCC was 1.81% (3 cases) and Kaposi's sarcoma (1 case) was 0.60%. No case of Malherbe's epithelioma was detected. Among NMSC, the most common were BCC, whose prevalence was higher comparing with Kaposi's sarcoma ( $p < 0.05$ ) (Figure 2b).

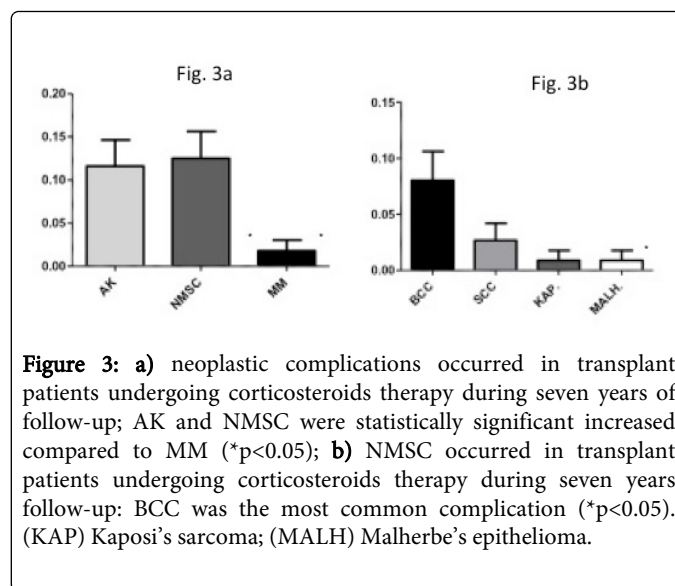


**Figure 2:** a) neoplastic complications occurred in transplant patients undergoing tacrolimus therapy during seven years of follow-up; AK and NMSC were significantly more prevalent than MM ( $*p < 0.05$ ); b) different NMSC occurred in transplanted patients undergoing tacrolimus therapy during seven years follow-up. BCC was more prevalent than Kaposi's sarcoma ( $*p < 0.05$ ) (KAP) Kaposi's sarcoma.

### Corticosteroids

Several patients (112 pz; 43.75%) had received steroid induction therapy which had been tapered off over a period of 6 months or integrated with other immunosuppressive therapies. Among one hundred and twelve patients, 12 had developed NMSC (10.7%), 1 MM (0.89%) and 13 AK (11.6%). Also in this group the most common neoplastic complications were AK and NMSC, whose prevalence was statistically significant increased comparing to MM ( $p < 0.05$ ) (Figure 3a).

In this population 8.03% had BCC (9 cases), 2.68% SCC (3 cases), and 0.89% for Kaposi's sarcoma and Malherbe's epithelioma (1 case). The prevalence of BCC was the greatest ( $p < 0.05$ ) with a statistically significant difference compared to Kaposi's sarcoma and Malherbe's epithelioma (Figure 3b).

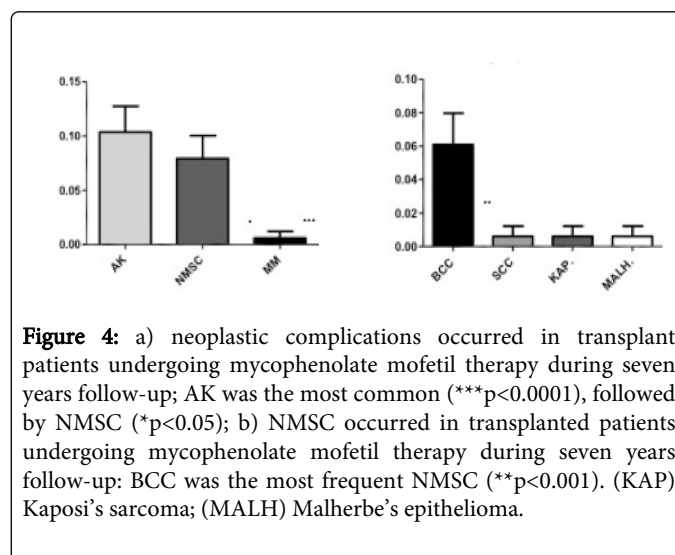


**Figure 3:** a) neoplastic complications occurred in transplant patients undergoing corticosteroids therapy during seven years of follow-up; AK and NMSC were statistically significant increased compared to MM ( $*p < 0.05$ ); b) NMSC occurred in transplant patients undergoing corticosteroids therapy during seven years follow-up: BCC was the most common complication ( $*p < 0.05$ ). (KAP) Kaposi's sarcoma; (MALH) Malherbe's epithelioma.

### Mycophenolate mofetil

One hundred and sixty-four patients (64.06%) had received immunosuppressive regimen with mycophenolate mofetil. Among patients undergoing this therapy, 7.31% developed NMSC (13 cases), 0.61 MM (1 case) and 10.37% AK [12]. As for the other therapies the prevalence of AK was the greatest ( $p < 0.0001$ ), followed by NMSC, which was more prevalent than the MM ( $p < 0.05$ ) (Figure 4a).

In this group the prevalence of BCC was 6.09 % (10 cases) and for each other NMSC (SCC, Kaposi's sarcoma and of Malherbe's epithelioma) was 0.61% (1 case for each) BCC was the most frequently observed NMSC and its prevalence was greater than the others ( $p < 0.001$ ) (Figure 4b).



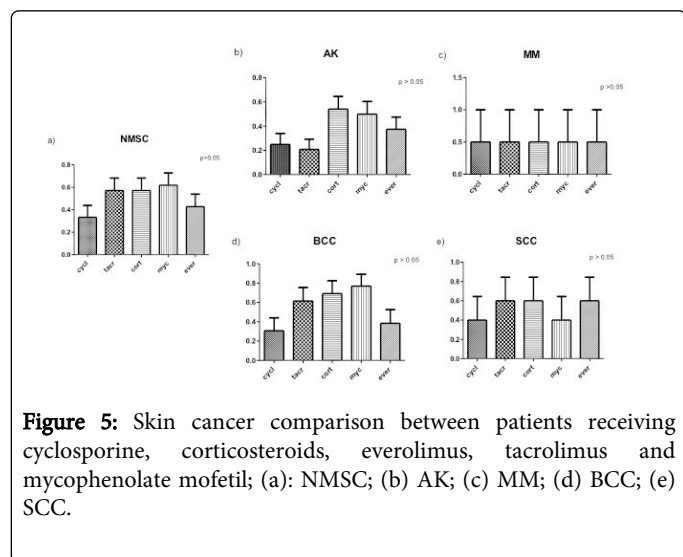
**Figure 4:** a) neoplastic complications occurred in transplant patients undergoing mycophenolate mofetil therapy during seven years follow-up; AK was the most common ( $***p < 0.0001$ ), followed by NMSC ( $*p < 0.05$ ); b) NMSC occurred in transplanted patients undergoing mycophenolate mofetil therapy during seven years follow-up: BCC was the most frequent NMSC ( $**p < 0.001$ ). (KAP) Kaposi's sarcoma; (MALH) Malherbe's epithelioma.

### Everolimus

One hundred and eleven (43.35%) patients were treated with Everolimus. Nine patients had NMSC (8.11%), 1 had MM (0.90%) and nine had AK (8.11%). Among the NMSC, were 5 cases of BCC (4.50%), 3 case of SCC (2.70%), and 1 case of Kaposi's sarcoma (0.90%)

%). No case of Malherbe's epithelioma. In this group, all the neoplastic skin lesions showed the same prevalence.

No significant difference in terms of skin cancers' prevalence was found among immunosuppressive regimens adopted (Figure 5).



**Figure 5:** Skin cancer comparison between patients receiving cyclosporine, corticosteroids, everolimus, tacrolimus and mycophenolate mofetil; (a): NMSC; (b) AK; (c) MM; (d) BCC; (e) SCC.

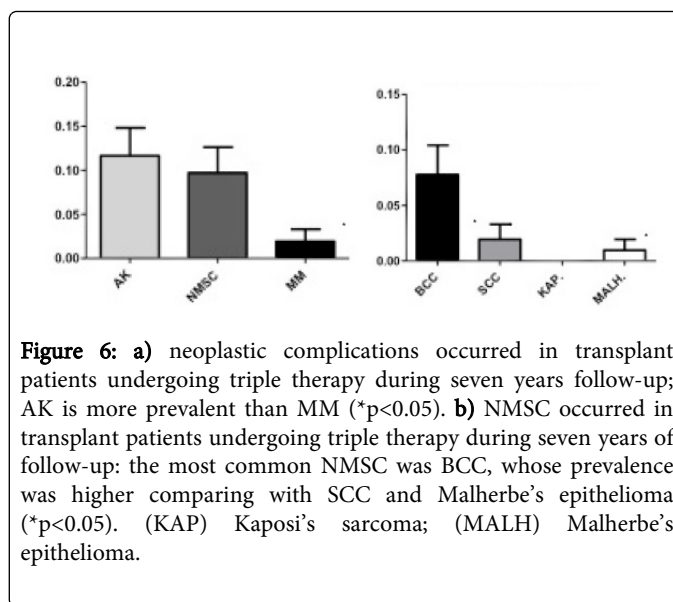
### Dual therapy

One hundred and thirty-three patients (51.95%) received dual immunosuppressive regimen. Six of them (4.51%) developed NMSC and 11 (8.27%) AK. No case of MM had been found.

In this population were only 3 case of BCC (2.25%) and 3 case of SCC (2.25%), no case of Kaposi's sarcoma and of Malherbe's epithelioma. There was no statistically significant difference comparing all these neoplastic skin lesions. Several therapeutic associations were administered: corticosteroid and everolimus (1 case of BCC and 1 case of SCC), corticosteroid and tacrolimus (1 case of SCC and 1 of AK), corticosteroid and mycophenolate mofetil (1 case of AK) cyclosporine and everolimus (2 case of AK), tacrolimus and everolimus (1 case of SCC and 2 of AK), tacrolimus and mycophenolate mofetil (2 case of BCC, 1 of SCC and 4 of AK) or everolimus and mycophenolate mofetil (1 case of AK). Different combinations of treatments did not influence the prevalence of skin cancer.

### Triple therapy

One hundred and three patients had received triple immunosuppressive therapy. In this group, the prevalence of NMSC was 10.68% (11 cases), of MM was 1.94% (2 cases) and of AK was 11.65% (12). In this group only the AK had a prevalence statistically significant compared to MM with ( $p < 0.05$ ) (Figure 6a). In this population, we had 8 case of BCC (7.77%), 2 case of SCC (1.94%) and 1 case of Malherbe's epithelioma (0.97%). No case of Kaposi's sarcoma. The most common NMSC was BCC, whose prevalence was higher comparing with SCC ( $p < 0.05$ ), and Malherbe's epithelioma ( $p < 0.05$ ) (Figure 6b).



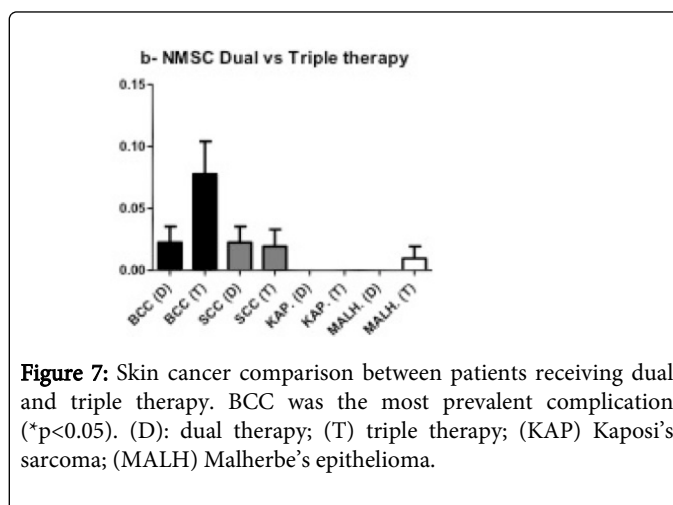
**Figure 6:** a) neoplastic complications occurred in transplant patients undergoing triple therapy during seven years follow-up; AK is more prevalent than MM ( $*p < 0.05$ ). b) NMSC occurred in transplant patients undergoing triple therapy during seven years of follow-up: the most common NMSC was BCC, whose prevalence was higher comparing with SCC and Malherbe's epithelioma ( $*p < 0.05$ ). (KAP) Kaposi's sarcoma; (MALH) Malherbe's epithelioma.

Different combinations of treatments were given: cyclosporine, corticosteroid and everolimus (1 case of BCC, 1 of SCC, 3 of AK, 1 of Malherbe's epithelioma and 1 of MM), cyclosporine, mycophenolate mofetil and everolimus (2 case of AK) or corticosteroid, tacrolimus and mycophenolate mofetil (7 case of BCC, 1 of SCC, 7 of AK and 1 of MM). There was no correlation between different prevalence of skin cancers and various therapeutic associations.

No evaluation was conducted on patients treated with mono or quadruple therapy due to the small size of the samples.

### Dual vs triple

The prevalence for each neoplastic complication and among the NMSC was compared between patients receiving dual and triple immunosuppressive regimen. All lesions had the same prevalence between the two populations, except for BCC, whose prevalence was relatively higher in patients receiving triple therapy, 8 cases (7.77%) compared to dual therapy 3 cases (2.25%) ( $p < 0.05$ ) (Figure 7).



**Figure 7:** Skin cancer comparison between patients receiving dual and triple therapy. BCC was the most prevalent complication ( $*p < 0.05$ ). (D): dual therapy; (T) triple therapy; (KAP) Kaposi's sarcoma; (MALH) Malherbe's epithelioma.

Moreover, the prevalence for all skin neoplastic complications (AK, NMSC, MM), and among NMSC: BCC, SCC, Kaposi's sarcoma, Malherbe's epithelioma was assessed and compared for each



immunosuppressive regimen (cyclosporine, tacrolimus, steroid, mycophenolate mofetil and everolimus), without any significant difference.

## Discussion and conclusions

Transplant recipients have an increased risk to develop skin neoplastic complications compared with general population [10,11]. All immunosuppressive treatments may impair the immune system network of cells and cytokines in the skin and may increase the risk of skin cancer [12].

Cyclosporine and tacrolimus inhibit the activation and proliferation of T cells by reducing IL-2 production; mycophenolate mofetil inhibits de novo purine synthesis and lymphocyte proliferation; corticosteroids lead to a reduction of neutrophil chemotaxis, antigen presentation, T cell activation and proliferation, and macrophage function [13].

In this study, among skin complications actinic keratoses were the most common encountered lesions (9.37%) followed by non melanoma skin cancer (8.20%) and melanoma (0.78%).

All patients had received surgical excision of the neoplasms and the survival rate with respect to these neoplasms was 100% at 10 years. The onset of cancer had peak of incidence between the 1st and the 3rd year after transplantation. No relationship between the timing of the development of skin cancer and cancer type was found.

According to data from literature, this study had underlined an increased prevalence of developing NMSC (8.20%) compared to melanoma (0.78%). However, the ratio between BCC and SCC was different in our group of patients: although the most part of the reported studies suggest a higher prevalence of SCC in transplant patients [12], our results showed an inverse proportion between BCC and SCC prevalence.

The rate of prevalence between SCC and BCC was reported by several studies conducted in Ireland, Czech Republic and Australia [14]. Particularly, Buell et al. [15] reported a rate 1.9:1; Molina B.D. [16] and Secnikova et al. [17] 1.6:1. Conversely, other authors, Naldi L et al. [18], and Fuente MJ et al. [19] have reported an inverse rate between BCC and SCC, as our results confirm (2.6:1).

Although this trend could probably reflect differences in genetic background, skin phototype and sun exposure at different latitudes in populations of patients included into the reported studies.

Even if the most part of the literature agrees in considering sun exposure an independent risk factor for MNSC [20,21] in transplanted patients, as demonstrated by the greater prevalence of NMSC in sun-exposed area. Particularly, Belloni-Fortina A et al. [5] reported a higher incidence in patients with phototype II-III (73.91%) as compared to patients with phototype IV-V (26.08%) ( $p < 0.05$ ).

Also any we failed to demonstrate a significant correlation between total amount of sun exposure and prevalence of skin cancer in our population. However the relationship between sun exposure and skin cancer is difficult to evaluate owing to the risk of bias in clinical data collected retrospectively.

Finally, no relationship was established between prevalence of clinically relevant viral infection and the emergence of skin cancer in our population. Data obtained on investigated neoplastic complications were similar for each immunosuppressive regimen

adopted: AK, NMSC and MM do not appear to have been influenced from neither the number nor the type of drug used.

Moreover, the prevalence of neoplastic lesions seems not to be influenced by the type of immunosuppressive drug used since no differences have been detected by comparing the different therapeutic regimens. The same data was reported in the Italian study of Savoia P et al [22] while opposite results were highlighted in the work of Belloni-Fortina A et al [5].

Interestingly, the development of BCC increases in patients receiving triple therapy compared to dual therapy, thus dermatologists should be aware that by increasing from dual to triple immunosuppressive therapy, the risk of BCC could increase for transplant patients.

In conclusion, this study confirms that the transplant patients are at higher risk of neoplastic skin complications regardless of the quantity and quality of immunosuppressive regimen adopted. A multidisciplinary approach, with strict dermatologic follow-up should be recommended for this set of patients.

## References

1. Starzl TE (2000) History of clinical transplantation. *World J Surg* 24: 759-782.
2. Thölking G, Fortmann C, Koch R, Gerth HU, Pabst D, et al. (2014) The tacrolimus metabolism rate influences renal function after kidney transplantation. *PLoS One* 9: e111128.
3. Chen H, Chen B (2014) Clinical mycophenolic acid monitoring in liver transplant recipients. *World J Gastroenterol* 20: 10715-10728.
4. Ganschow R, Pollok JM, Jankofsky M, Junge G (2014) The role of everolimus in liver transplantation. *Clin Exp Gastroenterol* 7: 329-343.
5. Belloni-Fortina A, Piaserico S, Bordignon M, Gambato M, Senzolo M, et al. (2012) Skin cancer and other cutaneous disorders in liver transplant recipients. *Acta Derm Venereol* 92: 411-415.
6. Perera GK, Child FJ, Heaton N, O'Grady J, Higgins EM (2006) Skin lesions in adult liver transplant recipients: a study of 100 consecutive patients. *Br J Dermatol* 154: 868-872.
7. Lober B, Lober C, Accola J (2000) Actinic keratoses is squamous cell carcinoma. *South Med J* 93: 650-655.
8. Heaphy MR Jr, Ackerman AB (2000) The nature of solar keratosis: a critical review in historical perspective. *J Am Acad Dermatol* 43: 138-150.
9. Pham TQ, Rochtchina E, Mitchell P, Smith W, Wang JJ (2009) Sunlight-related factors and the 10-year incidence of age-related maculopathy. *Ophthalmic Epidemiol* 16: 136-141.
10. Berg D, Otley CC (2002) Skin cancer in organ transplant recipients: Epidemiology, pathogenesis, and management. *J Am Acad Dermatol* 47: 1-17.
11. Tessari G, Girolomoni G (2012) Nonmelanoma skin cancer in solid organ transplant recipients: update on epidemiology, risk factors, and management. *Dermatol Surg* 38: 1622-1630.
12. Tepeoğlu M, Ayva Ş, Ok Atılgan A, Tunca MZ, Özdemir BH, et al. (2014) Nonmelanoma skin cancer after kidney transplant. *Exp Clin Transplant* 12: 233-237.
13. Halloran PF, Leung S (1998) Approved immunosuppressants. In: Norman EJ, Suki WN (eds). *Primer on Transplantation*. American Society of Transplant Physicians, Thorofare, NJ.
14. Moloney FJ, Comber H, O'Lorcain P, O'Kelly P, Conlon PJ, et al. (2006) A population-based study of skin cancer incidence and prevalence in renal transplant recipients. *Br J Dermatol* 154: 498-504.
15. Buell JF, Hanaway MJ, Thomas M, Alloway RR, Woodle ES (2005) Skin cancer following transplantation: the Israel Penn International Transplant Tumor Registry Experience. *Transplantation Proceedings* 37: 962-963.

16. Molina BD, Leiro MG, Pulpón LA, Mirabet S, Yañez JF, et al. (2010) Incidence and risk factors for nonmelanoma skin cancer after heart transplantation. *Transplant Proc* 42: 3001-3005.
17. Zuzana Secnikova D, Gopfertova L, Hoskovac J, Hercogova M, Dzambova A et al. (2015) Significantly higher incidence of skin cancer than other malignancies in patients after heart transplantation. A retrospective cohort study in the Czech Republic *Biomed Pap Med Fac Univ Palacky Olomouc Czech Repub*.
18. Naldi L, Fortina AB, Lovati S, Barba A, Gotti E, et al. (2000) Risk of nonmelanoma skin cancer in Italian organ transplant recipients. A registry-based study. *Transplantation* 70: 1479-1484.
19. Fuente MJ, Sabat M, Roca J, Lauzurica R, Fernández-Figueras MT, et al. (2003) A prospective study of the incidence of skin cancer and its risk factors in a Spanish Mediterranean population of kidney transplant recipients. *Br J Dermatol* 149: 1221-1226.
20. Rodríguez-Acosta ED, Calva-Mercado JJ, Alberú-Gómez J, Vilatoba-Chapa M, Domínguez-Cherit J (2015) Patients with solid organ transplantation and skin cancer: determination of risk factors with emphasis in photoexposure and immunosuppressive regimen. Experience in a third level hospital. *Gac Med Mex* 151: 20-26.
21. Sułowicz J, Wojas-Pelc A, Ignacak E, Betkowska-Prokop A, Kuzniewski M, et al. (2014) [Risk factors of non melanoma skin cancers in kidney transplant patients]. *Przegl Lek* 71: 19-25.
22. Savoia P, Stroppiana E, Cavaliere G, Osella-Abate S, Mezza E, et al. (2011) Skin cancers and other cutaneous diseases in renal transplant recipients: a single Italian center observational study. *Eur J Dermatol* 21: 242-247.