

Neoadjuvant use of Tyrosine Kinase Inhibitors

Mariano Provencio Pulla*, Antonio Sánchez Ruiz, Magda Palka Kotlowsk and Miriam Méndez Garcia

Medical Oncology Department, Puerta de Hierro Hospital, Madrid, Spain

*Corresponding Author: Mariano Provencio Pulla, Puerta de Hierro Hospital, Calle Manuel de Falla, 128222, Majadahonda, Madrid, Spain, Tel: 003491191416280; Fax: 0034 91 191 6671; E-mail: mprovencio@gmail.com

Rec date: Jul 14, 2014, Acc date: Aug 20, 2014, Pub date: Aug 27, 2014

Copyright: © 2014 Pulla MP et al. This is an open-access article distributed under the terms of the Creative Commons Attribution License, which permits unrestricted use, distribution, and reproduction in any medium, provided the original author and source are credited.

Introduction

Patients with clinical stage IIIA-N2 non-small cell lung cancer (NSCLC) have a 5-year overall survival (OS) of only 10%-15%, and it decreases to 2-5% in patients with mediastina N2 bulky disease. The efficacy of surgery in this stage is limited and remains controversial. In 4 different studies with a total of 1180 patients who underwent surgical resection, 5-year survival was 14-30% [1-4]. To improve this rate and supported by the introduction of new chemotherapeutic agents, induction chemotherapy (CT) has been added to the treatment approach in this stage. The theoretical advantages of induction CT include: in vivo assessment of response to CT, which would help identify patients who might benefit from adjuvant CT; early treatment of micro metastasis to increase control of distant metastases; reduction of drug resistance due to early exposure to chemotherapeutic agents and increased surgical resect ability, due to enhance of response rates that also allows preservation of healthy lung parenchyma.

Induction CT is a standard treatment accepted in IIIA stage which has shown survival increase in patients with inoperable stage III NSCLC; however, response and survival rates remain very unsatisfactory.

Selection of treatment for stage IV patients has evolved rapidly in recent years, as we can see in the identification of activating mutations and response to EGFR inhibitors [5]. ALK translocation for selecting crizotinib and treatment with pemetrexed in patients with non-squamous histology [6]. They have shown a change in prognosis and an increase in survival. However, these new options of treatments have not been transferred to patients with stage III NSCLC, who are still receiving platinum-based doublets CT, without further treatment selection [7].

In this small series we present our experience and review the use of new treatments in stage III disease.

Case Report

We present 3 cases of patients diagnosed with stage IIIA non-small cell lung cancer, non-resectable at the moment of diagnosis. See Table I for summary of patient's characteristics and evolution.

Patient Gender Age	Stage at diagnosis	Induction CT	EGFR mutation	Response to induction CT	Response to TKI and pTNM	Evolution
P1 Female 65 y	T2aN2M0 IIIA	Cisplatin + vinorelbine 3 cycles	Exon 19 deletion	Stable disease	ypT1aN1M0 IIA	Received adjuvant treatment with erlotinib for 7 months (suspended because of toxicity grade 2). Relapsed 14 months after surgery, and is now treated with afatinib.
P2 Female 64 y	T4N2M0 IIIB	No	Exon 19 deletion	No applicable	ypT3N2M0 IIIA	Received 4 cycles of adjuvant carboplatin AUC 5 + paclitaxel. Relapsed 15 months after surgery and she is now treated with gefitinib with good response to treatment.
P3 Male 70 y	T2aN2M0 IIIA	Cisplatin + vinorelbine 3 cycles	Exon 19 deletion	Stable disease	ypT2aN2M0 IIIA	Received radical radiotherapy and erlotinib for 2 months, suspended because of toxicity. Since surgery in may 2013, the patient is disease free.

Table 1: Patients characteristics and evolution since initiation of treatment

These are 2 women (patients 1 and 2) and a man (patient 3); between 64 and 70 years old, diagnosed with stage IIIA and IIIB lung adenocarcinoma between October 2010 and August 2012. Patients 1 and 3 were treated with neo adjuvant cisplatin plus vinorelbine regimen, with a stable disease response assessed by PET/CT after 3 cycles of induction chemotherapy. Patient 2 did not receive induction

CT because she was diagnosed in a different hospital with stage IIIB NSCLC, and her clinical situation did not guarantee enough time to proceed with the neo adjuvant treatment and made her more suitable for TKIs treatment. The fact that there was no shrinkage of the tumor, confirmed the non-respectability of the lesions, so analysis of EGFR mutations was performed using Cobas test and was positive in all of

the patients for exon 19 deletion. patients 1 and 3 received erlotinib and patient 2 was treated with gefitinib. This difference in the treatment was made because we understand that both treatment regimens have similar results as used in metastatic and therefore in neo adjuvant setting, without any expense on the efficiency of the treatment.

After 30 days of treatment, a PET/CT was performed in to assess the clinical response (Figure 1).

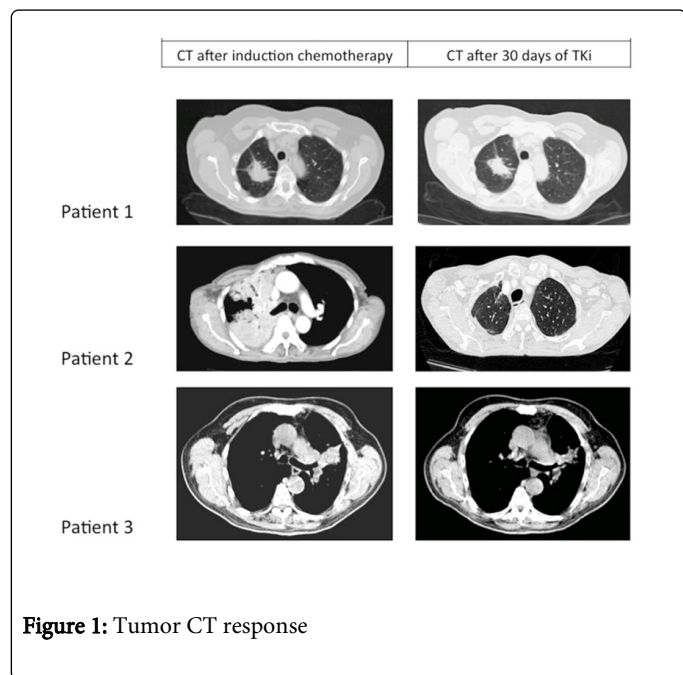


Figure 1: Tumor CT response

Down staging was achieved pathologically in 2 patients (patient 1 and 3) and clinically in one of them (patient 2), so they underwent surgery, and it was on the surgical specimen where the response to treatment with TKIs was assessed. Patient 1 passed from stage IIIA at diagnosis to stage IIA, and patient 2 passed from stage IIIB at diagnosis to stage IIIA. At the restaging moment, patient 3 had stable disease on the PET/CT but pathologically negative mediastina lymph nodes when bronchoscopy was made. He received 30days of erlotinib and underwent surgery. Although there was no down staging when surgical specimen was analysed, the piece had over 50% of necrosis.

After surgery, all of three patients received adjuvance: patient 1 was treated with erlotinib for 2 months, and suspended it because of grade 2 toxicity. She relapsed locally and with brain metastasis in March 2014 after 14 months of disease free survival. She is being treated with afatinib with good response. Patient 2 received 4 cycles of carboplatin AUC5 and paclitaxel, and was disease free for 15 months, when she relapsed with brain metastasis and is receiving treatment with gefitinib, with good control of the disease since May 2012. Patient 3 received adjuvant radiotherapy with 54Gy because the surgical specimen showed pleural involvement, and initiated erlotinib for 2 months. Erlotinib was suspended in November 2013 because of grade 2 asthenia, anorexia and diarrhoea. He remains disease free until today.

Discussion

Neo adjuvant treatment has gained acceptance in stage IIIB-IV NSCLC because of the results of several clinical trials suggesting that it

increases the OS of these patients [8-11]. As distant metastases remain the most common form of relapse, it is likely that more active cytotoxic drugs or other anticancer agents may be necessary to increase the response rate and survival. All studies of patients with EGFR mutations show a double response rate with TKI when compared to chemotherapy. This is the main point of interest of neo adjuvant treatments where complete surgical resection [12-13]. Tumor down staging and pathological complete response is predictive factors for long-term survival. Pathologic complete response after induction chemotherapy varies between 0 and 9.5%. A phase II study of preoperative gefitinib in clinical stage I NSCLC, in EGFR mutant patients showed extensive fibrotic changes (mean: 32.8% of tumor area), and significantly lower cellularity (mean:24.2% of tumor area) and Ki-67 proliferative index(mean:4.6%)compared to wild type EGFR adenocarcinoma (cellularity 58.6%,p=0.01,Ki-67:31.4%,p=0.002) and non- adenocarcinoma tumors (cellularity 55%,p=0.026, Ki-67:49.8%,p=0.001) [14]. Similar information showed in another study in resected disease from an enriched population (never-smoker, female sex, non-squamous histology, or Asian ethnicity). Pathologic examination showed more than 50% necrosis in 14 patients (23%), three (5%) of whom had more than 95% tumor necrosis. The response rate in the enriched population was 34% (10 of 29 patients).

Another theoretical benefit of using neo adjuvant TKI in selected patients with EGFR mutation would be the possibility of an early evaluation. In our 3 cases, the response was obtained within 30 days of treatment. Other aspect to consider is the tolerability of these treatments. Patients older than 70 years may have problems with treatment tolerance (platinum-doublet chemotherapy) [15]. One of our patients was older than 70 year old, and he could receive sequential treatment with TKI after stabilization with chemotherapy. As he did not have toxicity after induction treatment, surgical resection was performed, also without complications. We would like to underline that none of the patients interrupted the treatment in the first 20 days, when the response evaluation must be done, so we think that a short course of TKIs is feasible, safe and does not lead to treatment interruption. The maintained treatment in adjuvant or metastatic setting is associated to toxicities that can lead to the interruption of the TKIs treatment as happened after several months with two of our patients.

Neo adjuvant use of EGFR-TKIs in mutated patients has been reported only anecdotally so far [16-20]. In 2 of our cases, there is a special feature that makes it much more informative and not previously described. They were treated with chemotherapy doublets, one with cisplatin and pemetrexed, to obtain greater response optimization. In both, a short course of 20 days of TKI treatment was used. Because of the short duration it did not interfered in the patient treatment, if there had been no progression or response to treatment with definitive chemo radiotherapy. It remains questionable whether to apply adjuvant treatment with these compounds might be relevant. The NCIC Clinical Trials Group BR.19 study randomized 503 patients with resected stage IB-III A NSCLC to oral gefitinib 250 mg daily for 2 years or to placebo [21]. Overall survival trended in favour of placebo (hazard ratio:1.23; p=0.136), and patients with EGFR wild-type (hazard ratio:1.21;p=0.301) and EGFR mutation (hazard ratio:1.58; p=0.16) experienced non significantly worse survival on gefitinib, however this is not a large number of patients.

New studies should be done in selected populations to explore this approach, but it seems logical that in selected populations with EGFR mutation the results of advanced stages should be reproduced.

References

1. Martini N, Flehinger BJ (1987) The role of surgery in N2 lung cancer. *Surg Clin North Am* 67: 1037-1049.
2. Watanabe Y Shimizu J, Oda M, Hayashi Y, Watanabe S, et al. (1991) Aggressive surgical intervention in N2 non-small cell cancer of the lung. *Ann Thorac Surg* 51: 253-261.
3. Naruke T Goya T, Tsuchiya R, Suemasu K (1988) The importance of surgery to non-small cell carcinoma of lung with mediastinal lymph node metastasis. *Ann Thorac Surg* 46: 603-610.
4. Mountain CF (1990) Expanded possibilities for surgical treatment of lung cancer: survival in stage IIIA disease. *Chest* 97: 1045-105.
5. Rosell R Moran T, Queralt C, Porta R, Cardenal F, et al. (2009) Screening for epidermal growth factor receptor mutations in lung cancer. *N Engl J Med* 361: 958-967.
6. Malik SM Maher VE, Bijwaard KE, Becker RL, Zhang L, et al. (2014) U.S. Food and Drug Administration approval: crizotinib for treatment of advanced or metastatic non-small cell lung cancer that is anaplastic lymphoma kinase positive. *Clin Cancer Res* 20: 2029-2034.
7. Scagliotti GV Parikh P, von Pawel J, Biesma B, Vansteenkiste J, et al. (2008) Phase III study comparing cisplatin plus gemcitabine with cisplatin plus pemetrexed in chemotherapy-naive patients with advanced-stage non-small-cell lung cancer. *J Clin Oncol* 26: 3543-3551.
8. Rosell R Gómez-Codina J, Camps C, Maestre J, Padille J, et al. (1994) A randomized trial comparing preoperative chemotherapy plus surgery with surgery alone in patients with non-small-cell lung cancer. *N Engl J Med* 330: 153-158.
9. Skarin A Jochelson M, Sheldon T, Malcolm A, Oliynyk P, et al. (1989) Neoadjuvant chemotherapy in marginally resectable stage III M0 non-small cell lung cancer: long-term follow-up in 41 patients. *J Surg Oncol* 40: 266-274.
10. Faber LP Kittle CF, Warren WH, Bonomi PD, Taylor SG 4th, et al. (1989) Preoperative chemotherapy and irradiation for stage III non-small cell lung cancer. *Ann Thorac Surg* 47: 669-675.
11. Pass HI Pogrebniak HW, Steinberg SM, Mulshine J, Minna J (1992) Randomized trial of neoadjuvant therapy for lung cancer: interim analysis. *Ann Thorac Surg* 53: 992-998.
12. Sugarbaker DJ, Herdon J, Kohman LJ (1995) Results of cancer and leukemia group B protocol 8935: A multi-institutional phase II trimodality trial for stage IIIA (N2) non-small-cell lung cancer-Cancer and Leukemia Group B Thoracic Surgery Group. *J Thorac Cardiovasc Surg* 109: 473-485.
13. Kirn DH Lynch TJ, Mentzer SJ, Lee TH, Strauss GM, et al. (1993) Multimodality therapy of patients with stage IIIA, N2 non-small-cell lung cancer. Impact of preoperative chemotherapy on resectability and downstaging. *J Thorac Cardiovasc Surg* 106: 696-702.
14. Schaake EE Kappers I, Codrington HE, Valdés Olmos RA, Teertstra HJ, et al. (2012) Tumor response and toxicity of neoadjuvant erlotinib in patients with early-stage non-small-cell lung cancer. *J Clin Oncol* 30: 2731-2738.
15. Provencio M Camps C, Alberola V, Massutti B, Viñolas N, et al. (2009) Lung cancer and treatment in elderly patients: the Achilles Study. *Lung Cancer* 66: 103-106.
16. Ong M Kwan K, Kamel-Reid S, Vincent M (2012) Neoadjuvant erlotinib and surgical resection of a stage IIIA papillary adenocarcinoma of the lung with an L861Q activating EGFR mutation. *Curr Oncol* 19: e222-226.
17. Takamochi K Suzuki K, Sugimura H, Funai K, Mori H, et al. (2007) Surgical resection after gefitinib treatment in patients with lung adenocarcinoma harboring epidermal growth factor receptor gene mutation. *Lung Cancer* 58: 149-155.
18. Kappers I Klomp HM, Burgers JA, Van Zandwijk N, Haas RL, et al. (2008) Neoadjuvant (induction) erlotinib response in stage IIIA non-small-cell lung cancer. *J Clin Oncol* 26: 4205-4207.
19. Marech I, Vacca Angelo, Gnoni A, Silvestris N, Lorusso V (2013) Surgical resection of locally advanced epidermal growth factor receptor (EGFR) mutated lung adenocarcinoma after gefitinib and review of the literature. *Tumori* 99: e241-e244.
20. Wang Q Wang H, Li P, Zhu H, He C, et al. (2010) Erlotinib-based perioperative adjuvant therapy for a case of unresectable stage IIIA (N2) non-small cell lung cancer. *Am J Med Sci* 340: 321-325.
21. Goss GD O'Callaghan C, Lorimer I, Tsao MS, Masters GA, et al. (2013) Gefitinib versus placebo in completely resected non-small-cell lung cancer: results of the NCIC CTG BR19 study. *J Clin Oncol* 31: 3320-3326.