

In-vitro Tests Suitability in Severe Systemic Reaction due to Several Drugs

Dario Antolin-Amerigo^{1*}, Maria Luisa Sanz², Lucienne Costa-Frossard França³, Teresa Caballero Molina⁴, Pernila Tirado Zambrano⁵, Rosario Carrillo Gijón⁶, Ingrid Rocío Aguayo Leiva⁷ and Belen de La Hoz Caballer⁸

¹Allergy Division, Hospital Universitario Ramon y Cajal, Madrid, Spain

²Department of Allergology & Clinical Immunology, University Clinic of Navarra, Pamplona, Spain

³Neurology Department, Hospital Universitario Ramon y Cajal, Madrid, Spain

⁴Allergy Department, Hospital La Paz Health Research Center, Madrid, Spain

⁵Department of Pathology Service, Hospital Universitario Ramon y Cajal, Madrid, Spain

⁶Department of Pathology Service, Hospital Universitario Ramon y Cajal, Carretera de Colmenar Km, Madrid, Spain

⁷Department of Dermatology Service, Hospital Universitario Ramon y Cajal, Madrid, Spain

⁸Allergy Division, Hospital Universitario Ramon y Cajal, Madrid, Spain

Abstract

Background: Toxic-Epidermal-Necrolysis might be a severe delayed reaction to drugs, so *in-vitro* assessment could be suitable. To date there are not validated diagnostic procedures for such cases.

Methods: A 33 year-old female suffering from Multiple-Sclerosis (MS) was receiving Beta1a-Interferon from the last 2.5 months, Deflazacort 1 month and Ibuprofen occasionally. She consulted the emergency department due to confluent dianiform maculae, denuding blisters and subsequent systemic symptoms which led to toxic epidermal necrolysis after skin biopsy result. Cyclosporine, Prednisone, Zinc-Sulfate baths and complete discontinuation of implicated medication achieved total symptom relief. A Basophil Activation Test (BAT) and Lymphocyte-Transformation-Test (LTT) were carried out using Beta1a-Interferon, Deflazacort and Ibuprofen at different dilutions for each culprit medication (1/1, 1/10, 1/10², 1/10³). Glatiramer-Acetate (GA) hasn't been reported as TEN/SJS cause, therefore neurology-department considered it as a secure alternative to Beta-1a-Interferon so it was *in-vitro* assessed likewise.

Results: BAT and LTT results were inconclusive. In vivo tests: Intradermal test to GA at progressive dilutions (1/1, 1/10, 1/10², 1/10³, 1/10⁴, 1/10⁵) resulted negative. Oral Challenge Tests to Acetaminophen-1 mg, Prednisone-30 mg and 1-gram Intravenous Methyl-prednisolone resulted negative.

Conclusion: Up-to-date cutaneous lesions limited to injection sites have been reported following Beta-1a interferon treatment but the former had not been involved in a widespread reaction yet. We present a rare case of TEN due to several drugs in which *in-vitro* tests have been unhelpful, to manage this condition. Further studies would be helpful to clarify its suitability, mainly in immunomodulating medication.

Keywords: Epidermal necrolysis; Toxic; Multiple sclerosis; Interferon-beta; Neurology; Drug hypersensitivity

Introduction/Background

Toxic Epidermal Necrolysis (TEN) is a rare but life-threatening cutaneous eruption with systemic features mainly caused by drugs in which there is at least 30% of skin detachment so *in-vitro* assessment might be useful to avoid insecure drug challenges [1]. Most reactions occur among the first eight weeks of treatment. Infection, vaccination and graft-versus-host disease are additional causes [2].

Materials and Methods

A 33 year-old female suffering from relapsing-remitting Multiple-Sclerosis was receiving Beta1a-Interferon during the last 2.5 months, Deflazacort 1 month and Ibuprofen occasionally due to Beta1a-Interferon flu-like side effects. She was referred from Dermatology department due to erythematous, confluent morbilliform maculae beginning at her neckline and thorax subsequently spreading to palm-plantar and extremities regions accompanied by denuding blisters which began the previous week (Figure 1 and Figure 2). By that time she consulted the Emergency-Department (ER) due to dianiform erythematous macules spread over the cervicothoracic region but was discharged after emollient treatment recommendations. She visited our ER three days later because malaise, fever, cough, arthromyalgia were becoming patent, while generalized epidermal sloughing and mucositis appeared. Physical examination showed positive Nikolsky sign, Superficial Punctate-Keratitis and evident perionyxis. A skin

biopsy performed on a dianiform erythematous lesion showed intense hydropic degeneration at the basal layer and numerous apoptotic keratinocytes in the epidermis. A moderate lymphocytes infiltrate was present in the papillary dermis: Compatible diagnosis for TEN (Figure 3). Serology was negative to HIV, HHV 1, HHV 2, HHV-6, Hepatitis B and C Virus. IgG-CMV and IgG-EBV resulted positive. All complementary Laboratory tests were normal including mycoplasma pneumoniae, borrelia, brucella and syphilis.

Cyclosporine 200 mg/24 hours, Prednisone 50 mg/24 hours on a tapering basis, Zinc-Sulphate baths and complete discontinuation of the implicated medication achieved total symptom relief in two weeks, although the patient showed disturbed pigmentation of the former cutaneous lesions during several months. Neurology-Department

*Corresponding author: Dario Antolin-Amerigo, Allergy Division, Hospital Universitario Ramon y Cajal, Madrid, Spain, Tel: 34 661715681; Fax: 34- 91-3368624; E-mail: dario.antolin@gmail.com

Received October 27, 2011; Accepted March 21, 2012; Published March 26, 2012

Citation: Antolin-Amerigo D, Sanz ML, Costa-Frossard França L, Molina TC, Zambrano PT, et al. (2012) *In-vitro* Tests Suitability in Severe Systemic Reaction due to Several Drugs. J Clin Exp Dermatol Res S2:005. doi:10.4172/2155-9554.S2-005

Copyright: © 2012 Antolin-Amerigo D, et al. This is an open-access article distributed under the terms of the Creative Commons Attribution License, which permits unrestricted use, distribution, and reproduction in any medium, provided the original author and source are credited.

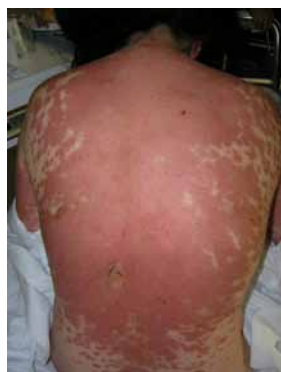

Figure 1: Erythematous at neckline and thorax.

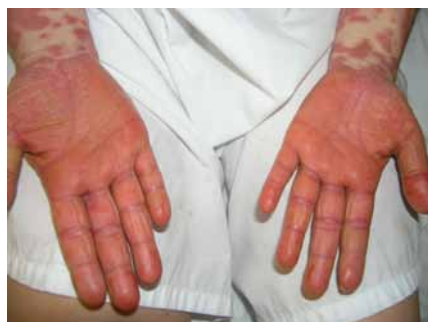

Figure 2: Erythematous at palm plantar and extremities regions.

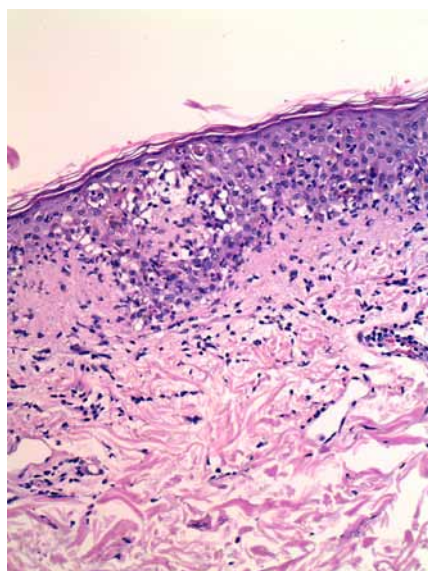


Figure 3: Histological picture of the skin biopsy showing intense vacuolar change at the dermo-epidermal junction. Numerous necrotic keratinocytes are evident within and above the basal layer.

referred the patient to our Allergy Division to perform allergological studies. Allergy study was performed after informed consent: A Basophile activation Test (BAT) and Lymphocyte-Transformation-Test (LTT) were carried out in order to elucidate the etiology of this complex Syndrome. These techniques were carried out using the drugs implicated in the reaction: Beta1a-Interferon, Deflazacort and

Ibuprofen. Glatiramer-Acetate (GA) shifts the population of T-cells from pro-inflammatory Th1-cells to regulatory Th2-cells, considered a suitable treatment instead of Interferon, was also tested. Different dilutions for each medication (1/1,1/10,1/10²,1/10³) were tested. LTT was also performed using Pichler's recommendations [3].

Results

Basophil Activation Test and Lymphocyte Transformation Test results were inconclusive. *In vivo* tests: We performed intradermal test to GA at progressive dilutions (1/1,1/10,1/10²,1/10³,1/10⁴,1/10⁵) resulting negative. Due to the severity of the reaction only alternative drugs were tested. Oral Challenge Tests to Acetaminophen 1 mg, Prednisone 30 mg and 1-gram Intravenous Methyl-prednisolone (MP) (to point out that MP is a first-election drug in Multiple-Sclerosis attacks as indicated by Neurology-Department), were performed in separate days and resulted negative in all of challenges.

As TEN might be a severe delayed reaction to drugs, *in-vitro* assessment (LTT and/or BAT) could be valuable alternatives. Kim et al. [4] reported a TEN case in which Deflazacort and Enalapril were the causative drugs. As they report it is extremely difficult to identify the culprit drug based on the patients' drug history, particularly in cases in which multiple medication is involved, however to date there are not validated diagnostic procedures for such cases, so diverse complementary tools are objects of current research [5]. Ibuprofen has previously been related to Stevens - Johnson syndrome by Neuman et al. [6]. To our knowledge there are not previous TEN/SJS linked to Beta1a-Interferon use. Casoni et al. [7] presented a case of severe vasculopathic skin lesions after two months of therapy with Beta 1a-Interferon, but those lesions appeared exclusively in injection sites, not spreaded as our case in which the cutaneous lesions appeared at a distance from the injection sites in such aggressive manner. Inafuku et al. [8] reported a case of cutaneous ulcerations following subcutaneous Beta-1b Interferon injections after 6 months of treatment. Authors conclude that local cytokine-mediated, adverse, immune reaction or non-specific cutaneous inflammatory reaction to interferon, Beta-1b initiated the skin ulceration long after institution of therapy at the injection sites, may constitute possible mechanisms, and the reaction might be related to the depth of injection. Our case differs from the former in the extension of the cutaneous lesions and also because the cutaneous disruption is not limited to injection sites.

GA has not been reported as TEN/SJS cause, therefore Neurology-Department considered it as a secure alternative to Beta-1a-Interferon so it was *in-vitro* assessed likewise.

LTT has recently evinced promising results in delayed-hypersensitivity reactions to drugs as reported by Kano et al., carried out in DRESS and TEN/SJS events [9].

Patient follow up was fulfilled within 1 month after discharge. Control analysis performed at that time, showed normal values on biochemistry and blood count, but the patient displayed disturbance of pigmentation of the cutaneous lesions. Her assessment included a 3 and 6 months after discharge follow-up in which recurrence of the cutaneous lesions was not observed.

Conclusion

We present a rare case of TEN due to several drugs in which *in-vitro* tests have been unhelpful, in our case, to manage this severe and life-threatening condition. Due to lack of evidence using these novel techniques to assess severe drug reactions, further studies would

be helpful to clarify its suitability, mainly in immune modulating medication.

References

1. Garcia-Ortega P, Marin An (2010) Usefulness of the basophil activation test (BAT) in the diagnosis of life-threatening drug anaphylaxis. *Allergy* 65: 1204.
2. Borchers AT, Lee JL, Naguwa SM, Cheema GS, Gershwin ME (2008) Stevens-Johnson syndrome and toxic epidermal necrolysis. *Autoimmun Rev* 7: 598-605.
3. Pichler WJ, Tilch J (2004) The lymphocyte transformation test in the diagnosis of drug hypersensitivity. *Allergy* 59: 809-820.
4. Kim DW, Jung DE, Koo JW (2006) Steroid and enalapril therapy- possible cause of toxic epidermal necrolysis. *Korean J Pediatr* 49: 332-336.
5. De Weck AL, Sanz ML, Gamboa PM, Aberer W, Blanca M, et al. (2009) Nonsteroidal anti-inflammatory drug hypersensitivity syndrome. A multicenter study. I. Clinical findings and in vitro diagnosis. *J Investig Allergol Clin Immunol* 19: 355-369.
6. Neuman M, Nicar M (2007) Apoptosis in ibuprofen-induced Stevens-Johnson syndrome. *Transl Res* 149: 254-259.
7. Casoni F, Merelli E, Bedin R, Martella A, Cesinaro A, et al. (2003) Necrotizing skin lesions and NABs development in a multiple sclerosis patient treated with IFNbeta 1b. *Mult Scler* 9: 420-423.
8. Inafuku H, Kasem Khan MA, Nagata T, Nonaka S (2004) Cutaneous ulcerations following subcutaneous interferon beta injection to a patient with multiple sclerosis. *J Dermatol* 31: 671-677.
9. Kano Y, Hirahara K, Mitsuyama Y, Takahashi R, Shiohara T (2007) Utility of the lymphocyte transformation test in the diagnosis of drug sensitivity: dependence on its timing and the type of drug eruption. *Allergy* 62: 1439-1444.

This article was originally published in a special issue, [Skin & Immune System](#) handled by Editor(s). Dr. Adriana T Larregina, University of Pittsburgh, USA