

More Reasons to Reduce Indications of Gastric Lavage in Self Poisoning

Bennis Nechba Rita*

Critical Care Unit, Idrissi Hospital, Kenitra, Morocco

Letter to Editor

Recently, gastric lavage (GL) is known to be unnecessary in some circumstances where it used to be performed as a routine [1,2]. The flood of airways is a severe complication of GL [3]. It must be prevented by previous tracheal intubation of patients presenting disturbances of consciousness. However, this intubation doesn't assure absolute security. In fact an acute lung injury (ALI) may happen during GL linked to malposition of gastric sound into bronchial tube. In this way we report a case of a severe iatrogenic ALI due to the GL.

Our patient was a 36 years old man, with psychiatric past history, who was admitted to emergency department for voluntary poisoning by a Benzodiazepine and Alpha chloralose with undetermined quantity. On arrival, his cardiovascular and pulmonary examination was normal. But the patient presented convulsions with disturbances of consciousness that's why he was immediately intubated and ventilated. Nesdonale was administered. Then a GL was practiced. The cerebral scanner was normal and the glycemia was 1.80 g/l. Next, the patient was addressed to intensive care unit. Lung examination found this time, crepitant rales diffuse and bilateral. Tracheal and gastric aspirations brought back pinkish secretions. Findings on chest radiograph were compatible with pulmonary edema and a right basal pneumopathy. In addition, it shown gastric sound introduced accidentally into bronchial tube (Figure 1). Immediately, gastric sound was removed and replaced into esophagus. This time, it brought back normal gastric secretions. Complete blood count, biochemical parameters and the rate of prothrombin were normal. The electrocardiogram showed a right bundle branch block. The patient Required Positive pressure ventilation, low tidal volume and inspiratory fraction of oxygen (FiO₂) at 60%. Arterial blood gases done with 60% of FiO₂ showed severe hypoxemia with partial pressure of arterial oxygen (Pao₂) at 60.6 mmHg. The ratio PaO₂/FiO₂ was equal to 100.24 hours after his hospitalization in intensive care the patient presented a septic shock. Protected distal aspiration brought

back purulent sputum, the direct microscopic exam detected Bacillus Gram negative and the culture revealed a *Pseudomonas aeruginosa*. The installation of a severe ALI and a septic shock required vasoactive drugs, wide spectrum antibiotics: ceftazidime and amikacin. Further it prolonged the duration of mechanic ventilation and hospitalization in intensive care. The outcome was favorable, with improvement of clinical signs, arterial blood gases and thoracic X-ray. The patient was weaned off ventilator after 6 days. He stayed in intensive care for 12 days then he was transferred to psychiatry.

The floods of airways owned to GL have worsened the outcome of poisoning by benzodiazepines and alpha chloralose. The use of GL for patients with oral poisons presenting altered mental status was a standard approach until the 1990s [4]. Now, the guidelines suggest that GL should only be considered in a potentially life-threatening ingestion and then only if it can be undertaken within 60 min of ingestion [5,6].

The procedure was performed correctly and all risks were carefully managed and mitigate. In fact, our patient presented a neurological disturbance that's why he was immediately intubated and ventilated before that GL was performed. The position of gastric sound was verified first by listening for air over the epigastrium. Unfortunately, this clinical examination didn't check early the bad position of gastric sound introduced accidentally into bronchial tube, but lately x ray confirmed this complication. This observation shows that GL resulted in adverse outcome.

It is time for a reassessment of the role of GL in the developing world. The 10-20% case fatality found with self-poisoning in the developing world differs markedly from the 0.5% found in the West [1]. This may explain in part why the recent movement away from the use of GL in the West has not been followed in the developing world [1]. Restricting its use to situations where there is a reasonable likelihood that the benefits will outweigh the risks is a necessary first step. This will present a challenge as it will require a significant change in beliefs. Many doctors still support the routine practice of GL. If this can be achieved, then the assessment of these risks and benefits in a randomized controlled trial could be done to see if selective and careful GL is warranted in any patients.

References

1. Eddleston M, Haggalla S, Reginald K, Sudarshan K, Senthilkumaran M, et al. (2007) The hazards of gastric lavage for intentional self-poisoning in a resource poor location. *Clin Toxicol (Phila)* 45: 136-143.
2. Eddleston M, Juszczak E, Buckley N (2003) Does gastric lavage really push poisons beyond the pylorus? A systematic review of the evidence. *Ann Emerg Med* 42: 359-364.
3. Underhill TJ, Greene MK, Dove AF (1990) A comparison of the efficacy of gastric

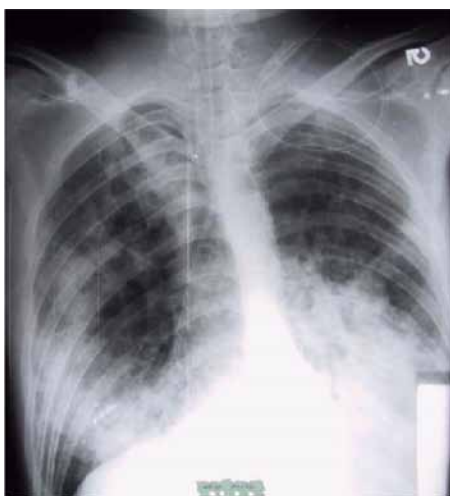


Figure 1: Radiography of thorax finding pulmonary oedema and a right basal pneumopathy. In addition, it shown gastric sound introduced accidentally into bronchial tube.

*Corresponding author: Bennis Nechba Rita, Critical Care Unit, Idrissi Hospital, Kenitra, Morocco, E-mail: bennirhita@yahoo.fr

Received May 21, 2012; Accepted August 20, 2012 Published August 23, 2012

Citation: Rita BN (2012) More Reasons to Reduce Indications of Gastric Lavage in Self Poisoning. *Emergency Med* 2:126. doi:10.4172/2165-7548.1000126

Copyright: © 2012 Rita BN. This is an open-access article distributed under the terms of the Creative Commons Attribution License, which permits unrestricted use, distribution, and reproduction in any medium, provided the original author and source are credited.

-
- lavage, ipecacuanha and activated charcoal in the emergency management of paracetamol overdose. *Arch Emerg Med* 7: 148-154.
4. Albertson TE, Owen KP, Sutter ME, Chan AL (2011) Gastrointestinal decontamination in the acutely poisoned patient. *Int J Emerg Med* 4: 65.
 5. Boyle JS, Bechtel LK, Holstege CP (2009) Management of the critically poisoned patient. *Scand J Trauma Resusc Emerg Med* 17: 29.
 6. Grierson R, Green R, Sitar DS, Tenenbein M (2000) Gastric lavage for liquid poisons. *Ann Emerg Med* 35: 435-439.