

Minimally Invasive Surgery of Lachrymal Outflow: Comparison of Techniques with Presentation of a Novel Surgical Dacryocystectomy Variant

Raffaele Nuzzi* and Federico Tridico

Institute of Ophthalmology, Department of Surgical Sciences, University of Turin, Turin, Italy

*Corresponding author: Raffaele Nuzzi, Institute of Ophthalmology, Department of Surgical Sciences, University of Turin, Turin, Italy, Tel: + 39368203493; E-mail: prof.nuzzi_raffaele@hotmail.it

Received date: October 15, 2016; Accepted date: November 20, 2017; Published date: November 24, 2017

Copyright: ©2017 Nuzzi R, et al. This is an open-access article distributed under the terms of the Creative Commons Attribution License, which permits unrestricted use, distribution, and reproduction in any medium, provided the original author and source are credited.

Abstract

Objective: The surgical treatment of epiphora and dacryocystitis includes Dacryocystorhinostomy (DCR) and Dacryocystectomy (DCT). To date, dacryocystectomy has been considered a secondary procedure and is not properly considered among the currently available surgical options. Intubation of the lacrimal system often improves surgical outcomes. In this study, a new variant of surgical technique, dacryocystectomy with lacrimal canalicula silicone intubation, is presented. All novel aspects and possible indications are discussed.

Methods: Patients with chronic dacryocystitis associated with epiphora and lacrimal stenosis were enrolled for dacryocystectomy with silicon intubation. During follow-up, prevalence of epiphora, disease recurrences and adverse events have been investigated. Also, a retrospective clinical charts comparison with patients that received dacryocystorhinostomy *ab externo* has been performed.

Results: No significant differences were found in terms of postoperative epiphora, silicon tube dislocation and overall adverse events have been observed between the compared groups ($p > 0.1$). Persistent bleeding events were significantly more frequent in the DCR group ($p < 0.05$). No severe adverse events were observed in both groups.

Conclusions: Lacrimal intubation may improve classical dacryocystectomy outcomes with greater reduction of the epiphora. This technique, when well indicated (especially following a proper intraoperative clinical evaluation), may provide a decisive resolution of infective/inflammatory lacrimal affections and can avoid intra and postoperative complications associated with DCR.

Keywords: Dacryocystectomy; Lacrimal intubation; Dacryocystorhinostomy; Surgical technique; Epiphora; Dacryocystitis; Crawford tubes

Abbreviations: DCR: Dacryocystorhinostomy; DCT: Dacryocystectomy

Introduction

The surgical treatment of epiphora and dacryocystitis includes dacryocystorhinostomy (DCR), performed with transcutaneous (external DCR) or endonasal technique, and removal of the lacrimal sac (dacryocystectomy, DCT).

Dacryocystectomy has been considered a secondary procedure, thus it is rarely mentioned in recent literature and not properly considered among the currently available surgical options. The main indication of DCT is limited to cases of lacrimal sac tumors [1]. Other indications reported in the Literature include recurrent dacryocystitis, especially in cases of fragile patients, nasal or facial malformations increasing the risk of post-DCR cutaneous fistula, Wegener granulomatosis or other vasculitis, risk of excessive bleeding, patients not suitable for long surgical procedures or with a low pain threshold [2]. Since the indication to DCT is considered rare, many surgeons are not experienced with this technique.

Given that, dacryocystectomy deserves to be reconsidered, especially in case of fragile patients or pre/intraoperative findings suggestive for lacrimal sac abnormalities or infections (which can be properly assessable only in course of intervention with surgical microscopy). Moreover, there are reports of cases of frail and elderly patients where a dacryocystectomy was preferred to DCR [3-5].

Usually, after a dacryocystorhinostomy, lacrimal intubation is required in order to improve postoperative outcomes [5-7]. However, Crawford's tube removal can often lead to DCR failure with epiphora recurrence and local inflammation that can propagate from the nasal region with ascending behavior. In addition, in patients with lacrimal outflow stenosis, DCR alone doesn't always restore a sustained reopening. The decision to apply stent intubation should be performed on the basis of pre/intraoperative findings [6].

In this study, a new variant of surgical intervention, dacryocystectomy with lacrimal canalicula intubation, is presented. All novel aspects and possible indications are discussed (also in comparison with dacryocystorhinostomy). This technique has been performed under surgical microscopy, in order to better observe the presence of anatomical conditions of chronic flogosis or signs of infection.

Methods

This novel surgical variant has been dedicated to patients presenting at our center with recurrent/chronic dacryocystitis associated with epiphora or lacrimal stenosis and indication to surgical resolution. Exclusion criteria were ongoing/unresolved severe corneal surface disease/infection, previous lacrimal surgery, maxillofacial malformations, acute ongoing lacrimal infection, pregnancy. All procedures were performed in conformity with the ethical principles set out in the Helsinki Declaration and its revisions. Consent to surgery was obtained in written form and has been registered for all subjects of this study. All subjects under study agreed to receive Dacryocystectomy with intubation instead of DCR, when proposed, since they intended to resolve recurrent dacryocystitis or they were against a more invasive procedure with higher anesthesiologic risk.

Dacryocystectomy with lacrimal intubation has then been performed by the same surgeon with the aid of a surgical microscope with a focal length of 300 mm, as reported below:

Skin disinfection with iodopovidone;

- "Medicated" lacrimal irrigation through superior and inferior puncta, with a tobramycin/dexamethasone association, preceded by assessment of mucopurulent secretions presence;
- Anesthesia with subcutaneous and peribulbar infiltration of mepivacaine 2%+epinephrine 1:100.000 (Carbocaine);
- Cutaneous incision of 10-12 mm at 3-4 mm from the inner canthus along the anterior lacrimal crest;
- Intraoperative assessment of anatomic relationships and conditions of the lacrimal sac
- Assessment of bone conditions, focusing on alignment/distance with the lacrimal sac;
- Canalicular incision at the level of their entrance in the lacrimal sac or at the level of the distal portion of the common canaliculus.
- Removal of the lacrimal sac (after a H-shaped incision, preferred when possible in relation to lacrimal sac conditions found through surgical exploration);
- Irrigation of the lacrimal pathways with Cefuroxime (50 mg/0.5 ml) and betamethasone (4 mg/2 ml)
- Intubation of the superior and inferior lacrimal canaliculi with Crawford tube: the two metal bodkins at the ends of the Crawford tube were introduced in both lacrimal puncta and pulled at the level of the respective canalicular distal ends. Then, both metal bodkins were removed and the remaining distal ends were shortened in order to obtain an intraorbital intubation of 10 mm of length.
- Knotting of the two Crawford tubes distal heads with suture/anchorage on anterior endorbital portion, with prolene 6-0 thread;
- Placement of the free endorbital portion of the Crawford tubes after realization of a proper deep posterior endorbital space. The endorbital lodge has been created within the lacrimal fossa (medially to the posterior lacrimal crest) through posterior mucosa disconnection, diathermy and cauterization directed towards the ethmoidal region.
- Repeated irrigation with cefuroxime (50 mg/0.5 ml) and betamethasone (4 mg/2 ml)
- Intra-dermal suture of the nasal cutaneous surgical wound with nylon 6-0 or prolene 6-0 thread;

- Crawford tube excision with scissors at the level of lacrimal puncta (to prevent extrusion) followed by suture of the proximal portion on lacrimal puncta with Sharpoint™ nylon microsuture (nylon 10-0)

Following surgery, each patient received netilmicin+dexamethasone eyedrops 4 times daily in the treated eye (to be applied at the inner canthus), and heparin sodium 500,000 UI/100 ml eyedrops (in order to prevent intraluminal coagulation of the tubes), twice a day, for a total of 15 days. Each patient also applied an Ofloxacin 0.3% ointment, 3 times a day on the skin wound for 15 days.

The suture applied to the skin wound was removed at 10 days after surgery. Sharpoint™ Nylon suture (nylon 10-0) was removed 10-15 days after surgery depending on different cases. No postoperative lacrimal ducts irrigation has been performed.

Primary outcomes were prevalence of postoperative epiphora or lacrimal infection (dacryocystitis) and prevalence of local/systemic adverse events. Preliminary results have been confronted with a retrospective clinical charts review of patients that received dacryocystorhinostomy *ab externo* at our center in the previous year, which have been selected applying the same indications and exclusion criteria of patients enrolled in this study, in order to obtain a homogeneous confront group (in relation to age, sex and pathologies). Clinical charts with missing information about one or more postoperative outcomes have not been included. Comparison between the two groups have been performed with Fisher Exact Test.

Results

39 patients were recruited in this study to undergo dacryocystectomy with lacrimal intubation technique. Population characteristics are reported in Table 1. 32 clinical charts of patients that received dacryocystorhinostomy in the previous year have been included. Characteristics of the retrospective clinical chart review are reported in Table 2. No statistically significant differences between the characteristics of the groups under study were found. Postoperative clinical presentation is shown in Figure 1.

Participants characteristics		
Patients	Men	10 (26.09%)
	Female	29 (73.91%)
	Total	39
Age	Average	63,52
	Range	42-85
Principal disease	Patients >80 years old	12 (30.43%)
	Patients >75 years old	9 (21.74%)
	Recurrent dacryocystitis	39 (100%)
Associated Diseases	Lachrymal stenosis	22 (56.41%)
	Epiphora	39 (100%)
	Blood hypertension	24 (60.87%)

	Hyschemic cardiopathy	9 (21.74%)
	Pacemaker holder	3 (8.70%)
	In therapy with oral antiaggregant	10 (26.09%)
	In therapy with oral anticoagulants	5 (13.04%)
	Hypothyroidism	2 (4.35%)
	Benign Prostatic hypertrophia	5 (13.04%)
	Diabetes	15 (39.13%)

Table 1: Population characteristics of the dacryocystectomy with intubation group.

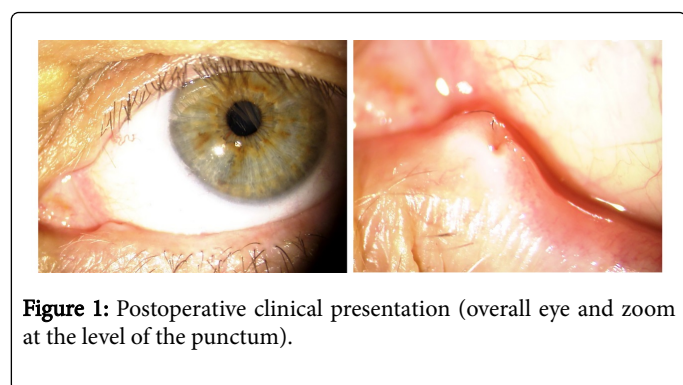


Figure 1: Postoperative clinical presentation (overall eye and zoom at the level of the punctum).

Dacryocystectomy group

14 patients (36.84%) reported the persistence of the epiphora, which lasted for not more than 30 days after surgery and coincided mostly with eyedrops administration. Of these patients, 10 (26.31%) complained occasional lacrimation even at the six months follow-up, albeit markedly reduced if compared to the immediate post-operative. In the event of dacryocystitis or subacute flogosis before surgery, no recurrence was observed throughout postoperative follow-up and patients reported complete symptoms resolution.

Recorded adverse events have been reported:

- Epithelial corneal erosion for protrusion from the canalicula of a single Crawford tube (8 cases, 21.05%), that has been subsequently shortened to the slit lamp;
- A complete, post-traumatic, Crawford tube extrusion case (2.56% of operated patients), then repositioned;
- A mildly local bleeding case persisting for 15 days.

Dacryocystorhinostomy group: clinical chart analysis

In this group, 9 patients (28.13%) reported epiphora persisting for more than 30 days after surgery. At the 6-months follow-up 4 patients (12.5%) keep complaining about occasional lacrimation, even if reduced.

Recorded adverse events in this group were:

- 4 cases of tube protrusions (12.5%)
- 2 Crawford tube extrusions (6.25%)
- 7 cases of persistent bleeding (21.86%)

- 2 cases of dry eye (6.25%)
- 1 case of pyogenic granuloma (3.13%)

Comparison with retrospective clinical chart analysis

Regarding persistent epiphora after 30 days, no statistically significant differences were found ($p > 0.1$). Even in the long term no differences in epiphora episodes were found ($p > 0.1$).

Regarding overall non-severe adverse events we have found differences statistically significant ($p < 0.01$). No differences were found in case of tube protrusion ($p = 0.53$) or extrusion events ($p = 0.59$). Persistent bleeding events were significantly fewer in the DCT group ($p < 0.05$). No severe adverse events were observed in both groups.

External-DCR Patients Characteristics		
Patients	Men	13 (40.63%)
	Female	19 (59.38%)
	Total	32
Age	Average	60.58
	Range	37-81
	Patients >80 years old Patients >75 years old	9 (28.13%) 23 (71.88%)
Principal disease	Recurrent dacryocystitis	30 (93.75%)
	Lachrymal stenosis	32 (100%)
	Epiphora	32 (100%)
Associated Diseases	Blood hypertension	27 (84.36%)
	Hyschemic cardiopathy	7 (21.88%)
	In therapy with oral antiaggregant	9 (26.09%)
	In therapy with oral anticoagulants	4 (12.5%)
	Hypothyroidism	1 (3.13%)
	Benign Prostatic hypertrophia	1 (3.13%)
	Diabetes	17 (53.16%)
Glaucoma	4 (12.5%)	

Table 2: Patients characteristics of the externa dacryocystorhinostomy group (extracted from retrospective clinical charts analysis).

Discussion

If compared to DCR, dacryocystectomy has advantages in terms of technical easiness, lower learning curve, rapid execution in local anesthesia, less invasiveness (since bone or nasal mucosa rupture is not needed), minimal bleeding, lower hospitalization, early recovery, and overall minor morbidity. Before the execution of dacryocystectomy

with silicone intubation, patients were informed that the purpose of this procedure was to eliminate recurring inflammation with excessive lacrimation. Infectious sites can be completely removed with the asportation of the lacrimal sac. A reduction of epiphora have been observed and no significant differences were found between the DCT group and the DCR interventions analyzed. Improvement of epiphora after this DCT technique may accrue probably from the realization of an alternative lacrimal outflow at the level of the posteromedial orbital region (with diffusion mechanism into the orbital venous drainage), which is facilitated by the application of silicone intubation with intraorbital suture (using in our cases the 10-0 nylon Sharpoint). Consequently, a reduction of the nasal lacrimal drainage can occur (due to complete lacrimal sac removal) with a following increase of lacrimal meniscus (even if not clinically significant). Besides, if lacrimal sac infection or flogosis is found during the pre/intraoperative evaluation, the resolution of these conditions should be prioritized with respect to the resolution of epiphora. In these cases, techniques performing a complete sac removal should be privileged even when patients complain mainly about epiphora. In addition, several subjects reporting residual epiphora after surgery referred a complete resolution after eyedrops suspension at the end of postoperative treatment (the optimal post-surgical efficacy occurred after eyedrops suspension).

Even if the DCR in local anesthesia minimizes intraoperative bleeding, pain during surgery may lead to inappropriate intervention, aside from the increased risk of arterial pressure spikes. In addition, meticulous hemostasis is crucial for a successful DCR [8]. During DCR in local anesthesia, it is necessary to pack the nose with cocaine (or other local anesthetic) and nasal decongestant as well with risk of exacerbation of systemic hypertension, tachycardia, dysrhythmia and myocardial toxicity due to their sympathomimetic action [9,10].

Reasons of endoscopic DCR failures include incorrect diagnosis, surgeon inability, inadequate opening of the nasolacrimal bone canal, inadequate removal of the middle half of the sac, prolonged stenting and fibrotic or atonic sac [11,12]. Fibrosis and bone neogenesis are other factors that contribute to poor prognosis [13].

Moreover, a higher rate of severe adverse events in older people, if compared with a younger population, has been reported. Severe cases include stroke, myocardial infarction, syncope, hemorrhage requiring arterial embolization and copious epistaxis [14].

Complications following a dacryocystectomy are rare. Accidental angular vein injury may lead to important bleeding, similar to dacryocystorhinostomy procedures. This can be easily avoided if the incisions are not performed in correspondence of the angular vein. Other complications include dehiscence of surgical wound, wound infection, increased lacrimal meniscus and epiphora, recurrent dacryocystitis (in case of not complete removal of lacrimal sac) and a facial scarring/cheloid [2]. Although very rare, cases of visual loss and orbital cellulitis following a DCT have been reported in the literature [2,15].

In this study, no significant differences in terms of overall complications were observed between the two compared groups. However, cases of persistent postoperative bleeding were significantly more frequent in patients that underwent dacryocystorhinostomy. Pyogenic granuloma cases did not occur in the DCT+intubation group. Even with the presence of a permanent communication between ocular surface and deep orbital region, events of orbital cellulitis have not been observed in the DCT group. Prophylaxis of

postoperative infections was performed through repeated antibiotic and antinflammatory irrigation and accurate cauterization in orbita post. Moreover, with DCT it is possible to remove completely infectious lacrimal sacs and nasal anastomosis is not needed, hence eliminating two possible sites of infections (sac and nasal mucosa) that are still possible after DCR. In fact, the osteotomy itself increase the risk of inflammation/infections ascending from the nasal cavity, even subacute, with an increased frequency of scarring stenosis or angular conjunctivitis [16,17]. Ascending infections and flogosis can be also promoted by Lester-Jones tubes, especially if used in case of negative outcomes of previous DCR. Furthermore, it is not reasonable to expect an increase of postoperative orbital infections (which is a rare complication in this type of surgery), since this technique is similar to a classical dacryocystectomy.

The osteotomy in DCR surgery, may also promote nasal absorption of antiglaucomatous drugs, increasing the risk of systemic side effects. Toxicity of topic beta-blockers may be significantly aggravated after an effective DCR due to an increase in lacrimal outflow through the anastomotic site with increased drug absorption at the level of the nasal mucosa [18]. We therefore believe that DCT may be preferred to DCR in the management of dacryocystitis episodes in elderly patients receiving topical beta blockers, when epiphora is not a serious symptom. The execution of a DCT instead of DCR also prevents the "sump syndrome" that can occur after DCR due to an incomplete anastomosis or to lacrimal sac regeneration.

Given these considerations, the choice between DCR or DCT may be influenced also by the different conditions assessed intraoperatively: repeated infectious events of the lacrimal sac (which may appear inconsistent) or mucopurulent discharge at the time of intraoperative irrigation, can lead the surgeon choice towards a dacryocystectomy with intubation procedure.

The "lacrimal plug" effect (following the reduction of the nasal lacrimal drainage) is particularly desirable in patients with different degrees of dry eye because it increases lacrimal meniscus improving keratoconjunctivitis sicca or tear hyposalivation [2]. In fact, Boynton and Anawis commented that elderly patients with dry eye, DCR can lead to discomfort, even when technically correct, because these subjects have insufficient production of tears to maintain the lacrimal flow and the nasal drainage is more represented [19]. Even in this study, dry-eye onset after dacryocystorhinostomy has been observed.

Crawford tube prolapse is one of the most common complications when silicone intubation is applied, especially after DCR. [20]. The lateral prolapse of the tube is problematic given the potential corneal and conjunctival irritation, punctal erosion and patient discomfort [21]. Crawford tubes' intraorbital anchorage is a safe procedure as it would limit the anterior dislocation and the risk of ocular extrinsic muscles involvement is low. The suture on the lacrimal puncta 10-0 nylon (with Sharpoint™ needle) has the advantage of maintaining endocanalicular positioning (supporting the endorbital suture). However, Crawford's tube prolapse is still possible. The passage of the nylon thread inside the tube lumen avoids its occlusion by debris or mucous swelling. We did not observed cases of stenosis/scarring of the lacrimal puncta following suture.

In this particular DCT technique, postoperative lacrimal irrigations or probing have never been performed, in contrast with regular DCR procedures. On the contrary these maneuvers should be contraindicated after this type of surgery and may lead to failure or

possible complications. No inflammatory granulomas have been observed in the postoperative follow-up.

Conclusions

Silicon lacrimal intubation may improve classical dacryocystectomy outcomes with greater reduction of the epiphora. This modified technique can expand the indications of DCT which can therefore be dedicated to cases of recurrent dacryocystitis (associated with dry-eye syndrome), frail subjects with high hemorrhage risk or affected by generalized vasculopathy or uncontrolled hypertension, subjects with conditions leading to ocular/nasal scarring or ascending infectious processes, subjects treated with antiglaucomatous drugs (in order to prevent systemic toxicity), patients presenting maxillofacial pyomucocele or malformations (even in case of previous surgery) and intraoperative assessments which lead to conversion from DCR to DCT (these should be obtained only under examination through operative microscopy) [22-26]. Since this modified DCT is also effective in treating "sticky eye" symptoms, it may be preferable to DCR especially for older patients complaining mainly mucopurulent discharges and episodes of dacryocystitis rather than "watery-eye".

DCT with intubation, when well indicated, may provide a decisive resolution of infective/inflammatory affections (acute/subacute/recurrent) of the lacrimal sac and can avoid intra-and postoperative complications associated with DCR. While DCR remains the operation of choice for the vast majority of lacrimal disorders, when the only symptom is epiphora, the DCT with intubation should still be carefully considered, especially if based on clinical findings in the intraoperative setting. In addition, as the surgical time is significantly shorter, the intraoperative hemorrhage can be minimized, and the type of local anesthesia needed is safer than in the DCR, DCT may be considered in case of frail patients.

In conclusion, DCT with intubation of lacrimal canaliculi can represent a safe alternative to DCR, particularly in frail, elderly patients with recurrent or chronic dacryocystitis or alterations of the lacrimal sac and/or the anatomical configuration of the medial orbit. This technique should be considered also in case of intraoperative assessment of alterations that can lead to dacryocystorhinostomy failure. Moreover, we have recently designed a minimally invasive intraorbital lacrimal prosthesis (currently patent pending) which can be associated with the procedure described in this study.

Conflicts of Interests

The authors declare that they have no competing interests.

Funding Sources

All materials needed in this study have been procured/funded by the Eye Clinic Section, Department of Surgical Sciences, University of Turin.

References

1. Flanagan JC, Mauriello JA, Stefanyszyn MA (1990) Lacrimal tumors and inflammations. In: Mauriello JA, Flanagan JC, eds. *Management of orbital and ocular adnexal tumors and inflammations*. New York: Springer-Verlag, 187-196.
2. Ali MJ (2014) Dacryocystectomy: Goals, Indications, Techniques and Complications. *Ophthal Plast Reconstr Surg* 30: 512-516.
3. Cook HL, Olver JM (2004) Dacryocystectomy as treatment of chronic dacryocystitis in a frail, elderly patient. *Eye (Lond)* 18: 334-336.
4. Matayoshi S, Van Baak A, Cozac A, Sardinha M, Fernandes JB, et al. (2004) Dacryocystectomy: indications and results. *Orbit* 23: 169-173.
5. Kim NJ, Kim JH, Hwang SW, Choung HK, Lee YJ, et al. (2007) Lacrimal silicone intubation for anatomically successful but functionally failed external dacryocystorhinostomy. *Korean J Ophthalmol* 21:70-73.
6. Longari F, Dehgani Mobaraki P, Ricci AL, Lapenna R, Cagini C, et al. (2016) Endoscopic dacryocystorhinostomy with and without silicone intubation: 4 years retrospective study. *Eur Arch Otorhinolaryngol* 273: 2079-2084.
7. Saiju R, Morse LJ, Weinberg D, Shrestha MK, Ruit S (2009) Prospective randomised comparison of external dacryocystorhinostomy with and without silicone intubation. *Br J Ophthalmol* 93 :1220-1222.
8. Bartley GH, Nichols WL (1991) Hemorrhage associated with dacryocystorhinostomy and the adjunctive use of Desmopressin in selected patients. *Ophthalmology* 98: 1864.
9. Meyers EF (1980) Cocaine toxicity during dacryocystorhinostomy. *Arch Ophthalmol* 98: 842-843.
10. Meyer DR (2000) Comparison of oxymetazoline and lidocaine versus cocaine for outpatient dacryocystorhinostomy. *Ophthalmic Plastic Reconstr Surg* 16: 201-205.
11. Nomura K, Arakawa K, Sugawara M, Hidaka H, Suzuki J, et al. (2017) Factors influencing endoscopic dacryocystorhinostomy outcome. *Eur Arch Otorhinolaryngol* 274: 2773-2777.
12. Tarbet KJ, Custer PL (1995) External dacryocystorhinostomy. Surgical success, patient satisfaction, and economic cost. *Ophthalmology* 102: 1065-1070.
13. Walland MJ, Rose GE (1994) Factors affecting the success rate of open lacrimal surgery. *Br J Ophthalmol* 78: 888-8891.
14. Tooley AA, Klingler KN, Bartley GB, Garrity JA, Woog JJ, et al. (2017) Dacryocystorhinostomy for Acquired Nasolacrimal Duct Stenosis in the Elderly (≥ 80 Years of Age). *Ophthalmology* 124: 263-267.
15. Pai VH, Rao DK, Bhandary SV (2006) Visual loss following dacryocystectomy. *Ophthalmic Surg Lasers Imaging* 37: 494-496.
16. Coumou AD, Genders SW, Smid TM, Saeed P (2017) Endoscopic dacryocystorhinostomy: long-term experience and outcomes. *Acta Ophthalmol* 95: 74-78.
17. Eshraghi B, Alemzadeh SA, Abedinifar Z (2016) Conjunctival bacterial flora in fellow eyes of patients with unilateral nasolacrimal duct obstruction and its changes after successful dacryocystorhinostomy surgery. *J Curr Ophthalmol* 29: 59-62.
18. Detorakis ET, Tsilimbaris MK (2009) Dacryocystectomy for the treatment of nasolacrimal obstruction in elderly patients treated with beta-blockers. *Ophthal Plast Reconstr Surg* 25: 417.
19. Boynton JR, Anawis MA (1996) Role of dacryocystectomy in the management of failed dacryocystorhinostomy associated with chronic dacryocystitis. *Ophthalmic Surg* 27: 133-136.
20. Segal KL, Van Tassel SH, Kim C, Hsu N, Kacker A, et al. (2015) Comparison of the extrusion rate of Crawford tubes. *Int J Ophthalmol* 8: 791-793.
21. Brookes JL, Olver JM (1999) Endoscopic endonasal management of prolapsed silicone tubes after dacryocystorhinostomy. *Ophthalmology* 106: 2101-2105.
22. Baek JS, Jeong SH, Lee JH, Choi HS, Kim SJ, et al. (2017) Cause and Management of Patients with Failed Endonasal Dacryocystorhinostomy. *Clin Exp Otorhinolaryngol* 10: 85-90.
23. Onerci M, Orhan M, Ogretmenoğlu O, Irkeç M (2000) Longterm results and reasons for failure of intranasal endoscopic dacryocystorhinostomy. *Acta Otolaryngol* 120: 319-322.
24. Yung MW, Hardman-Lea S (2002) Analysis of the results of surgical endoscopic dacryocystorhinostomy: effect of the level of obstruction. *Br J Ophthalmol* 86: 792-794.
25. Choi JC, Jin HR, Moon YE, Kim MS, Oh JK, et al. (2009) The Surgical Outcome of endoscopic dacryocystorhinostomy according to the

obstruction levels of lacrimal drainage system. *Clin Exp Otorhinolaryngol* 2: 141.

26. Fayers T, Laverde T, Tay E, Olver JM (2009) Lacrimal surgery success after external dacryocystorhinostomy: functional and anatomical results using strict outcome criteria. *Ophthal Plast Reconstr Surg* 25: 472-475.