

Minimal Access Laser Therapy (Malt) of Genitary Hemangiomas in Girls

Andreas Fette*

Department of Pediatric Surgery, University of Pécs, Medical School, Hungary, Libyan German Hospital Benghazi, Lybia

Abstract

Objective: Hemangiomas in the sensitive genital area of the female body are a constant major cosmetic concern. In the majority of cases they are even complicated by ulceration and/or hemorrhage as well. In addition, their delicate location make genitary hemangiomas like their facial counterparts prone to psychosocial disorders, too. Therefore, to find the best and most effective treatment for the individual case is still an ongoing debate.

Patients and methods: We treated 5 girls (Median age: 6 mos, range: 2.5-118 mos) with ulcerating and/or bleeding complex genitary hemangiomas ("capillary", "cavernous", "mixed") with minimal access laser therapy (MALT). The 1064 nm Nd:YAG laser was applied in compression or intralesional bare fibre technique with cooling of the skin under general anesthesia. Median energy applied ranged from 500 to 13 075 J/cm²/session in the individual patient.

Results: Bleeding and ulceration could be stopped usually within the first laser session, while involution started during the following sessions.

Conclusion: Our minimal access laser therapy (MALT) with a commercial Nd:YAG laser device seems to be promising alternative in the treatment of this specific condition.

Keywords: Genitary hemangiomas; Girls; Nd:YAG-Laser; Minimal access treatment

Introduction

Hemangiomas are still one of the most common skin lesions in infancy and early childhood. To cope with such a lesion is a persistent problem for all affected children and parents alike. But not exclusively, it is an ongoing challenge for us carers and the health care system as well. And, it is not only the delicate location of these hemangiomas in a most sensitive area like the genitals, unfortunately, its their (potential) complications like ulceration and hemorrhage, that needs to be taken into consideration quite frequently, too.

Thus, the question, -"How to manage and treat such hemangiomas best...?"-, is still a matter of debate in our allday clinical practice.

Especially, since the former practised benign neglect of such lesions is no longer in favour, thanks to the improved understanding of the natural course and general acceptance of a more accurate classification scheme of such hemangiomas. Respectively, recent advantages in wound care and/or laser technology made it much easier to intervene earlier and more effective as well. And this not only for lesions, that would otherwise leave a grossly unacceptable result behind. Quite contrary, such an early approach will even prevent these children to suffer any of the negative clinical and psychological impacts such lesions will have on their future life.

In the following paragraphs we would like to present our results using minimal access laser therapy (MALT) in the care of this small cohort of patients.

Patients and Methods

Five little girls (Median age: 6 mos, range: 2.5-118 mos) with complex genitary hemangiomas have been treated with MALT in a Swiss Children's Hospital over a time period of 3 years. Each hemangioma has been subclassified either into "capillary", "cavernous", or "mixed" in accordance to the hemangioma's overall morphological appearance and the dominating part of the lesion [1-3]. Ulceration and hemorrhage, either preexisting or appearing in due course, diagnosed alone or in combination, have been documented and treated accordingly and immediately after first notification [4-6].

For details regarding type, size, location and complications please

visit (Table 1 and Figure 1).

A continous Nd:YAG (neodymium:yttrium aluminum garnet) laser (CLMD 220-60; 1064 nm; Surgical Laser Technology (SLT), Montgomery PA/USA) beam of 5-10 W has been applied straight to the capillary parts of the hemangioma in glass plate-compression-technique. While the cavernous parts of the hemangioma, indeed, have been treated with a continuous 30-35 W laser beam transmitted via an ice cube (ice cube-cooling-technique). For the deep parts, respectively, the intralesional bare fiber-technique (5-8 W) has been used. Margins or other specific areas of the hemangioma have finally been treated in pulsed spot (0.2-0.5 s), non-contact technique with repeated intermittent cooling of the skin, if deemed necessary (Table 2).

All laser sessions have been performed under general anesthesia on a 4 to 6 weeks basis; in the majority in the day surgery department of the Children's Hospital. Follow-up visits have been scheduled every 4 weeks. On parent's request intermittent hydrocolloid foam dressings have been applied on the ulcerated areas. No antibiotics have been prescribed on a regular basis.

Temporary and final results have been documented with a standard digital camera (Samsung, Digimax S 1000). Treatment has been graded a success when ulceration or hemorrhage stopped, and the hemangioma showed constant involution.

Results

In Median 2 (range 1-4) laser sessions have been administered to each individual patient to stop ulceration and hemorrhage and to

***Corresponding author:** Andreas Fette, Chief Physician, Department of Pediatric Surgery, University of Pécs, Medical School, Hungary, Libyan German Hospital Benghazi, Lybia, Tel: 00491729535127; E-mail: andreas.fette@gmx.de

Received August 13, 2014; **Accepted** December 16, 2014; **Published** December 20, 2014

Citation: Andreas F (2014) Minimal Access Laser Therapy (Malt) of Genitary Hemangiomas in Girls. Med Surg Urol 3: 145. doi:10.4172/2168-9857.1000145

Copyright: © 2014 Andreas F. This is an open-access article distributed under the terms of the Creative Commons Attribution License, which permits unrestricted use, distribution, and reproduction in any medium, provided the original author and source are credited.

Pat	Age [mos]	Location	Type	Size [cm]	Complications
B.C.	118	right nipple	mixed	1	pretreated for abscess
K.I.	72	right nipple	mixed	1	po laser 5 yago,pain
Sch.E.	11	right breast	mixed	4	-
M.T.	6	perineum, labia bilateral	capillary	3+5	ulceration
H.M.	2.5	left labia majora	capillary	2	ulceration,hemorrhage

Table 1: Details of hemangiomas regarding type, size, location and complications.

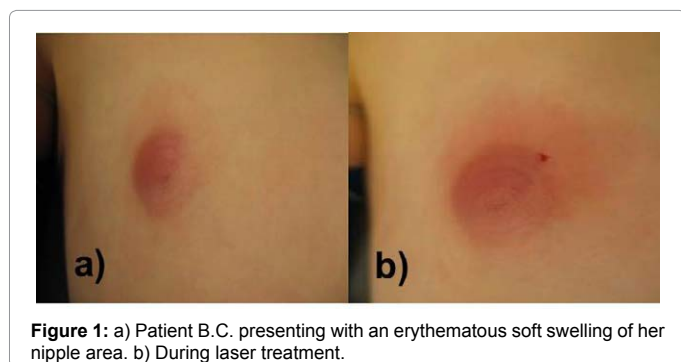


Figure 1: a) Patient B.C. presenting with an erythematous soft swelling of her nipple area. b) During laser treatment.

induce constant involution. The Median laser energy applied per cm² and per session ranged widely from 500-13 075 J in our patient sample.

For more details on the final results please see (Table 3 and Figures 1-5). Finally, no laser specific complications have been seen.

Discussion

Hemangiomas are common tumors in infancy and one of the most common congenital anomaly in the human. During the last decades the general and non-specific term “hemangioma” has been traditionally applied to all sorts of benign vascular tissue tumors, vascular birthmarks, and vascular malformations [1,2,7]. In order to develop a more stringent classification for the “real” hemangioma, several revisions and updates have been undertaken over the years, but none has been finally approved yet and the discussion is still controversial [1,7-10].

However, at the time this study started, the final decision has been to classify the simple genitourinary hemangiomas in either “capillary”, “cavernous” or “mixed” lesions based on the following definitions: A “capillary” hemangioma is represented by a bright red, raised lesion, ranging from millimeters to several centimeters in diameter. It is always well circumscribed, and only partially compressible. A “cavernous” hemangioma instead, is a more nodular one, that could be large in diameter, width and depth as well. It is often bluish or purple and easy compressible. The “mixed” lesions, indeed, have components of both [1,8,9].

Hemangiomas found in developmental segments are referred to as “segmental” lesions. These segmented hemangiomas are commonly associated with other extracutaneous abnormalities. Here the PELVIS/SACRAL syndrome denotes the association of segmented hemangiomas of the loins (sacrolumbar region, buttocks or perineum = napkin hemangioma) with spinal dysraphia affecting the sacrolumbar spine, the terminal medullary cone, the genitourinary organs and the anal region to a varying degree [11-13]. The acronym “LUMBAR”, indeed, is proposed by several authors to describe the association between Lower body hemangioma and other cutaneous defects, Urogenital anomalies, Ulceration, Myelopathy, Bony deformities, Anorectal malformations, or Arterial and Renal anomalies further. Because

of the many similarities between the LUMBAR association and a PHACE syndrome, they might be considered as a regional expression of the same. In general, such segmental lesions have a higher risk of threatening life or function, and when they are located in the perineal area, they are frequently associated with developmental anomalies and even more often complicated by ulceration. The diagnosis of such hemangiomas associated with a PELVIS/SACRAL/LUMBAR syndrome might be delayed or complicated, too, due to the common macular, teleangiectasic or livedoid appearance of these lesions [10-13], which was noticed in one of our patient as well.

The “rule of thumb”, stating that all hemangiomas appear after a few weeks of life, growing fast, before starting a slow involution is old fashioned and too simplistic, because it does not tell parents or physicians anything about the lesion’s further growth or potential to destruct sensitive surrounding tissues. But, as soon as we are able to stop the hemangioma’s growth early, we can definitely guarantee a final scar or spot not bigger than the primary lesion itself. If we let it grow instead, we definitely will end up with either a completely involuted hemangioma with no real difference to its surrounding tissue (most favourable). Or, a big fibrous scar and fatty tissue remnant, that needs surgical correction (and hopefully can be corrected) later in life, respectively, a huge area of destruction and disfigurement, where the chance of reconstruction is nil (because we are too late) [6,7].

Fortunately, this traditional approach of “benign neglect” is nowadays challenged more and more by considering hemangiomas in locations, like the face, the digits and the perineal and genital area, as real “cosmetic emergencies” [6-8,11,14-18]. Here, in parallel to functional and cosmetic irritation, immediate intervention is of key importance, because of the permanent concerns and psychosocial trauma the child and his/her family is subjected to. So far, this has been one of the most neglected facts in the management of this type of hemangiomas [18-25].

Later in adolescence, the most critical transition period from childhood to adult sexual and social behaviour rules, increasing normative attention to anxiety, worries and concerns regarding self-esteem, overall physical appearance, and body image have to be paid for, too. Many of these adolescents suffer depressive and attendant behavioural disorders like fatigue, poor concentration, and hypochondriasis. Or even self-imposed isolation, suicide thoughts and attempts. In fact, their psychosocial well-being is at risk. However, in comparison to other physical impairments or differences, so far no reports of higher rates of clinical depression, psychosocial disturbances or suicides are available [7,22,24].

The denial is still so great, that many medical textbooks still fail to mention it. And, at least in the past, we have to confess, that this “wait & see” approach, or considering any treatment “just as cosmetic”, left us behind too often. Than, obviously there is a hemangioma, and this hemangioma anyhow will certainly subject this child to several years of emotional trauma. That this usually happens during the formative years of the child’s individual personality, will make it even worse and it will certainly interfere with his/her puberty as well. With no doubt, these effects are profound and most likely irreversible [7,22,24].

Ulceration is one of the most common physical complications seen in up to 35% of patients with centro-facial and genitourinary hemangiomas [4,5,26-30]. Such an ulceration can cause pain, or making difficult time for dressing or nappy changes. Ulceration can be further complicated by secondary infection (4.9%) [27] and hemorrhage. This hemorrhage can even lead to severe anaemia with the need for a blood transfusion. Finally, often a disfiguring scar follows this wounding [5]. Since

glass plate compression	By compression of the capillary layer onto the neighbouring layers the laser beam gets more focused.
ice cube cooling	When the skin and superficial layers are protected from the thermal injury by cooling, high laser beam energy can be focused directly into the deeper areas of the hemangioma without burning the overlying skin.
intralesional bare fibre	After puncturing the deep parts of the hemangioma by a Teflon canula, a fresh broken bare fibre is introduced through this canula and directly positioned in the lesion's centre. To avoid any damage to the canula a distance of approximately 5 mm between the tip of the bare fibre and the end of the canula has to be kept. The lesion is treated in a fan-shape fashion with a maximum power of 5 W. In parallel, the temperature of the laser irradiated tissue has to be controlled constantly by two finger tips to cessate the laser application immediately, if necessary.

Table 2: Details of surgical laser techniques applied.

Table 1 Pat B.C.	presented after previous (accidental) treatment of her hemangioma as an abscess. After 2 laser sessions (intralesional and ice cube cooling-technique, Median 13 075 J/cm ² /session) a significant reduction in redness/ erythema and involution could be achieved (Figure 1).
Pat K.I.	presented with persistent pain around her right nipple after first laser therapy 5 years ago. With one intralesional laser session (Median 500 J/cm ² /session) the swelling and pain could be reduced (Figure 2).
Pat Sch.E.	presented with a constantly growing bluish swelling of her right breast. According to her mother the swelling has arised over the last weeks. After 3 laser sessions (ice cube cooling and intralesional technique, Median 5 750 J/cm ² /session) swelling and growth stopped and involution started (Figure 3).
Pat M.T.	PELVIS/LUMBAR syndrome, presented with a rapidly growing and ex-ulcerating hemangioma in the perineal region. Exulceration and growth stopped during her 4 laser sessions (ice cube cooling-technique, Median 1 250 J/cm ² /session). But, despite of this positive response the mother decided to switch to herbal medicine and the girl has been lost for follow-up (Figure 4).
Pat H.M.	presented with repeated ulceration and hemorrhage of her left big labial hemangioma. Immediately after her first laser session (glass plate-compression and ice cube cooling-technique, Median 11 500 J/cm ² /session) ulceration and bleeding stopped and involution started. On parental request hydrocolloid dressings have been applied, intermittently (Figure 5).

Table 3: Results of MALT at-a-glance.

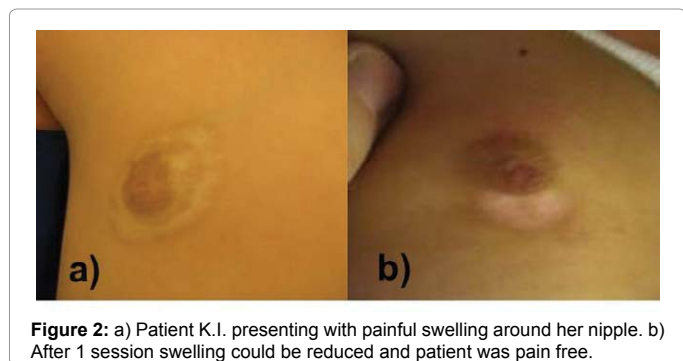


Figure 2: a) Patient K.I. presenting with painful swelling around her nipple. b) After 1 session swelling could be reduced and patient was pain free.

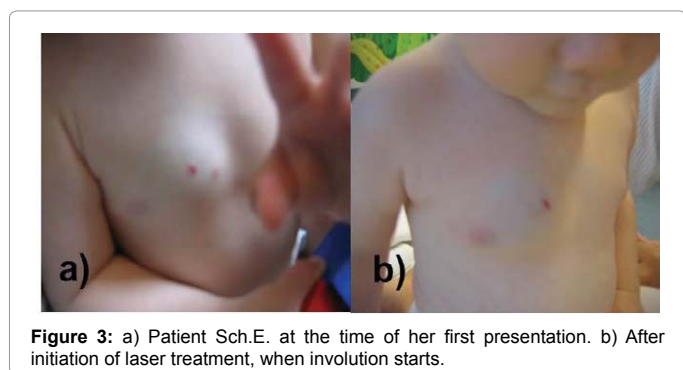

Figure 3: a) Patient Sch.E. at the time of her first presentation. b) After initiation of laser treatment, when involution starts.

ulceration can happen anytime, before, during or after any type of treatment, at least a superficial ulceration is nowadays considered more and more as normal course, or regular part of the treatment than as a complication per se [4,7,18,23,26-33].

But, despite this high overall complication rate, the rate of the “so far not-treated”, and the “traditional wait & see approach” at the time of their first consultation can still reach up to 49% ! [3,27,34], which is in coincidence with the author’s personal experience. In addition, any identified (or unidentified) psychological distress is significantly associated with extra medical complications, but never with the

lesion site or surface area. And, with any repeated intervention, regardless if based on a real or just imaginary medical complication, the expectations, worries and concerns of the parents immediately increase manifold as well. That is why several studies end up with the expression of substantial parental dissatisfaction with nearly all aspects of the medical care of their children’s hemangioma [21].

Obviously there is no real doubt that almost all hemangiomas finally “involute”. But, what is really meant by this, and is that grade of involution (nowadays) really satisfying and acceptable enough [7,24] ?? On the other hand, authors advocating in general against any early intervention, may have underestimated the fact, that in reality every hemangioma will definitely leave a “residuum” behind [14,20,25,27,35]. And that both, final “involution” and “residuum” to date might be considered as absolutely unacceptable. Too far away from actual standards raised by patients, parents and the (medical) society for a sensitive body area like the genitals.

In contrast, any over-aggressive treatment or previously ill-planned surgery, when indeed followed by a good involution, will left the child behind with a grossly deformed or deficient body part as soon as he/she gets older [14,19,20,25,27,35]. Which, of course, will be unacceptable, too.

Thus, the risk of a small physical scar, resulting out of a well-planned early active treatment, should always be weighted up against the sequelae a lifelong emotional scar will have. Especially, when nowadays we are able to treat genitary hemangiomas more safe and easily, thanks to the recent advances in medical science. And this not only for lesions, that would otherwise leave a grossly unacceptable result behind. Quite contrary, these advances now permit treatment safe enough to prevent these children from suffering any of the negative psychological impacts such genitary hemangiomas might have on them in their future life [7].

Surgical treatment options for (genitary) hemangiomas are mainly cryosurgery, plastic surgical excision and laser surgery among others [7,16,17,36-38].

While cryosurgery is widely used in Europe, less experience is found in the United States due to its proposed potential for more extensive

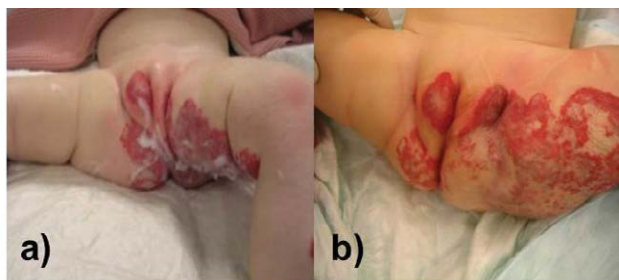


Figure 4: a) Patient M.T. on admission presenting with extended gluteal-perineal-genital hemangiomas. b) Showing ulceration in due course, but responding well to NdYAG laser therapy.

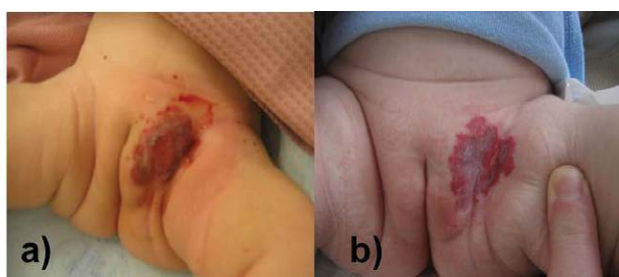


Figure 5: a) Patient H.M. with her isolated ulcerated and bleeding labial hemangioma. b) Ulceration and bleeding stopped immediately after NdYAG laser application.

scarring [16,17,30,39]. In Germany indeed, in order to prevent maceration and infection of hemangiomas in the ano-genital area, and by supporting the philosophy of considering such hemangiomas as a “cosmetic emergency”, the use of cryosurgery in form of Peltier elements or ice cube-cooling is recommended as early as possible, and not found to be associated with an increased scarring potential [16,17,28,38, 40,41].

Indications for surgical hemangioma removal in delicate areas are seen quite restrictive in both, past and present guidelines. In the majority indications are limited to function-threatening lesions, serious complications, non-responders to pharmacotherapy, or other less invasive alternatives. Respectively, when most probably a fibrofatty or involuted residuum will finally stay behind, that can be excised easily without leaving behind a significant cosmetic deformity, or the lesion persists showing atypical (malignant) growth. However, in each individual case the final rate of involution, the most likely prognosis and the parental desires and expectations must be weighted up carefully and seriously against the ultimate results, that can be achieved by other treatment modalities [7,30,33,39,42].

In 1988, Berlien and co-workers, later joined by Apfelberg et al. and Clymer et al., introduced Nd:YAG laser for the treatment of hemangiomas with promising results. Shortly thereafter, it has become a general agreement, that laser therapy will be a valuable tool in rendering an inoperable lesion into a safely resectable one. Respectively in treating lesions, that interfere with body orifices, by markedly decreasing the lesion’s size and functional impact [4,7,8,20,41].

Since the wavelength of the Nd:YAG laser is mainly absorbed in blood in comparison to other tissues, its main effect as the result out of its deep penetration and widespread scattering is below the surface and within the hemangiomatous tissue [8,9]. Therefore, additional cooling and/or compression should be applied to protect the overlying

epidermis and all other tissue layers from unwanted thermal injury. Here any type of pre-, intra- and post procedural cooling and/or compression, applied either alone or in combination, will be able to reduce the adverse laser effects on collagen stimulation and the risk of a thermal injury. In addition, by stimulating the vasoconstriction of the vessels, which subsequently leads to diminished blood flow, Nd:YAG laser administration will be even made more effective [8,28,38,40,41,43,44]. Thus, the combination of these techniques combines all the positive laser- and cryosurgical effects to its best.

All laser parameter settings and application techniques have been adjusted according to the recommendations of globally renowned laser operators [5,8,9,15,20,38,42] and our own experience [7,43,44].

Each individual treatment usually consisted out of multiple Nd:YAG laser sessions performed under general anesthesia. General anesthesia is mandatory, because the laser beam is painful, and will have hazardous effects on ie the eyes, when operated uncontrolled in a struggling and fighting child. For many carers this immanent multi-session schedule is sufficient enough to reject the laser option forever. Obviously and for sure, any “restraining-torture”-management is absolutely inappropriate and unacceptable, even when so far no long term psychological effects after repetitive painful treatments to a restrained young child are determined in the medical literature. In addition, the physical and mental health risks of repeated general anesthetics to a young child are still undetermined as well. On the other hand, there are no reports either, that a well-balanced and monitored pediatric anesthesia will have a harmful impact on the regular development of these little patients [19,45]. Last but not least, the decision made for the need of general anesthesia in children has always to be based on a correct indication and its real need for this specific pediatric surgical procedure. Thus, any detainment will be definitely more harmful and more disadvantageous for the child’s well being [19,45].

In the majority of cases our Nd:YAG laser patients have been served safely on a day case basis, which is in coincidence with a literature review [32]. Follow-up schedules after Nd:YAG hemangioma laser treatment are various, with some authors requesting 2-6 weeks intervals during active treatment, followed by 3 months intervals for the first year. Thereafter, yearly visits for a maximum of 8 (Mean 6) years have been recommended [4,28,42]. However, since the exact time, when ulceration and hemorrhage, or “changes” in the genitourinary hemangioma’s appearance or laser response occur, will be hard to determine in advance, providing the child and his/her parents with a flexible schedule like in this collective might be more advantageous.

Briefly, in coincidence with our results the Nd:YAG laser is a valuable and successful tool in treatment of genitourinary hemangiomas in girls. Especially, since this laser has proven to prevent excessive growth and to promote involution in all types of hemangiomas with minimal adverse effects. Its effects are even more pronounced, when applied early, and most effective, when used in combination with cooling and compression techniques [7,8,38].

Mainly in the past and despite controversy about their real effectiveness, systemic or intralesional steroids have been considered as a mainstay in hemangioma treatment. But, quite a considerable number reported severe adverse effects, like moon facies, behavioural changes, osteoporosis, irritability, immunosuppression and growth retardation [3,4,6,7,20,24,25,27,28,30-33,35,42,46]. That is why steroids have never been considered seriously in our hemangioma management policies.

By chance, French authors detected in the year 2008, that propranolol has been able to stop hemangiomas’ growth. Since it

has been acting so powerful, it has been proposed, that it might have the potential to cause a paradigm shift in their future management [11,14,26,46]. So far, common indications are large hemangiomas in endangering localization [11,14,46,47]. Propranolol treatment should always start as soon as possible during the proliferation phase [46]. In the meantime, promising results after topical application have been found, too [47].

Shortly summarized

Propranolol is currently used worldwide as well as in the author's daily practice for all types of hemangiomas with an impressive effect and a low toxicity profile. But it has to be kept in mind, that final pediatric pharmaceutical approval is still pending [7,48]. Propranolol is likely to play a substantial role in the treatment of genitourinary hemangiomas in the near future. Either alone or in combination with the Nd:YAG laser device. However, since propranolol has not been inaugurated when this study started, it has not been tested in this patient collective. The evaluation of the results after Nd:YAG laser therapy is usually based on the following standard criteria: reduction in size and area of the target lesion, the amount of laser energy applied, and the number of treatment sessions needed to achieve this actual result [7,41]. Others, that have to be mentioned are changes in morphological appearance, improvement in function and the elimination of complications, like ulceration and hemorrhage [8,29]. Since especially ulceration and pain are always a major concern in treatment of genitourinary hemangiomas, many authors have put their focus on it. While in the past, Lacour et al. exclusively favoured conservative management, with local cleaning, application of topical antimicrobials, and systemic antibiotics, they later have changed to pulsed dye laser treatment, because of its rapid alleviation of pain, and the early restoration of micturition and defecation. But in contrast to our results, they experienced Nd:YAG laser treatment or cryosurgery as a complete failure [7,36]. In a more recent publication, Dixon and Gilbertson have recommended specifically the use of the argon laser for ulceration and bleeding complications, or hemangiomas encroaching into body orifices. But, it has to be considered, that the authors described their "successful" results in a way, that "the lesion usually become ulcerated without bleeding", and that one of the earlier classification schemes has been in use. They mentioned the Nd:YAG laser only briefly and without any further specification [37]. In their current publication Vlachakis and co-workers' objective has been to determine, whether or not the cooling of the epidermis during Nd:YAG laser irradiation prevents thermal damage and decreases the number of sessions required to treat such lesions. Like in our study, a comparable proportion of cases complicated by ulceration and bleeding, endangering impairment of important functions, or significant cosmetic disfigurement and psychological problems related to the patient's appearance has been presented. None of the patients have received any other treatment such as steroids, but antibiotics have been used as a routine. Vlachakis et al., of course, have been intending primarily on cutaneous and facial rather than on genitourinary and extracutaneous hemangiomas like we did, but complications and cosmetic disfigurement reported for both collectives seem to be comparable enough to support the early treatment for both. Suitable treatment therefore means early Nd:YAG laser irradiation in combination with ice protection of the epidermis, since this has produced good cosmetic results and decreased the number of treatment sessions finally needed [38].

As already mentioned, the combination of Nd:YAG laser, cryosurgery and surface cooling is nowadays a valuable tool in the treatment of genitourinary hemangiomas and to combine it with propranolol might be even more superior in the future.

All genitourinary hemangiomas have been documented and photographed on a regular basis. Because, their real appearance is too quick and easily forgotten in the majority of cases, so that a "before and after" picture right in hand, would always serve and has always served as the perfect "reminder" and great "morale booster" for both, parents and children alike [4,8,23,29,42].

"Lesions in cosmetically strategic locations, such as the face, genitalia and nipple area can also be considered endangering in a sense, that they are more prone to ulceration, superinfection and pain, and that they can produce permanent disfigurement and psychological issues to the patient and his/her family..." [11,49]. For the first time this statement has paid real attention to the particular concerns, patient, parents and carers usually encounter, when they have to face a hemangioma in the genital area. Plus concerns about atrophy or unwanted scarring after involution, especially when the breast, the breast bud, or the nipple area are at risk.

Bava et al. have presented a case report on a capillary vulvar hemangioma, that has been complicated by life-threatening hemorrhage, not responsive to corticosteroid therapy, and that showed no signs of spontaneous involution. Their therapeutic approach consisted out of 3 selective arterial embolization sessions, followed 5 months later by surgical excision and reconstruction of the vulva. Selective embolization has been rarely used in the treatment of hemangiomas, but in this case it has been a good option in preparing for the final surgery [50].

Baetz et al. reported on a 4 month old baby suffering from a 5x3 cm big ulcerating hemangioma on her left labia majora. Systemic treatment with off-label-use of propranolol has been initiated. After a few weeks, the size and color of the hemangioma has been reduced, and 5 ½ months later almost complete regression has been achieved [49].

Both publications re-underline again, that hemangiomas of the genitals are a clear indication for early active treatment.

Iacobas et al. conducted a multi-institutional, retrospective case analysis on the LUMBAR syndrome based on their patients and published cases in order to assess the potential risk for underlying anomalies in regard to the hemangioma's specific location. Most hemangiomas tended to be "segmental" and "off minimal growth" in morphology. Such lesions often have been extensive, covering the entire leg. Such extensive limb hemangiomas showed a high potential for extracutaneous anomalies, like ulceration, limb underdevelopment or underlying arterial anomalies. The cutaneous hemangioma and its underlying anomalies demonstrated regional correlation and myelopathies have been the most commonly associated [51]. By trying to subclassify our patient, we found female predominance, too, segmental, but "fast and extensive" growth, and involvement of more than one region. In fact, all regions have been involved plus extension across the midline. Like in their patients, ulceration has been extensive, the extracutaneous anomaly found has been tethered cord, and in MRI evidence of myelopathy has been shown.

Conclusion

Main goals in treatment of genitourinary hemangiomas are minimization of complications, like ie ulceration, hemorrhage or pain, full restoration of function, maximization of the cosmetic appearance, the minimization of the emotional trauma and a significant decrease in time and age at which the final result could be obtained. The MALT and cryotherapy seems to be valuable tools in achieving this.

Limitations of this study are: the small number of cases and their

short follow-up. The broad variance within the diagnosis “genitary hemangioma” and the different classification schemes used in literature reviews, making it hard to quantify the outcome in a retrospective study design.

References

1. Schaarschmidt K (2000) Tumorchirurgie, Hämangiome, In Willital GH, Lehmann RR, 956-965.
2. Puri P, Nemeth L (2003) Hemangiomas and vascular malformations, chapter 71, Arnold Publisher, London.
3. Stringel G (1980) Hemangiomas and Lymphangiomas. (2nd edn), W.B. Saunders Company, Philadelphia, London, Toronto.
4. Burstein FD, Simms C, Cohen SR, Williams JK, Paschal M (2000) Intralesional laser therapy of extensive hemangiomas in 100 consecutive pediatric patients. *Ann Plast Surg* 44: 188-194.
5. Léauté-Labrèze C, Prey S, Ezzedine K (2011) Infantile haemangioma: part II. Risks, complications and treatment. *J Eur Acad Dermatol Venereol* 25: 1254-1260.
6. Ron GC, Pasquali P (1997) Management of Hemangiomas, *Pediatr Dermatology* 14: 57-83.
7. Fette A (2013) Management of facial hemangiomas by pediatric surgical laser therapy, chapter 1, *Advances in Medicine and Biology*.
8. Poetke M, Philipp CM, Urban P, Berlien HP (2004) Laser therapy of hemangiomas and vascular malformations - techniques and strategies. *Med Laser Appl* 19: 32-44.
9. Poetke M, Berlien HP (2005) Laser treatment in hemangiomas and vascular malformations. *Medical Laser Application* 20: 95-102.
10. Hassanein AH, Mulliken JB, Fishman SJ, Greene AK (2011) Evaluation of terminology for vascular anomalies in current literature. *Plast Reconstr Surg* 127: 347-351.
11. Restrepo R, Palani R, Cervantes LF, Duarte AM, Amjad I, et al. (2011) Hemangiomas revisited: the useful, the unusual and the new Part 2: endangering hemangiomas and treatment. *Pediatr Radiol* 41: 905-915.
12. Bourrat E, Lemarchand-Venencie F, Jacquemont ML, El Ghoneimi A, Wassef M, et al. (2008) [PELVIS/SACRAL syndrome with livedoid haemangioma and amniotic band]. *Ann Dermatol Venereol* 135: 855-859.
13. Léauté-Labrèze C, Prey S, Ezzedine K (2011) Infantile haemangioma: Part I. Pathophysiology, epidemiology, clinical features, life cycle and associated structural abnormalities. *J EADV*, 25: 1245-1253.
14. Hochman M, Adams DM, Reeves TD (2011) Current Knowledge and Management of Vascular Anomalies I. Hemangiomas. *Arch Facial Plast Surg* 13: 145-151.
15. Schmittenebecher PP, Grantzow R, Klia-Lange D (1993) Ergebnisse nach perkutaner Lasertherapie kutaner Angiome, *Angewandte Lasermedizin* 6.
16. Cremer H, Djawari D (1995) Zur Frühtherapie der planen und planotuberösen Hämangiome mittels Kontaktkyrochirurgie. *Monatsschr Kinderheilkd* 143: 365-368.
17. Bause H (2004) Kryotherapie lokalisierter klassischer Hämangiome. *Monatsschrift Kinderheilkunde* 152: 16-22.
18. Rogers M (1997) Management of Hemangiomas, *Pediatr Dermatology* 1: 57-83.
19. Strauss RP, Resnick SD (1993) Pulsed dye laser therapy for port-wine stains in children: psychosocial and ethical issues. *J Pediatr* 122: 505-510.
20. Apfelberg DB, Maser MR, White DN, Lash H (1989) A preliminary study of the combined effect of NdYag laser photocoagulation and direct steroid instillation in the treatment of capillary/cavernous hemangiomas of infancy. *Annals of Plastic Surgery* 22: 94-104.
21. Tanner JL, Dechert MP, Frieden IJ (1998) Growing up with a facial hemangioma: parent and child coping and adaptation. *Pediatrics* 101: 446-452.
22. Dieterich-Miller CA, Safford PL (1992) Psychosocial development of children with hemangiomas: home, school, health care collaboration. *Child Health Care* 21: 84-89.
23. Roberts LJ (1997) Management of Hemangiomas, symposium editor, *Pediatr Dermatology* 14: 57-83.
24. Waner M, Suen JY (1997) Management of Hemangiomas, *Pediatr Dermatology* 14: 57-83.
25. Williams EF 3rd, Stanislaw P, Dupree M, Mourtzikos K, Mihm M, et al. (2000) Hemangiomas in infants and children. An algorithm for intervention. *Arch Facial Plast Surg* 2: 103-111.
26. Weiss I, O TM, Lipari BA, Meyer L, Berenstein A, et al. (2011) Current treatment of parotid hemangiomas. *Laryngoscope* 121: 1642-1650.
27. Achauer BM, Chang CJ, Vander Kam VM (1997) Management of hemangioma of infancy: review of 245 patients. *Plast Reconstr Surg* 99: 1301-1308.
28. Vlachakis IA, Velaoras K, Charissis G (2004) Different modes cooling the epidermis with ice during Nd:Yag laser treatment of hemangiomas in children. *Med Laser Appl* 19: 19-23.
29. Achauer BM, Celikoz B, VanderKam VM (1998) Intralesional bare fiber laser treatment of hemangioma of infancy. *Plast Reconstr Surg* 101: 1212-1217.
30. Adams DM, Lucky AW (2006) Cervicofacial vascular anomalies. I. Hemangiomas and other benign vascular tumors. *Semin Pediatr Surg* 15: 124-132.
31. David LR, Malek MM, Argenta LC (2003) Efficacy of pulse dye laser therapy for the treatment of ulcerated haemangiomas: a review of 78 patients. *Br J Plast Surg* 56: 317-327.
32. Edgerton MT (1982) Vascular hamartomas and hemangiomas: classification and treatment. *South Med J* 75: 1541-1547.
33. Batniji RK, Buckingham ED, Williams EF (2005) An aesthetic approach to facial hemangiomas. *Arch Facial Plast Surg* 7: 301-306.
34. Finn MC, Glowacki J, Mulliken JB (1983) Congenital vascular lesions: clinical application of a new classification. *J Pediatr Surg* 18: 894-900.
35. Zide BM, Glat PM, Stile FL, Longaker MT (1997) Vascular lip enlargement: Part I. Hemangiomas—tenets of therapy. *Plast Reconstr Surg* 100: 1664-1673.
36. Lacour M, Syed S, Linward J, Harper JI (1996) Role of the pulsed dye laser in the management of ulcerated capillary haemangiomas. *Arch Dis Child* 74: 161-163.
37. Dixon JA, Gilbertson JJ (1985) Cutaneous laser therapy. *West J Med* 143: 758-763.
38. Vlachakis I, Gardikis St, Michailoudi E, Charissis G (2003) Treatment of hemangiomas in children using a Nd:YAG laser in conjunction with ice cooling of the epidermis: techniques and results. *BMC Pediatrics* 3.
39. Grantzow R (2004) Chirurgische Therapie von Hämangiomen. *Monatsschrift Kinderheilkunde* 152: 23-28.
40. Pham RT (2001) Treatment of vascular lesions with combined dynamic precooling, postcooling thermal quenching, and ND:YAG 1,064-nm laser. *Facial Plast Surg* 17: 203-208.
41. Clymer MA, Fortune DS, Reinisch L, Toriumi DM, Werkhaven JA, et al. (1998) Interstitial Nd:YAG photocoagulation for vascular malformations and hemangiomas in childhood. *Arch Otolaryngol Head Neck Surg* 124: 431-436.
42. Ulrich H, Bäuml W, Hohenleutner U, Landthaler M (2005) Neodymium-YAG Laser for hemangiomas and vascular malformations – long term results. *J Dtsch Dermatol Ges* 3: 436-440.
43. Fette A, Yonekawa K, Kothbauer KF (2006) Use of microsurgical laser in paediatric surgery and paediatric neurosurgery. *Technol Health Care* 14: 507-513.
44. Fette A (2007) Facial enhancement in children using lasers. *Lasers in Surgery and Medicine suppl* 19: 144.
45. Jöhr M (2006) [Does anesthesia damage children's brains?]. *Anaesthesist* 55: 465-466.
46. Weibel L (2009) Propranolol – eine neue Therapie für infantile Hämangiome. *Paediatrica* 20: 27–29.
47. Ni N, Guo S, Langer P (2011) Current concepts in the management of periorcular infantile (capillary) hemangioma. *Curr Opin Ophthalmol* 22: 419-425.
48. Fette A (2013) Propranolol in Use for Treatment of Complex Infant Hemangiomas. Literature Review Regarding Current Guidelines for Preassessment and Standards of Care before Initiation of Therapy. Review article. *The Scientific World Journal* 9.
49. Baetz J, Eigelshoven S, Marquard J, Bruch-Gerharz D, Homey B, et al. (2010) [Infantile hemangioma. Successful treatment with propranolol]. *Hautarzt* 61: 290-292.
50. Bava GL, Dalmonte P, Oddone M, Rossi U (2002) Life-threatening hemorrhage from a vulvar hemangioma. *J Pediatr Surg* 37: 36.
51. Iacobas I, Burrows PE, Frieden IJ, Liang MG, Mulliken JB, et al (2010) LUMBAR: Association between Cutaneous Infantile Hemangiomas of the Lower Body and Regional Congenital Anomalies. *The Journal of Pediatrics*.