

Research Article

Open Access

Lateral Malleolus Hook-Plate Fixation in the Treatment of Herscovici Type B Medial Malleolar Fractures: The Clinical Evaluation of an Alternative Fixation Technique

Kai Xiao*, Zhen-hua Fang and Cheng Hao

Department of Foot & Ankle Surgery, Wuhan Fourth Hospital, Puai Hospital, Tongji Medical College, Huazhong University of Science and Technology, China

Abstract

Background: To evaluate the availability of lateral malleolus hook plate fixation for medial malleolar fractures.

Materials and Methods: 23 patients with Herscovici type B medial malleolar fractures were involved as subjects between January 2013 and December 2015. All the patients had undergone lateral malleolus hook plate fixation surgery. 6 males and 17 females with an average age of 46.0 ± 12.4 years (range, 22-62 years) were identified. All of the fractures were evaluated based on Herscovici medial malleolar fractures classification. Postoperatively, radiographs was used to assess the quality of bone union directly at the follow-up examination. The clinical evaluation was based on the American Orthopaedic Foot and Ankle Society (AOFAS) scoring system.

Results: 21 patients had adequate follow-up for clinic evaluation. The mean follow-up period was 18.6 ± 4.2 months (range; 13–28 months). Full union was achieved in all fractures with mean time of 12.9 ± 2.03 weeks (range, 10-16 weeks). The mean AOFAS score was 94.1 ± 4.4 (range; 87–100) at final follow up. The mean range of injured ankle plantar flexion and dorsi flexion motion were 40.6 ± 2.8 (range; 35–45) and 15.4 ± 2.7 (range; 10–20) respectively in post-operation at final follow up. The injured ankle motion presented good rehabilitation. Based on AOFAS evaluation standard, the outcome was excellent in 18 cases and good in 3 cases.

Conclusion: In this study, lateral malleolus hook-plate fixation yielded good clinical outcome in surgical treatment of Herscovici type B fractures.

Keywords: Medial malleolus; Herscovici fracture classification; Lateral malleolus hook plate; Fixation technique

Introduction

The medial malleolus is crucial importance for keeping the stability of ankle. Whether isolated or a more complex pattern of medial malleolus fractures, optimal fixation methods should be concerned [1]. The aim of operative treatment in ankle fractures is to provide stable internal fixation and allow early motion. The situation of the reduction of medial malleolar fractures can predict the change of the biomechanical tibiotalar joint contact surface and pressure [2]. The anatomic reduction of the ankle fracture is considered as one of the key factors to obtain optimum clinical outcome. It has been shown by Ramsey and Hamilton that even a 1mm shift of the talus within the mortise produces a decrease of 42% of joint contact area [3].

There are several options about implants used to fix medial malleolar fractures. The current literature suggests to fixation for the anatomic reduction of the medial malleolus fractures. Kirschner wire (K-wire) and tension band method, screw-only fixation, fixation with suture anchors, bio-absorbable screw fixation, a Fiber Wire loop with a tension band, and bicortical screw fixation and the use of neutralization plates, et al. have been reported [4-10]. In addition to these techniques, fixation with headless compression screw can also be used for medial malleolar fixation [11]. These methods can deal with majority cases in general. However, in some special cases (Type B medial malleolus fractures according to Herscovici classification in 2007) [12], smaller fracture fragments that are not amenable to typical screw fixation, even if the Kirschner wire (K-wire) and tension band method. They can not provide stability to comminuted fracture fragments, prevent rotation and apply compressive forces across fracture sites. How to fix these small fracture fragments, keep optimal compressive forces across fracture sites and restore the ankle mortise is concerned as a challenge for surgeons.

Biomechanical studies have assessed the strength and durability of different types of implant, plates were determined to provide a significant amount of “mechanical advantage” over other methods in fixation of medial malleolus fractures [10]. Therefore, plate fixation should be concerned as a suitable method to keep fracture fragments stability in medial malleolus fractures. However, it may be impossible to apply regular plate to fix Herscovici Type B medial malleolus fractures. As an alternative fixation, the hook plate is considered as an optimal fixation method in Herscovici Type B medial malleolus fractures. This type of fixation has the benefit of the screw and K-wire and tension band method in Type B, thus possibly minimizing complaints of nonunion. Therefore, this study was designed to evaluate the functional and radiological outcomes following fixation with lateral malleolus hook plate in the Treatment of Herscovici Type B medial malleolar fractures.

Materials and Methods

23 patients were involved as subjects who had undergone surgery for a medial malleolar type B fracture based on the Herscovici fracture classification system between January 2013 and December

***Corresponding author:** Kai Xiao, Department of Foot & Ankle Surgery, Wuhan Fourth Hospital, Puai Hospital, Tongji Medical College, Huazhong University of Science and Technology, China, Tel: 0086-13476829220; E-mail: xiaokai1125@163.com

Received November 24, 2017 ; **Accepted** December 11, 2017; **Published** December 18, 2017

Citation: Xiao K, Fang Zh, Hao C (2017) Lateral Malleolus Hook-Plate Fixation in the Treatment of Herscovici Type B Medial Malleolar Fractures: The Clinical Evaluation of an Alternative Fixation Technique. Orthop Muscular Syst 7: 250. doi:10.4172/2161-0533.1000250

Copyright: © 2017 Xiao K, et al. This is an open-access article distributed under the terms of the Creative Commons Attribution License, which permits unrestricted use, distribution, and reproduction in any medium, provided the original author and source are credited.

2015. Approval for the study was granted by the Institutional Ethics Committee of Wuhan Puai Hospital affiliated to Tongji Medical College of HUST.

The exclusion criteria was: open fracture, a pathological fracture and infection or multitrauma. 6 males and 17 females, with a mean age of 44.0 ± 12.4 years (range, 22-62 years), included in the study. 2 patients had isolated medial malleolar fractures, 11 patients had bimalleolar fractures, and 10 patients had trimalleolar fractures. All patients with Herscovici type B (Figure 1) medial malleolar fractures. All fractures were closed. The etiologies of the fractures were a sports injury in 12 patients and a simple fall in the other 11 patients.

Fibula fractures were fixed with the plate and screw in bimalleolar fractures and trimalleolar fractures. Medial malleolar fractures were all fixed with lateral malleolus hook plate (Königsee Implantate GmbH. Am Sand 4 / OT Aschau D-07426 Allendorf, Germany).

At the postoperative follow-up examination, radiographs as the method to assess the quality of bone union directly. Disappearance of the fracture line and appearance of a bridging callus on X-ray suggested bone union. The clinical evaluation was based on the American Orthopaedic Foot and Ankle Society (AOFAS) scoring system

Surgical technique

The patients were positioned supine on an operating table. After performed anesthetization, tourniquet hemostasis was administered. The surgeon disinfected the affected extremity and then covered with sterile draping.

A longitudinal incision was made along the posterior or posterolateral edges of the distal fibula in cases of bimalleolar or trimalleolar fractures. Following fracture reduction, fibula fracture and posterior ankle fracture were fixated via this incision by plate and screws.

Based on the center of the medial malleolus, a medial incision of

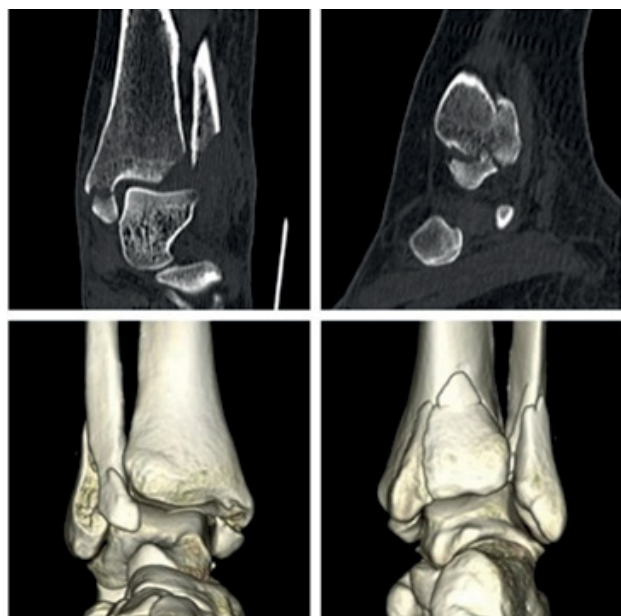


Figure 1: A 35-year-old woman with left ankle fresh fracture (AO-44-B3, Lauge-Hansen Supination eversion rotation fracture type IV) (medial malleolar fracture of Herscovici type B). Preoperative CT, showing left ankle fracture (Herscovici type B).

approximately 4-5 cm was then made, which curved distally to the anterior surface. The saphenous vein and nerve should be protected. After exposing the medial malleolus fracture line, then the soft tissue in the fracture line was cleared off, and the distal part of the medial malleolus was measured. Reduction of the medial malleolus fracture, and then one or two 1.2 mm thick K-wires were fixed from distal end of the fracture fragment to the proximal part of the fracture. The medial malleolus was then fixed with a lateral malleolus hook plate which firstly the hook will grasp distal part of the fracture fragment, and fix the plate with a slide hole screw at proximal articular surface of distal tibial. After reduction of fracture and keep proper compression on the hook plate from distal to proximal, subsequently the slide hole screw was fasten. Fixing all the other screws at last. The soft tissues were sutured layer-by-layer appropriately. The tourniquet was opened, and the blood circulation was checked. After that a short-leg splint was applied.

Postoperative mobilization of knee was allowed. The splint was removed in the second week following soft tissue healing, then ankle exercises was started. Partial weight bearing was permitted after radiological healing was observed and when the clinical examination was pain-free. After the 8th week, all patients were permitted to use a single crutch, and after the 10th week, unaided ambulation was allowed.

Statistical analyses

The SPSS for Windows version 19.0 software (SPSS Inc., Chicago, Ill., USA) was used for statistical analysis. The mean, standard deviation, range, median, minimum and maximum as factors were included in descriptive statistics. T-test was used to compare the range of ankle motion.

Results

23 ankles were fixed via lateral malleolus hook-plate and 21 had adequate follow-up for clinic evaluation. The average length of follow-up was 18.6 ± 4.2 months (range; 13-28 months).

Radiographic evidence of fracture union was noted in all patients (Figures 2-5). None of the patients requested or required hardware removal from plate prominence. Full bone union was achieved in all fractures. The mean time to union was 12.9 ± 2.03 weeks (range, 10-16 weeks).

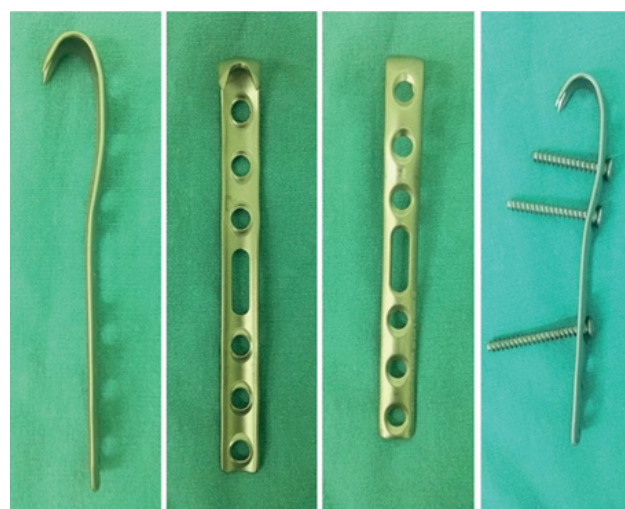


Figure 2: View of the hook plate and screws (Königsee Implantate GmbH. Am Sand 4 / OT Aschau D-07426 Allendorf, Germany).

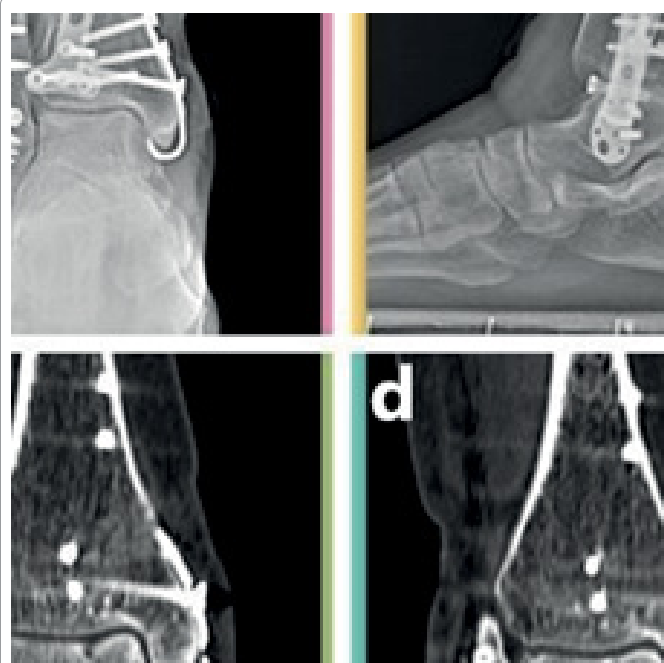


Figure 3: Postoperative X-rays of the same patient. (a) and (b) is the X-ray of post-op at 3 days.

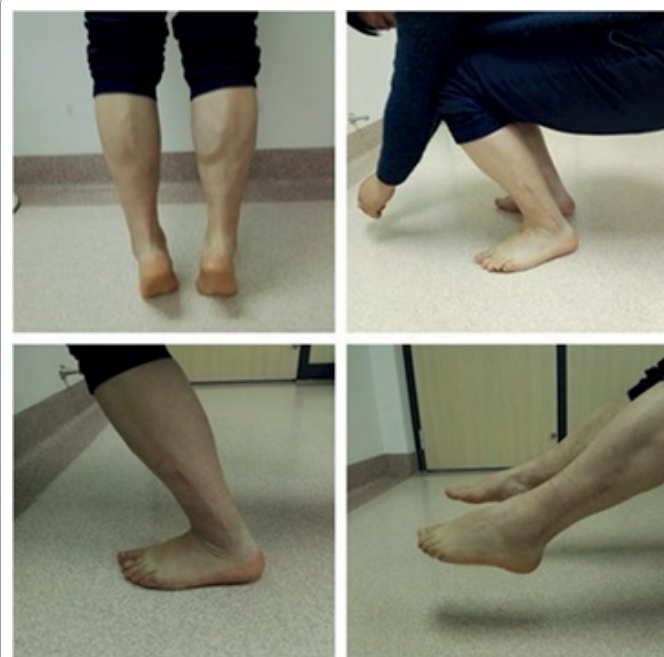

Figure 4: Postoperative X-rays and CT of the same patient. (a) and (b) is the X-ray of post-op at 15 weeks, (c) and (d) is the CT of post-op at 15 weeks indicating bone union of the fracture.

Instability, loss of reduction, non-union or infection was not observed in these patients. The mean AOFAS score was 94.1 ± 4.4 (range; 87-100) at final follow up and 89, 87, 87 who were less than 90 were evaluated finally on 3 patients respectively. Based on AOFAS evaluation standard, good outcomes were obtained in 3 patients and excellent in 18.

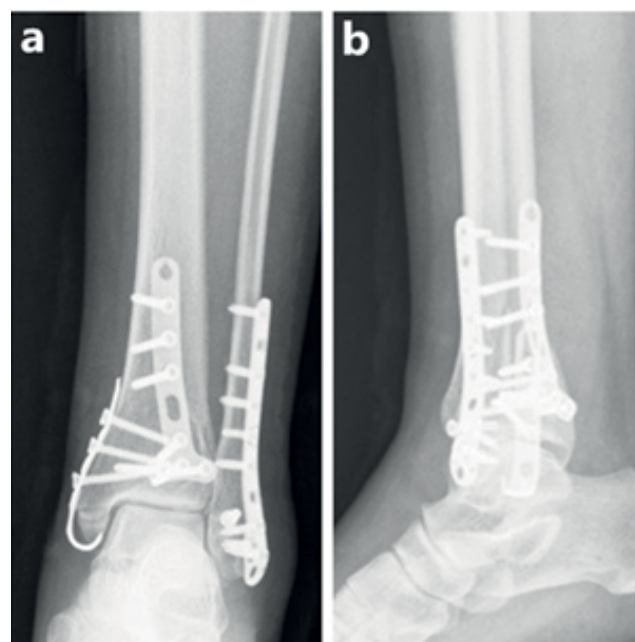


Figure 5: Excellent functions of ankle plantar flexion and dorsiflexion at 1 year after operation.

The mean range of injured ankle plantar flexion motion was 40.6 ± 2.8 (range; 35-45) in post-operation at final follow up. The mean range of injured ankle dorsi flexion motion was 15.4 ± 2.7 (range; 10-20) in post-operation at final follow up.

Discussion

In this study, the hook plate fixation was a good option for the treatment of Herscovici type B fractures because of the good and excellent outcome in all the patients: high union rate and no major complications were observed during follow-up. Patients did not complain soft tissue irritation caused by hardware. The mean union time was 12.9 weeks which was similar to those reported previously [7,13,14]. In our study, those patients did not report discomfort at the surgical site probably since lateral malleolus hook plate has a curve at the distal of malleolus medialis and maybe decreases the risk of hardware prominence and soft tissue irritation. In this study, the hook plate fixation for the treatment of Herscovici type B fractures was efficient and was reported limited discomfort.

In the current study, surgical treatment was used rather than conservative monitoring to achieve anatomic reduction because the fractures were intra-articular [15]. Medial malleolar fractures are generally treated surgically [16]. According to Herscovici classification [12], Type A is Avulsion fracture of the anterior colliculus involving the superficial deltoid ligament; Type B is Intermediate fracture; Type C is Fracture at the level of the plafond (Lauge-Hansen external rotation-abduction type) and Type D is Plafond fracture (Lauge-Hansen supination-adduction type). Generally, the Kirschner wire (K-wire) and tension band method and screws fixation can deal with majority cases in general. However, in some Type B medial malleolus fractures, smaller fracture fragments that are not amenable to typical fixation.

The main stress of ankle are load and torsion. To achieve early functional exercise of ankle joint, malleolus fractures should be fixed to get good support and resist torsion, which requires multiple screws

fixation of the distal fracture fragments to provide effective control performance, good compressive capacity. Simultaneously three-dimensional multiple plane fixation is necessary which can obtain good ability to resist torsion [17]. Tension band or screw fixation can easily lead to fracture fragment rupture, internal fixation instability and even nonunion in the treatment of Herscovici Type B medial malleolus fractures. Therefore, a hook plate can be as an option for fixation these fractures. Surgeons commonly utilize hook plates for smaller fracture fragments that are not amenable to typical screw fixation or K-wire tension band method [18,19]. They can provide stability to comminuted fracture fragments, prevent rotation and apply compressive forces across fracture sites. The plate serves to purchase a fracture fragment with its prongs and reduce the fragment to the diaphyseal portion of bone.

We firstly exploratory study to apply lateral malleolus hook plate fixation of such fractures. Although there is no relevant biomechanical studies, no breakage of screws or hook plate occurred in all the patients during follow-up, which testifies that the strength of hook plate can support the tibia distal medial malleolus fracture. We also did not get complains from patient about the deltoid ligament injury during ankle joint function exercise after hook plate fixation medial malleolus fractures. However, it should be noticed that making two 0.5 mm incision line direction by electric knife along the fiber of the deltoid ligament when hook plate was applied in advance. This step was not only conducive to hook fixation, but also can avoid the pull of hook on the deltoid ligament after postoperative function exercise to decrease the discomfort in side of medial malleolus.

In our study, 23 cases of Herscovici type B medial malleolus fractures were fixated with lateral malleolus hook plate since the distal part of the fracture was too small for screw. K-wire tension bands is not easy to keep the stabilization of the small avulsions fractures. Biomechanical studies assessing the strength and durability of different types of implants have previously determined that neutralization plates provide a significant amount of “mechanical advantage” over only using screws for certain fracture patterns [7]. Fixation was achieved in our study with the lateral malleolus hook plate. Furthermore, there is less postoperative irritation of the deltoid ligament from the hook which may be associated with its curve and deep. This likely reduces the possibility of subsequent injury to the deltoid ligament. Although in our study, 3 of the 21 patients achieved an AOFAS score of good rather than excellent because of intermittent pain, persistent pain or pain associated with implant irritation did not occur in any patient in this study.

Compression in the fracture line was previously reported to facilitate union [20]; therefore, compression screws can be selected for fracture fixation. Generally, 2 screws or K-wire tension band should be used to prevent rotation and keep compression [17,21]. However, in Herscovici type B medial malleolus fractures, screws fixation maybe cause fracture fragment rupture and K-wire tension band can not keep good reduction in small avulsion medial malleolus fractures. In our study, hook plate can achieve good reduction and proper tension to promote fracture union. The fixation technique also can prevent rotation of medial malleolus fractures. Non-union was not observed in the medial malleolar fractures treated with hook plate in this study.

In Herscovici type B fractures, the two 3.5 mm screws were not suitable to fix the fracture fragment as the distal part is small, therefore one screw or the tension band method may be a selection for these fractures. If hardware removal with a second manipulation becomes necessary which sufficient rigid fixation cannot be obtained with one

screw or because of irritation in the tension band method, then fixation can be achieved with hook plate as an alternative method.

Overall, the advantages of the lateral malleolus hook plate fixation technique are: (1) The distal end of plate was designed as two sharp hook. The hooks can grasp the distal bone of medial malleolus under compression on the hook plate which the small size of the fractured distal fragment in a medial malleolar fracture is insufficient for conventional fixation. Therefore, the hook plate fixation not only carries pressure effect, but also forms a triangle plane three-dimensional fixation in the distal fractures of medial malleolar to strengthen the ability of anti-torsion. (2) The hook plate with multiple proximal screw holes, can effectively prevent displacement of distal fracture fragment as a checkered plate and will prevent rotation of the distal fracture fragment. (3) Hook plate is titanium alloy products including good histocompatibility and it is thin. Usually the plate fixation does not need to make periosteal stripping which can effectively protect blood supply of the fracture end. Its material and morphological characteristics of the plate possess the performance of elastic fixation which can allow micro motion to facilitate bone healing. (4) Theoretically, the compression provided by the hook plate may lead to improved fracture union rates. However, there are no studies in the literature of the topic. In our result, the hook plate was verified its reliability in the fixation of Herscovici type B fractures.

The limitations of this study were the small number of patients, a lack of a control group, the retrospective design of the study and a short follow-up period. Future studies could be designed to compare biomechanical fixation with screws and the tension band method for repairing small fractures. In addition, it was the first exploratory clinical applications, there is no biomechanical literature support, and therefore biomechanics research should be focus on the next step research.

Conclusion

In this study, hook plate fixation for Herscovici type B fractures had a good and excellent union rate, no complications. Hence, hook plate fixation should be considered as an alternative method in the treatment of medial malleolar fractures requiring fixation.

References

1. Singh R, Kamal T, Roulohamin N, Maoharan G, Ahmed B, et al. (2014) Ankle fractures: A literature review of current treatment methods. *Open J Ortho* 4: 292.
2. Lareau CR, Bariteau JT, Paller DJ, Koruprolu SC, DiGiovanni CW (2015) Contribution of the medial malleolus to tibiotalar joint contact characteristics. *Foot Ankle Spec* 8: 23-28.
3. Hamilton WC (1984) *Traumatic disorders of the ankle*. Springer Science, New York.
4. Ostrum RF, Litsky AS (1992) Tension band fixation of medial malleolus fractures. *J Orthop Trauma* 6: 464-468.
5. Ricci WM, Tornetta P, Borrelli JJ (2012) Lag screw fixation of medial malleolar fractures: a biomechanical, radiographic, and clinical comparison of unicortical partially threaded lag screws and bicortical fully threaded lag screws. *J Orthop Trauma* 26: 602-606.
6. Kupcha P, Pappas S (2008) Medial malleolar fixation with a bicortical screw: technique tip. *Foot Ankle Int* 29: 1151-1153.
7. King CM, Cobb M, Collman DR, Lagaay PM, Pollard JD (2012) Bicortical fixation of medial malleolar fractures: review of 23 cases at risk for complicated bone healing. *J Foot Ankle Surg* 51: 39-44.
8. Fowler TT, Pugh KJ, Litsky AS, Taylor BC, French BG (2011) Medial malleolar fractures: A biomechanical study of fixation techniques. *Orthopedics* 34: e349-355.
9. Rangdal S, Singh D, Joshi N, Soni A, Sament R (2012) Functional outcome of

- ankle fracture patients treated with biodegradable implants. *Foot Ankle Surg* 18: 153-156.
10. Dumigan R, Bronson D, Early J (2006) Analysis of fixation methods for vertical shear fractures of the medial malleolus. *J Orthop Trauma* 20: 10.
 11. Tekin AC, Cabuk H, Dedeoglu SS, Saygili MS, Adas M, et al. (2016) Anterograde headless cannulated screw fixation in the treatment of medial malleolar fractures: Evaluation of a new technique and its outcomes. *Med Princ Pract* 25: 429-434.
 12. Herscovici D, Scaduto JM, Infante A (2007) Conservative treatment of isolated fractures of the medial malleolus. *J Bone Joint Surg Br* 89: 89-93.
 13. Mohammed AA, Abbas KA, Mawlood AS (2016) A comparative study in fixation methods of medial malleolus fractures between tension bands wiring and screw fixation. *Springerplus* 5: 530.
 14. Barnes H, Cannada LK, Watson JT (2014) A clinical evaluation of alternative fixation techniques for medial malleolus fractures. *Injury* 45: 1365-1367.
 15. Schenker ML, Mauck RL, Ahn J, Mehta S (2014) Pathogenesis and prevention of posttraumatic osteoarthritis after intra-articular fracture. *J Am Acad Orthop Surg* 22: 20-28.
 16. Sutter PM, Peltzer J (2010) Principles of operative treatment of malleolar fractures today. *Eur J Trauma Emerg Surg* 36: 505-514.
 17. Saini P, Aggrawal A, Meena S, Trikha V, Mittal S (2014) Miniarthrotomy assisted percutaneous screw fixation for displaced medial malleolus fractures - A novel technique. *J Clin Orthop Trauma* 5: 252-256.
 18. Lee SK, Park JS, Choy WS (2014) Locking compression plate distal ulna hook plate as alternative fixation for fifth metatarsal base fracture. *J Foot Ankle Surg* 53: 522-528.
 19. Tonogai I, Hamada Y, Kashima M, Takahashi M, Kanematsu Y, et al. (2011) Pins and rubber band traction system and osteosynthesis with a hook plate for the treatment of old fracture-dislocation of a toe: application of hand operative techniques in a foot operation. *Foot Ankle Spec* 4: 42-44.
 20. Khanna A, Gougoulas N, Maffulli N (2008) Intermittent pneumatic compression in fracture and soft-tissue injuries healing. *Br Med Bull* 88: 147-156.
 21. Ruedi TP, Murphy WM (2001) AO principles of fracture management.