

Laparoscopic Treatment of an Interstitial Pregnancy

Hamon NG^{1*}, Peng NG² and Sharon Li³

¹Senior House Officer, Gold Coast University Hospital, 1 Hospital Boulevard, Parkwood, QLD 4214, Australia

²Obstetrician and Gynaecologist, Sunnybank Private Hospital Medical Centre, Suite 5, 245, McCullough St, Sunnybank, QLD 4109, Australia

³Obstetrician and Gynaecologist, Sunnybank Private Medical Centre, Suite 3, 245, McCullough St, Sunnybank, QLD 4109, Australia

Abstract

In a 35 year old patient who was 8 weeks pregnant with a diagnosis of a stable, interstitial ectopic pregnancy, a decision was made to proceed with laparoscopic surgical management. A successful wedge resection of the ectopic pregnancy was completed with minimal blood loss using a Ligasure blunt tip laparoscopic sealer/divider forceps and O V-Loc suture. Other treatment modalities were discussed.

Introduction

Interstitial (cornual) pregnancy accounts for 2-4% of all tubal pregnancies [1] and is regarded as a medical emergency due to the risk of severe maternal haemorrhage if it ruptures [2]. Previous gold-standard of treatment involved a Laparotomy due to the increased vascularity of the area. However, laparoscopic surgery can now be considered an alternative option [2]. Other treatment options are explored in the discussion. The following case report demonstrates a successful laparoscopic technique of treating an interstitial ectopic pregnancy.

Case Report

A 35 year old G1P0 woman who was 8 weeks pregnant, had an endovaginal ultrasound scan, which showed a 2 cm gestation sac in her left adnexa. It was thought to be a tubal ectopic pregnancy. The patient herself was asymptomatic with no pain or bleeding.

A laparoscopy performed on the same day showed a very vascular interstitial pregnancy, which made up about 1/4 of the whole uterus. The cornual mass was excised with a Ligasure blunt tip laparoscopic sealer/divider forceps. The Ligasure forceps was used to coagulate and separate the lateral aspect of the cornual mass from the fallopian tube, suspensory ligament of the ovary and the adjacent broad ligament. The forceps then grasped and separated the inferior edge of the mass, cutting in from the lateral aspect of the uterus into the uterine cavity. The forceps hugged the mass and excised it from the uterine body, removing about 1/3 of the uterine fundus, finishing on the superior medial edge of the mass. The resulting defect was closed in two continuous layers with an 'O V-Loc 180' suture (Barbed, self-anchoring dissolvable suture). There was minimal blood loss of <50 mL. The operation on the actual ectopic pregnancy itself took about 20 minutes. Post-operation, only oral analgesics were required. The patient was discharged on the next day.

Her serum beta HCG level was 48,200 IU/L the day before surgery, 23,500 IU/L 12 hours after the operation, and 344 IU/L 9 days after surgery. This is a drop of more than 51% within a day after the operation. A threshold value of more than 50% drop makes a persistent ectopic pregnancy much less likely [3].

Discussion

Interstitial pregnancy is a rare form of ectopic pregnancy. Bouyer et al. [3] reported an incidence of 2.4% in 1,800 cases of ectopic pregnancies. Traditionally, the most common treatment of an interstitial pregnancy is through cornual wedge resection by Laparotomy. With the advancement of technology and surgical skills, various alternative treatment modalities have been reported. They are often made possible because of the advancement of ultrasound

scanning with the consequent early discovery of unruptured interstitial pregnancy.

Methotrexate in single or multiple doses, administered systemically or directly into the interstitial pregnancy, can be a useful option. The advantage is that surgery may be averted. The uterine integrity may be preserved. Direct injection of methotrexate into the lesion was shown to have a three time shorter average time to resolution of serum bHCG compared with systemic treatment [4]. However, it is not appropriate for ruptured ectopic pregnancy. Direct methotrexate injections can be hard to organise during accidental discoveries of interstitial pregnancies in laparoscopic cases thought to be normal tubal ectopic pregnancies. An overall failure rate of up to 35% has been reported [5-8]. There may be an increased risk of recurrent ectopic pregnancy especially on the

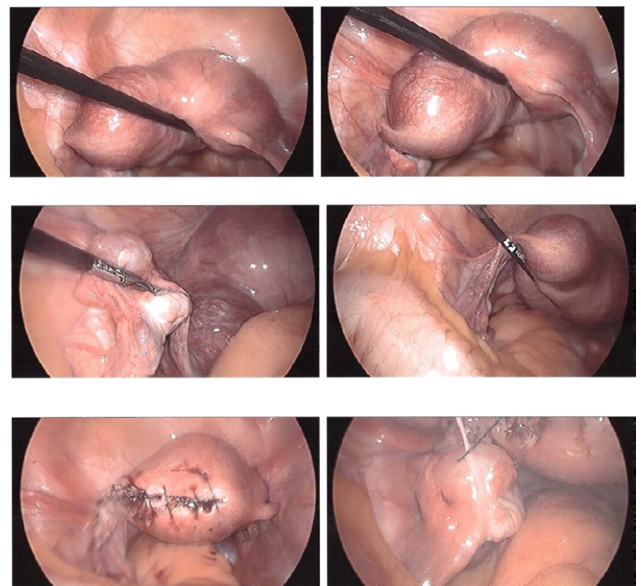


Figure 1: Ectopic pregnancy.

*Corresponding author: Hamon NG, Senior House Officer, Gold Coast University Hospital, 1 Hospital Boulevard, Parkwood, QLD 4214, Australia, Tel: 0430110256; E-mail: hamon.ng5@gmail.com

Received May 05, 2014; Accepted August 22, 2014; Published August 27, 2014

Citation: Hamon NG, Peng NG, Sharon Li (2014) Laparoscopic Treatment of an Interstitial Pregnancy. Gynecol Obstet (Sunnyvale) 4: 238 doi:10.4172/2161-0932.1000238

Copyright: © 2014 Hamon NG, et al. This is an open-access article distributed under the terms of the Creative Commons Attribution License, which permits unrestricted use, distribution, and reproduction in any medium, provided the original author and source are credited.

ipsilateral side. Failure rate for large interstitial pregnancies is likely to be higher. Methotrexate, being an antimetabolite and anti-folate chemotherapeutic agent, has the potential to cause collateral tissue or organ damage and may not be acceptable or appropriate to some patients. Other concerns are multiple doses may be required, treatment prolonged and there is a risk of uterine rupture with catastrophic haemorrhage.

Direct injection of potassium chloride may be a preferable option for the treatment of heterotopic interstitial pregnancies [9]. Patients particularly at risk of heterotopic pregnancies are IVF patients whereby 2 or more embryos are transferred.

Hysteroscopic or combined hysteroscopic and laparoscopic treatment of interstitial pregnancies have also been described [10-14]. The laparoscopy offers some safety against cornual rupture during hysteroscopic resection or suction curettage. This is not a commonly used treatment as there is paucity of data about its safety.

Laparoscopic surgical treatment can be either by cornuostomy or wedge resection. The latter offers more certainty in the complete elimination of trophoblastic tissue, and less risk of subsequent ectopic pregnancy on the same side. However, it is more challenging in the reconstruction of the uterus. Cornuostomy preserve more anatomical integrity but is more likely to have persistent retained trophoblastic tissue.

Methotrexate can be given post-operatively if there is inadequate reduction in HCG levels where retained trophoblastic tissue is suspected. It has been recommended that post-operative methotrexate should be reserved for the few patients in whom the HCG concentration does not decrease by 15% within 48 hours [15].

The main concern about laparoscopic surgery for interstitial pregnancy is the risk of rupture in future pregnancy. As it is a novel method of treatment, there is insufficient data to demonstrate its safety for future pregnancy. Cases of cornual ruptures have been reported [16]. Good surgical technique and keeping diathermy use to a minimum to reduce adjacent tissue damage will likely reduce this risk. A retrospective review of 52 cases of laparoscopic surgical treatment of interstitial pregnancy has provided some promising results [17]. The 52 cases were followed up for at least 18 months. Eighteen women managed to become pregnant and 10 had pregnancies beyond 24 weeks gestation. There was no report of any uterine rupture or dehiscence. For women who wish to have another pregnancy, sonohysterography has been recommended to look for myometrial thinning [18]. Careful monitoring of all subsequent pregnancies is essential and caesarean delivery is highly recommended.

The second main concern of the laparoscopic surgical treatment of interstitial pregnancy is the risk of major haemorrhage. In this case study, the wedge resection was performed using the ligasure laparoscopic sealer/divider forceps. This forceps offers average seal cycles of 2-4 seconds with effective haemostasis and minimal adjacent tissue damage of <5 mm. It significantly reduces blood loss and operation time [19-21].

The third main concern of the laparoscopic method of treating interstitial pregnancies involves the length of time of operation. Currently, most laparoscopic repairs of interstitial pregnancy were by interrupted figure of 8 stitches, involving multiple knot tying. This is time consuming and laparoscopic knot tying is a relatively difficult technique to master. In this case study, by using the O V-Loc suture, the barbed suture ensures tension is maintained in between each stitch, much like an open procedure. A continuous stitch therefore can be

performed, maintaining tension throughout the whole wound closure. Knot tying is not required at all as the stitch is self-holding. This ensures more secure tissue approximation, haemostasis and reduces operation time considerably [22].

In conclusion, with the appropriate patients, setting and in the presence of experienced laparoscopic surgeons, laparoscopic management for interstitial pregnancies may be considered a preferable option.

References

1. Damario MA, Rock JA (2003) „Ectopic Pregnancy”. In: Rock JA, Jones HWIII (Eds.) *Te Linde's Operative Gynecology* (9th ed.). Lippincott Williams and Wilkins, Philadelphia, pp. 507-536.
2. Faraj R, Steel M (2007) Management of cornual (interstitial) pregnancy. *The Obstetrician and Gynaecologist* 9: 249-255.
3. Bouyer J, Coste J, Fernandez H, Pouly JL, Job-Spira N (2002) Sites of ectopic pregnancy: a 10 year population-based study of 1800 cases. *Hum Reprod* 17: 3224-3230.
4. Lau S, Tulandi T (1999) Conservative medical and surgical management of interstitial ectopic pregnancy. *Fertil Steril* 72: 207-215.
5. Sagiv R, Golan A, Arbel-Alon S, Glezerman M (2001) Three conservative approaches to treatment of interstitial pregnancy. *J Am Assoc Gynecol Laparosc* 8: 154-158.
6. Tulandi T, Al-Jaroudi D (2004) Interstitial pregnancy: results generated from the Society of Reproductive Surgeons Registry. *Obstet Gynecol* 103: 47-50.
7. Barnhart K, Spandorfer S, Coutifaris C (1997) Medical treatment of interstitial pregnancy. A report of three unsuccessful cases. *J Reprod Med* 42: 521-524.
8. Gherman RB, Stitely M, Larrimore C, Nevin K, Coppola A, et al. (2000) Low-dose methotrexate treatment for interstitial pregnancy. A case report. *J Reprod Med* 45: 142-144.
9. Fritz M, Speroff L (2011) *Clinical Gynecology Endocrinology and Infertility*, (8th Edn.), Lippincott Williams and Wilkins, Philadelphia, USA.
10. Nezhat C, Dun E (2014) Laparoscopically-assisted, hysteroscopic removal of an interstitial pregnancy with a fertility-preserving technique. *The Journal of minimally invasive Gynaecology*.
11. Cai Z, Wang F, Cao H, Xia Q (2009) Transcervical suction of interstitial pregnancy under laparoscopic and hysteroscopic guidance. *J Minim Invasive Gynecol* 16: 761-764.
12. Katz DL, Barrett JP, Sanfilippo JS, Badway DM (2003) Combined hysteroscopy and laparoscopy in the treatment of interstitial pregnancy. *Am J Obstet Gynecol* 188: 1113-1114.
13. Minelli L, Landi S, Trivella G, Fiaccavento A, Barbieri F (2003) Cornual pregnancy successfully treated by suction curettage and operative hysteroscopy. *BJOG* 110: 1132-1134.
14. Ross R, Lindheim SR, Olive DL, Pritts EA (2006) Cornual gestation: a systematic literature review and two case reports of a novel treatment regimen. *J Minim Invasive Gynecol* 13: 74-78.
15. Siow A, Ng S (2011) Laparoscopic management of 4 cases of recurrent cornual ectopic pregnancy and review of literature. *J Minim Invasive Gynecol* 18: 296-302.
16. Weissman A, Fishman A (1992) Uterine rupture following conservative surgery for interstitial pregnancy. *Eur J Obstet Gynecol Reprod Biol* 44: 237-239.
17. Ng S, Hamontri S, Chua I, Chern B, Siow A (2009) Laparoscopic management of 53 cases of cornual ectopic pregnancy. *Fertil Steril* 92: 448-452.
18. Maruthini D, Sharma V (2013) A Case of Live Birth after Uterine Reconstruction for Recurrent Cornual Ectopic Pregnancy following IVF Treatment. *Case Rep Obstet Gynecol* 2013: 625261.
19. Targarona EM, Balague C, Marin J, Neto RB, Martinez C, et al. (2005) Energy sources for laparoscopic colectomy: A prospective randomized comparison of conventional electrosurgery, bipolar computer-controlled electrosurgery and ultrasonic dissection. *Operative Outcome and cost analysis. Surg innov* 12: 339-344.

-
20. Campagnacci R, de Sanctis A, Baldarelli M, Rimini M, Lezoche G, et al. (2007) Electrothermal bipolar vessel sealing device vs. ultrasonic coagulating shears in laparoscopic colectomies: a comparative study. *Surg Endosc* 21: 1526-1531.
21. Takada M1, Ichihara T, Kuroda Y (2005) Comparative study of electrothermal bipolar vessel sealer and ultrasonic coagulating shears in laparoscopic colectomy. *Surg Endosc* 19: 226-228.
22. Time motion study-comparison of wound closure time using conventional techniques and knotless, self-anchoring surgical sutures in ex-vivo porcine model for both single layer and double layer closure in all closure techniques. Royal College of Surgeons, London, UK; Coviden V-Loc 180 Absorbable Wound Closure Device Time Study, Robert T. Grant, New York Presbyterian Hospital, Argent Global Services.